

A RARE CASE OF LOCALIZED PULMONARY NOCARDIOSIS CAUSED BY *NOCARDIA FARCINICA* IN A PATIENT WITH A BRAIN TUMOR

BEYİN TÜMÖRÜ OLAN HASTADA *NOCARDIA FARCINICA*'NİN NEDEN OLDUĞU NADİR BİR LOKALİZE PULMONER NOKARDİYOZ OLGUSU

Sevinc VURAL¹ , Tayfur DEMİRAY¹ , Salih BİLEN² , Özlem AYDEMİR¹ , Mehmet KÖROĞLU¹ 

¹Sakarya University, Faculty of Medicine, Department of Medical Microbiology, Sakarya, Türkiye

²Sakarya University, Education and Research Hospital, Department of Thoracic Surgery, Sakarya, Türkiye

ORCID IDs of the authors: S.V. 0000-0001-6999-1250; T.D. 0000-0003-1161-4684; S.B. 0000-0001-9387-7968; Ö.A. 0000-0003-4533-6934; M.K. 0000-0001-8101-1104

Cite this article as: Vural S, Demiray T, Bilen S, Aydemir Ö, Köroğlu M. A rare case of localized pulmonary nocardiosis caused by *nocardia farcinica* in a patient with brain tumor. J Ist Faculty Med 2024;87(2):176-179. doi: 10.26650/IUITFD.1386668

ABSTRACT

Nocardia farcinica is rarely isolated from clinical specimens, and it is a more virulent strain than other types of *Nocardia*. In this report, we evaluated a rare case of pleural empyema and pneumonia caused by *Nocardia farcinica* in a patient who had risk factors such as long-term use of corticosteroids, chronic respiratory disease, and a brain tumor. The distinction of *N. farcinica* from other *Nocardia* species is important because *N. farcinica* is more virulent and highly resistant, especially to broad-spectrum cephalosporins, which can make treatment difficult. In conclusion, in the presence of nonspecific physical examination and radiographic findings in patients using immunosuppressives and having comorbid diseases, atypical causative agents such as *Nocardia infection* should be considered in the differential diagnosis.

Keywords: Nocardiosis, *Nocardia farcinica*, pleural effusion, antibiotic susceptibility test, immunocompromised patients

ÖZET

Nocardia farcinica klinik örneklerden nadiren izole edilir ve diğer *Nocardia* türlerine göre daha virülan bir türdür. Bu makalede uzun süreli kortikosteroid kullanımı, kronik solunum yolu hastalığı ve beyin tümörü gibi risk faktörlerine sahip bir hastada *Nocardia farcinica*'nın neden olduğu nadir bir plevral empiyem ve pnömoni olgusu değerlendirildi. *N. farcinica*'nın diğer *Nocardia* türlerinden ayrılması önemlidir, çünkü *N. farcinica* daha virülandır ve özellikle geniş spektrumlu sefalosporinlere yüksek derecede dirençlidir ve bu da tedaviyi zorlaştırabilir. Sonuç olarak, immünsüpresif ilaç kullanan ve eşlik eden hastalıkları olan hastalarda nonspesifik fizik muayene ve radyografik bulguların varlığında ayırıcı tanıda *Nocardia* enfeksiyonu gibi atipik etkenlerin akılda tutulması gerekmektedir.

Anahtar Kelimeler: Nokardiyoz, *Nocardia farcinica*, plevral efüzyon, antibiyotik duyarlılık testi, bağışıklığı zayıflamış hastalar

Corresponding author/İletişim kurulacak yazar: Sevinç VURAL – vuralsevinc1@gmail.com

Submitted/Başvuru: 09.11.2023 • **Revision Requested/Revizyon Talebi:** 22.12.2023 •

Last Revision Received/Son Revizyon: 03.01.2024 • **Accepted/Kabul:** 03.01.2024 • **Published Online/Online Yayın:** 09.02.2024



Content of this journal is licensed under a Creative Commons Attribution-NonCommercial 4.0 International License.

INTRODUCTION

The *Nocardia* species is a Gram-positive, partially acid-fast, aerobic, filamentous genus of *Actinomycetes* commonly found in decaying matter, soil, and water (1). *Nocardia* is usually transmitted by inhalation (2). Pulmonary nocardiosis is the most common clinical presentation; the most common symptoms are shortness of breath and coughing (2, 3). Although *Nocardia farcinica* is rarely isolated, it is more virulent than other *Nocardia* species (4). It mainly causes infections in immunocompromised patients who have risk factors such as long-term corticosteroid therapy, use of immunosuppressive drugs, organ transplantation, malignancy, human immunodeficiency virus (HIV) infection, diabetes, chronic obstructive pulmonary disease (COPD), or alcoholism (2, 5, 6). Although it is rarely isolated from local and systemic infections in healthy individuals, it can also cause opportunistic infections in immunocompromised patients (7). Pleural involvement in *N. farcinica* infections is rare; few studies have been reported in the literature (4, 8).

In this case report, pleural empyema and pulmonary nocardiosis caused by *N. farcinica*, which developed in a patient with long-term corticosteroid use, COPD, and malignancy, are evaluated.

CASE PRESENTATION

A 70-year-old male patient was admitted to the emergency department with complaints of shortness of breath. The patient was diagnosed with hypertension, COPD, ischemic heart disease, and diabetes mellitus and was waiting for surgery, with the preliminary diagnosis of a brain tumor. The patient's vital signs were TA: 147/88 mmHg, pulse: 110/min, and O₂ saturation: 86-88 (while oxygen was administered). During physical examination, costal movements were restricted on the right side, and respiratory findings decreased with auscultation. Right total pneumothorax was detected on posteroanterior chest radiography and thorax computed tomography (Figure 1). A thoracostomy tube was placed at the right 4th intercostal level. The patient was transferred to the intensive care unit. C-reactive protein: 190 mg/L, sedimentation: 119 mm/hour, and glucose: 516 mg/dL were revealed in laboratory tests. Other biochemical parameters and hemogram results were within normal limits. The patient was discharged with full recovery on the 10th day after admission.

One month later, the patient was admitted again to the emergency department with findings such as shortness of breath, subcutaneous emphysema, and discharge from the drain site and was transferred to the thoracic surgery clinic. Radiological examinations revealed a minimal expansion defect of the right lung, atelectasis at the base of the right hemithorax, and secondary minimal pleural effu-

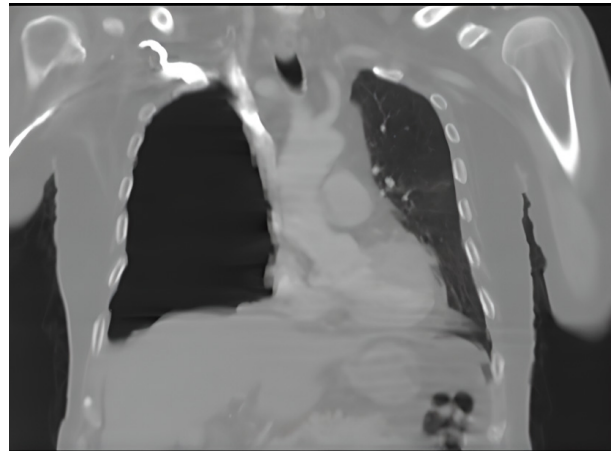


Figure 1: Admission thoracic tomography (June 15, 2022)

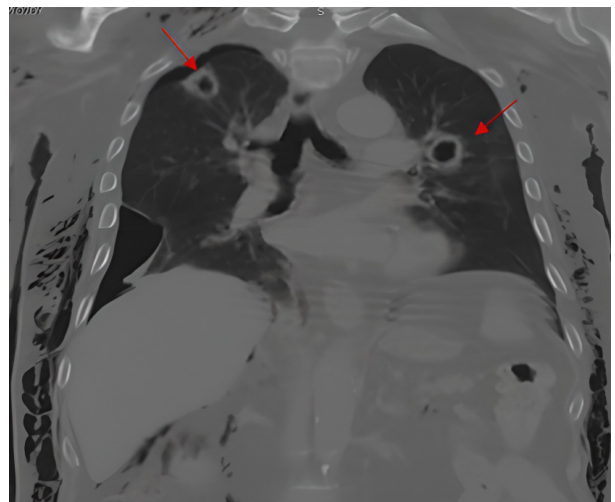


Figure 2: Bilateral cavitory lesions on coronal computed tomography (July 14, 2022)

sion and bilateral cavitory lesions (Figure 2). Considering the patient's newly developing cavitory lesions and possible brain tumor metastases, positron emission tomography/computed tomography (PET/CT) was planned. Thoracentesis was performed from the right hemithorax. Pleural fluid was purulent and sent to the bacteriology laboratory for further analysis. The pleural fluid sample was inoculated on 5% sheep blood agar, eosin-methylene blue agar, and chocolate agar. Direct Gram staining was performed from the sample. Gram-positive bacilli with branching structures and polymorph nuclear inflammatory cells were detected. After two days of incubation, non-hemolytic, small, irregular colonies appeared on sheep blood agar. Microscopic examination of the grown colonies revealed Gram-positive bacilli with branching structures (Figure 3). The bacteria were identified as *N. farcinica* by Mass Spectrometry (VITEK MS, bioMérieux, Marcy l'Etoile, France). Antimicrobial susceptibility tests (AST) were evaluated according to the Clinical and Lab-

oratory Standards Institute (CLSI) (9). The isolate was susceptible to increased doses of imipenem, amikacin, ciprofloxacin, and gentamicin. It was resistant to amoxicillin plus clavulanic acid.

Progression in the number and size of bilateral cavitory lesions were determined on PET/CT. The lesions were compatible with infective processes (Figure 4). The patient received ampicillin/sulbactam treatment for five days, and his treatment was revised after the causative agent was reported as *N. farcinica*. Trimethoprim-sulfamethoxazole (4x3 400/80 mg I.V.) and linezolid (2x600 mg I.V.) treatment was administered. During the patient's follow-up and treatment continued in the ward, the patient's health deteriorated. The patient, who developed sepsis in the intensive care unit, died on the 5th day of his admission to the intensive care unit.

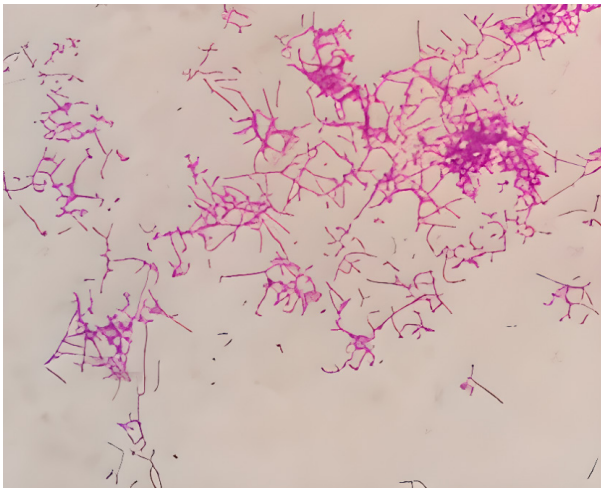


Figure 3: Gram-positive branching bacillus on microbiological staining of the pleural fluid specimen

DISCUSSION

Nocardia species can cause opportunistic infections in patients with predisposing factors such as malignancy, chemotherapeutic agents and/or steroid use, and COPD (2, 4). According to the study conducted by Torres et al., almost all of the 53 patients with *N. farcinica* infection had predisposing factors (5). *N. farcinica* can cause serious infections such as pneumonia and sepsis (2). Pulmonary and pleural infections, brain abscesses, and skin infections are the main clinical manifestations of *N. farcinica* infections (5). Although the onset of symptoms is subacute or chronic, it is difficult to recognize clinically because it occurs with nonspecific symptoms such as coughing, fever, shortness of breath, weight loss, fatigue, chest pain, hemoptysis, and night sweats (10). *N. farcinica* should be considered in pneumonia in the presence of radiological nodules, airspace consolidations, pleural effusion, and cavitory lesions (Figure 2, Figure 4) (11). As in this case, cavitory lesions are generally seen in immunocompromised patients and progress rapidly (2). In a review of 18 cases of pleural infection caused by *N. farcinica*, mortality was found to be more than 30% (4).

The diagnosis of nocardiosis is achieved by isolating the bacteria from clinical samples such as sputum, bronchoalveolar lavage fluid, pleural fluid, and abscess aspiration within 2-7 days (6). 16S rRNA sequence analysis is the gold standard for the identification of *Nocardia* species (12). However, the mass spectrometry method has promising results and is used successfully in rapid diagnosis (13).

The European Committee on Antimicrobial Susceptibility Testing (EUCAST) is still working to determine AST

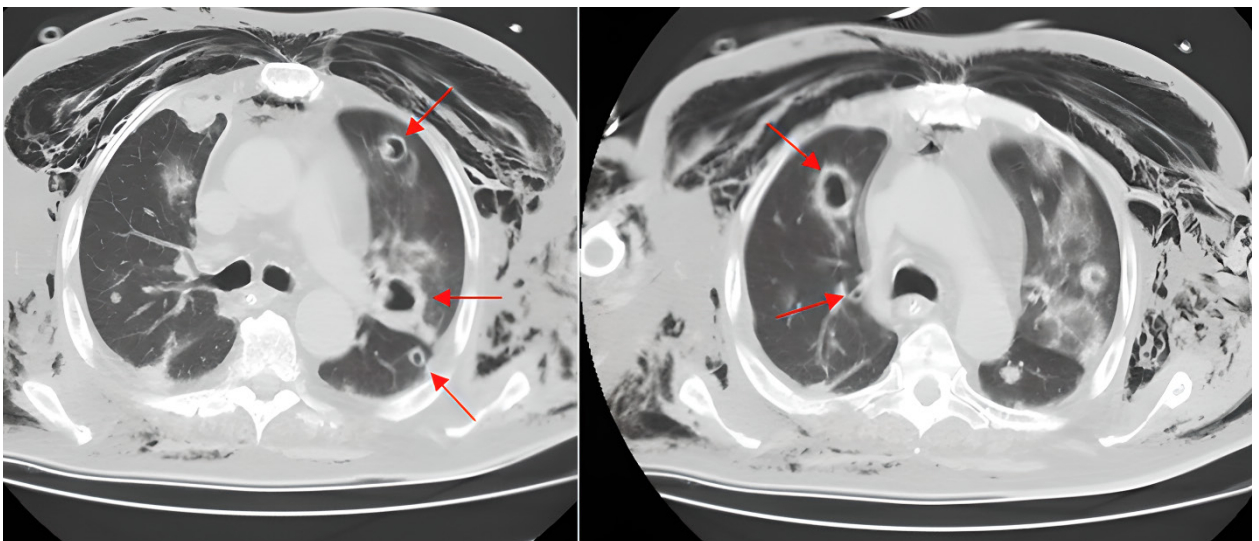


Figure 4: Rapidly progressing cavitory lesions (July 28, 2022)

breakpoints for *Nocardia* species (12). For this reason, the CLSI guideline is still used for AST (12). According to CLSI guidelines, broth microdilution is recommended for AST of *Nocardia* (12). Gradient strip tests and disk diffusion methods can also be used (8, 14). The results obtained in all AST methods should be interpreted carefully (15).

Trimethoprim-sulfamethoxazole has been the basis of nocardiosis treatment for the last 70 years (12). However, very high resistance rates have been reported for *N. farcinica* in some studies (8). All *Nocardia* species are generally susceptible to linezolid, amikacin, and trimethoprim-sulfamethoxazole in vitro (12). However, the susceptible profiles of other antibiotics vary greatly among *Nocardia* species (12).

In pneumonia caused by *Nocardia*, the combination of trimethoprim-sulfamethoxazole and carbapenem is recommended as initial treatment (4). In more severe cases, aminoglycoside can be added to this combination, and oral monotherapy can be switched after clinical improvement following 3 to 4 weeks of parenteral treatment (4). The treatment period may last 6-12 months (10). In addition to antibiotic treatment, interventional methods such as tube thoracostomy or therapeutic thoracentesis can be considered (4).

CONCLUSION

In conclusion, *Nocardia* infection should be considered in differential diagnosis in immunocompromised patients. Rapid identification of the microorganism can be life-saving, as identification at the species level is important in initiating the appropriate antimicrobial therapy. Considering the increasing resistance rates, antimicrobial susceptibility testing is of vital importance.

Informed Consent: Written informed consent was obtained from the patient and their legal guardians.

Peer Review: Externally peer-reviewed.

Author Contributions: Conception/Design of Study- S.V., T.D.; Data Acquisition- S.V., S.B.; Data Analysis/Interpretation- S.V., T.D.; Drafting Manuscript- S.V., T.D., S.B.; Critical Revision of Manuscript- S.V., T.D., S.B., Ö.A., M.K.; Final Approval and Accountability- S.V., T.D., S.B., Ö.A., M.K.

Conflict of Interest: The authors have no conflict of interest to declare.

Financial Disclosure: The authors declared that this study received no financial support.

REFERENCES

1. Kandi V. Human Nocardia Infections: A review of pulmonary nocardiosis. *Cureus* 2015;7(8):e304. [[CrossRef](#)]
2. Steinbrink J, Leavens J, Kauffman CA, Miceli MH. Manifestations and outcomes of Nocardia infections comparison of immunocompromised and non-immunocompromised adult patients. *Medicine (United States)* 2018;97(40):e12436. [[CrossRef](#)]
3. Ambrosioni J, Lew D, Garbino J. Nocardiosis: updated clinical review and experience at a tertiary center. *Infection* 2010;38(2):89-97. [[CrossRef](#)]
4. Bagüeste G, Porcel JM, Bagüeste G, Porcel JM. Pleural infection caused by *Nocardia farcinica*: two cases and review of the literature. *Cureus* 2021;13(4):e14697. [[CrossRef](#)]
5. Torres OH, Domingo P, Pericas R, Boiron P, Montiel JA, Vázquez G. Infection caused by *Nocardia farcinica*: case report and review. *Eur J Clin Microbiol Infect Dis* 2000;19(3):205-12. [[CrossRef](#)]
6. Brown-Elliott BA, Brown JM, Conville PS, Wallace RJ. Clinical and laboratory features of the *Nocardia* spp. based on current molecular taxonomy. *Clin Microbiol Rev* 2006;19(2):259-82. [[CrossRef](#)]
7. Budzik JM, Hosseini M, Mackinnon AC, Taxy JB. Disseminated *Nocardia farcinica*: Literature review and fatal outcome in an immunocompetent patient. *Surg Infect (Larchmt)* 2012;13(3):163-70. [[CrossRef](#)]
8. Valdezate S, Garrido N, Carrasco G, Medina-Pascual MJ, Villalón P, Navarro AM, et al. Epidemiology and susceptibility to antimicrobial agents of the main *Nocardia* species in Spain. *J Antimicrob Chemother* 2017;72(3):754-61. [[CrossRef](#)]
9. Clinical and Laboratory Standards Institute (CLSI). Performance standards for susceptibility testing of mycobacteria, nocardia spp., and other aerobic actinomycetes. 2nd edition. CLSI supplement M24S, 2023.
10. Wilson JW. Nocardiosis: Updates and clinical overview. *Mayo Clin Proc* 2012;87(4):403-7. [[CrossRef](#)]
11. Blackmon KN, Ravenel JG, Gomez JM, Ciolino J, Wray DW. Pulmonary nocardiosis: Computed tomography features at diagnosis. *J Thorac Imaging* 2011;26(3):224-9. [[CrossRef](#)]
12. Margalit I, Lebeaux D, Tishler O, Goldberg E, Bishara J, Yahav D, et al. How do I manage nocardiosis? *Clin Microbiol Infect* 2021;27(4):550-8. [[CrossRef](#)]
13. Girard V, Mailler S, Welker M, Arzac M, Cellière B, Cotte-Pattat PJ, et al. Identification of *Mycobacterium* spp. and *Nocardia* spp. from solid and liquid cultures by matrix-assisted laser desorption ionization–time of flight mass spectrometry (MALDI-TOF MS). *Diagn Microbiol Infect Dis* 2016;86(3):277-83. [[CrossRef](#)]
14. Lebeaux D, Bergeron E, Berthet J, Djadi-Prat J, Mouniée D, Boiron P, et al. Antibiotic susceptibility testing and species identification of *Nocardia* isolates: a retrospective analysis of data from a French expert laboratory, 2010–2015. *Clin Microbiol Infect* 2019;25(4):489-95. [[CrossRef](#)]
15. Wang H, Zhu Y, Cui Q, Wu W, Li G, Chen D, et al. Epidemiology and antimicrobial resistance profiles of the *Nocardia* species in China, 2009 to 2021. *Microbiol Spectr* 2022; 10(2):e0156021. [[CrossRef](#)]