

Pediatric deep neck infections: efficacy of conservative treatment versus immediate surgical intervention

Emel Tahir¹, Nilda Süslü², R. Önder Günaydın², Oğuz Kuşçu², Onur Ergün², Umut Akyol²

¹Department of Otorhinolaryngology, Ankara Dışkapı Yıldırım Beyazıt Training and Research Hospital, Ankara, Turkey

²Department of Otorhinolaryngology, Faculty of Medicine, Hacettepe University, Ankara, Turkey

Abstract

Objective: The objective of this study was to review the management of deep neck space infections in pediatric patients and to evaluate the efficacy of intravenous antibiotic treatment alone before surgical drainage, and also to point out the indications for the drainage.

Methods: We reviewed sixty pediatric cases who were treated in our clinic because of deep neck space infections. The details of demographic data, medical history, initial complaints and physical examination, radiological examination, microbiology and laboratory results (C-reactive protein level and leukocyte count), treatment modality and follow-up findings were collected. The bacteriological results, management, complications, follow-up data and outcomes were also noted. A basic treatment algorithm for the management of the pediatric deep neck space infections was constituted.

Results: In 47 (78.3%) of the children, infection did not require any surgical intervention or puncture – in other words, needle aspiration – and it was successfully treated with antibiotic therapy alone. Fifty-six patients (93%) were initially treated with sulbactam-ampicillin.

Conclusion: We advise surgical drainage in cases of fluctuating large abscesses and infections without clinical improvement despite antibiotic treatment, and in complicated or life-threatening cases such as retropharyngeal abscess and mediastinitis. An otolaryngologist should be patient before any surgical intervention.

Keywords: Deep neck infection, children, antibiotic treatment, surgery.

Özet: Pediyatrik derin boyun enfeksiyonları: Acil cerrahi girişime karşılık konservatif tedavinin etkinliği

Amaç: Bu çalışmanın amacı pediyatrik hastalarda derin boyun enfeksiyonlarının yönetimini gözden geçirmek, cerrahi drenajdan önce yalnızca intravenöz antibiyotik tedavisinin etkinliğini değerlendirmek ve drenaj endikasyonlarına dikkati çekmekti.

Yöntem: Kliniğimizde derin boyun enfeksiyonu nedeniyle tedavi edilmiş 60 pediyatrik olguyu gözden geçirdik. Demografik veriler, tıbbi öykü, başlangıç yakınmaları ve fizik muayene, radyolojik inceleme, mikrobiyoloji ve laboratuvar sonuçları (C-reaktif protein düzeyi ve lökosit sayısı), tedavi yöntemi ve izlem bulgularının ayrıntıları toplandı. Bakteriyojik sonuçlar, tedavi komplikasyonları, takip verileri ve sonuçlar da kaydedildi. Pediyatrik derin boyun enfeksiyonları için bir temel tedavi algoritması oluşturuldu.

Bulgular: Çocukların 47'sinde (%78.3) enfeksiyon cerrahi girişim veya ponsiyon, başka bir deyişle iğne aspirasyonu gerektirmemiş yalnızca antibiyotiklerle başarılı bir şekilde tedavi edilmişlerdi. Elli altı hasta (%93) başlangıçta sulbaktam-ampisilinle tedavi edilmişti.

Sonuç: Fluktuasyon veren büyük apselerde ve antibiyotik tedavisine rağmen klinik iyileşme olmayanlarda, retrofarengeal apse ve mediastinit benzeri komplike ve yaşamı tehdit edici olgularda cerrahi drenaj önermekteyiz. Bir KBB uzmanı herhangi bir cerrahi girişimden önce sabırlı olmalıdır.

Anahtar sözcükler: Derin boyun enfeksiyonu, çocuklar, antibiyotik tedavisi, cerrahi.

Deep neck space infection in the pediatric age group is a common and morbidity-causing disease. These infections may involve the parapharyngeal, submandibular, and retropharyngeal spaces. Symptoms may differ from mild fever to life-threatening airway obstructions. Occasionally,

patients present with fever, neck mass, sore throat, and limited neck movements.^[1,2]

The most common pathogens are *S. aureus*, including the methicillin-resistant *Staphylococcus aureus* (MRSA) subtype, Group A beta-hemolytic Streptococcus, and anaer-

Correspondence: Emel Tahir, MD. Department of Otorhinolaryngology, Ankara Dışkapı Yıldırım Beyazıt Training and Research Hospital, Ankara, Turkey.
e-mail: emeltahir@hotmail.com

Received: July 2, 2017; **Accepted:** July 29, 2017

Presentation: This study was presented as poster in ESPO (European Society of Pediatric Otolaryngology) Congress, May 2014, Dublin, Ireland.

©2017 Continuous Education and Scientific Research Association (CESRA)

Online available at:
www.entupdates.org
doi:10.2399/jmu.2017002006
QR code:



deomed®

obes, often as a polymicrobial flora.^[3] For diagnosis, cultures and antibiograms must be taken to identify the microorganism and the appropriate antibiotic therapy. Ultrasonography (USG) is a useful diagnostic technique in case of a liquefactive abscess. In deeply situated infections and complicated patients, computerized tomography (CT) is advised.^[4]

Treatment options are intravenous (IV) antibiotics alone, or with surgical drainage if necessary. Despite the numerous studies, there is a lack of consensus about the treatment algorithm.^[4,5] Early surgical drainage versus conservative medical treatment as the primary treatment modality is a subject of ongoing debate.

Our objective was to review the management of deep neck abscesses in pediatric patients and to evaluate the efficacy of IV antibiotic treatment before considering surgical drainage, and also to point out the indications for the drainage.

Materials and Methods

Institutional ethics committee approval was obtained with a number of GO 14/278. All the procedures followed were in accordance with the ethical standards of Helsinki Declaration of 1964, as revised in 2000.

A retrospective chart review of children diagnosed with deep neck infection in Otolaryngology Department of Faculty of Medicine at Hacettepe University between January 2010 and December 2014 was performed. Patients from 0–16 years of age were included in the study. The diagnosis of deep neck infection was based on clinical features, radiological investigation (ultrasonography or computerized tomography), surgical and microbiological findings. Children who had neck swelling due to malignant diseases, tuberculosis, chronic granulomatous infections or immune deficiency were excluded. The details of demographic data, medical history, initial complaints and physical examination, radiological examination, microbiology and laboratory results (C-reactive protein level and leukocyte count), treatment modality and follow-up findings were collected. The bacteriological results, management, complications, follow-up data, and outcomes were also noted.

The microbiological investigation was done via aerobic and anaerobic pus culture which was taken from the fluctuating abscesses. Specimens are placed onto blood agar in the microbiology laboratory. Culture and puncture were not performed if the patient has no fluctuating lesion.

Results

A total of 60 cases that met the criteria were identified. The mean age of the patients was 5 years, ranging from 10 days to 16 years.

Initial complaints were reviewed. Among 60 patients, 55 (91.6%) were admitted with neck swelling. Other initial symptoms were presented as restricted neck movements in two children and dysphagia in three children. Fifty-three children (88.3%) had a fever (above 37.5°C) initially. Additional signs and symptoms were sore throat (12 patients), dental abscess (2 patients) and tachypnea (1 patient). The most common symptoms upon admission are shown in Table 1.

Laboratory results were reviewed. All children were tested for C-reactive protein (CRP) and complete blood count. Twenty-two of them (36.6%) had elevated CRP levels. Leukocyte counts were ranged from 2300 to 23,900 microliter. Fifty-seven patients (95%) had elevated leukocyte counts (above 10,000 microliter).

All patients underwent radiological investigations. Ultrasonography was preferred in 54 non-complicated children who had no evidence of prominent complicated and fluctuating neck mass. USG was the most commonly preferred radiologic study for 90%, because there was no evidence of complication. In five children, CT scan was required as the initial radiological assessment. These patients were thought to have complicated deep neck space infections such as retropharyngeal or parapharyngeal space involvements. Magnetic resonance imaging (MRI) was used in only one child who had mediastinitis. Ultrasonographic measurement of the abscess, if any, was performed and the patients who had an abscess ≥ 3 cm in diameter were evaluated and followed up for possible puncture or drainage.

In 47 (78.3%) of the children, infection did not require any surgical intervention or puncture and it was success-

Table 1. Most common symptoms upon admission day.

Symptom	Number of cases (%)
Neck mass	55 (91.6)
Fever	53 (88.3)
Sore throat	12 (20)
Dental abscess	2 (3.3)
Tachypnea	1 (1.6)
Limited neck motion	2 (3.3)
Dysphagia	3 (5.0)

fully treated with antibiotic therapy alone. Thirteen of the patients (21.7%) required puncture or drainage. In 8 of those 13 children, puncture was performed and the pus was aspirated. Nine of the cases required minimal incision and drainage upon admission because of large fluctuating abscess. One patient was complicated with mediastinitis and had a huge fluctuating abscess on the neck. She was treated with immediate surgical drainage and intravenous antibiotics for three weeks and healed without any problem. After discharge from the hospital, oral antibiotics (amoxicillin clavulanate) were prescribed to all of the patients for 10 days and they were recalled for a control examination. Surgical complications such as neurovascular injury or extensive scar formation were not observed in the study group. Mean duration of hospital stay was 8 days, ranging from 1 to 21 days. Mean hospitalization period in the surgically drained group was 12 days, slightly longer than the non-drained group, with 10 days.

Cultures from the abscess were taken in 13 patients who required puncture or drainage. The most common microorganism isolated in the cultures was *S. aureus* in 9 patients. Other microorganisms were *S. epidermidis* in 2 patients, *Streptococcus agalactia* and *Bacteroides fragilis* each in 1 patient. Microorganisms isolated by drainage are shown in Table 2. None of the patients were immunocompromised.

The most commonly used antibiotic regime was a 40 mg/kg/day sulbactam+ampicillin (SAM) combination divided into 4 doses. Fifty-six patients (93%) were initially treated with SAM. Vancomycin in 3 patients and ceftriaxone in 1 patient were the antibiotherapies of choice because of the complicated clinical course. The mean duration of antibiotherapy was 8.07 days. For 4 patients, ornidazole was added to SAM because of their underlying odontogenic infections and the increased possibility of polymicrobial flora with anaerobic microorganisms. Clindamycin was added in 3 cases who had anaerobic microorganisms, proven by culture. The patient treated with ceftriaxone had previously received unsuccessful amoxicillin + clavulanic acid treatments and the patients treated with vancomycin had histo-

ry of hospitalization at a hospital known for MRSA colonization. This is mostly because patients referred to our clinic had been already received antibiotics before bacterial culture. Antibiotics were adjusted according to culture results and susceptibility results. Antibiotic regimens were ordered according to the consultation of pediatric infectious diseases department.

Discussion

Deep neck space infections (DNSIs) are infections in the potential spaces and fascial planes of the neck, which could be related to lymphadenitis, cellulitis, necrotic node or abscess. DNSIs are common diseases in childhood. Infections of the ears, nose, throat, and teeth can produce DNSI by lymphatic drainage or direct spread.^[5]

The disease often presents with upper respiratory tract symptoms, fever, neck pain, swelling of the cervical lymph nodes, neck mass, dysphagia, odynophagia, torticollis, trismus and limitations of neck movements. Neurologic symptoms may arise if cranial nerves or sympathetic chain are involved.^[6] Among our 40 patients, 87.5% presented with neck mass and fever as the most frequently encountered symptoms on admission day. Complications of deep space neck infections include airway obstruction, jugular vein thrombosis, mediastinitis, and carotid rupture.^[7] Life-threatening complications such as airway obstruction and dissemination of infection to potentially dangerous spaces like the mediastinum can develop in hours. A rapidly progressive course with fatal outcome may be seen, especially in infants and immunocompromised patients.^[8] Children with congenital immune deficiencies or oncologic patients under chemotherapy may develop complications very rapidly and dramatically. One of our patients presented with a mediastinal involvement of a huge fluctuating neck abscess that needed immediate surgical drainage and IV antibiotics in order to save her life.

A wide spectrum of pathogens is involved in deep neck infections. The most common pathogens are *S. aureus*, including MRSA, beta hemolytic streptococcus, Group A *Streptococcus* and anaerobes. The increasing isolation of community-acquired MRSA in pediatric head and neck abscesses has been a major focus of the current literature.^[9] In our study, the most commonly isolated pathogen in the pus culture was *S. aureus* in 9 patients (69.2%). Because of different causative microorganisms often found as polymicrobial floras, broad spectrum parenteral antibiotics are advocated for DNSIs.

In the present study, it should also be noted that a majority of the cases (78.3%) received empirical antibiotic

Table 2. Most commonly isolated microorganisms.

Microorganism	Number of patients (%)
<i>Staphylococcus aureus</i>	9 (69.2)
<i>Staphylococcus epidermidis</i>	2 (15.4)
<i>Streptococcus agalactia</i>	1 (7.7)
<i>Bacteroides fragilis</i>	1 (7.7)

treatments because it is not possible to take cultures unless there is a fluctuant collection to be punctured, and early recognition and treatment prevent DNSIs from forming abscesses. For the rest of the cases, antibiotic treatments had been started empirically before the culture results became available, and were tailored if necessary.

Rozovsky et al. stated that ultrasonography is sufficient to provide information about the nature, size and extent of inflammatory neck masses.^[10] Meyer et al. suggest CT upon presentation in all patients with deep neck abscesses.^[11]

In our study, 54 patients (90%) were evaluated by ultrasonography. In 6 patients, cross-sectional studies like CT or MRI were required. Although CT is accurate in differential diagnosis of cellulitis, phlegmon or abscess, radiation exposure and possible sedation or anesthesia requirements must be considered. Ultrasonography is useful as an initial imaging modality, especially for the identification of abscesses. It evaluates whether the abscess is liquefied enough to be drained and may also be used in ultrasonography-assisted drainage procedures. However, in deeply situated infections which may not be visible by ultrasonography, CT or MRI may be required.

Abscesses within the lymph nodes are formed by liquefactive necrosis, a process that may require a long time if the infection is left untreated. Some clinicians advocate initial antibiotic therapy, especially for patients with early admissions to hospital.^[12,13] They suggest surgical intervention in case of a failure of improvement. They state that an initial trial of IV antibiotics may reduce the need for surgical intervention, which has potential complications. The urgency of the surgical drainage for children is not clearly stated in the current literature. The study of Cramer et al. found that delay in surgical drainage was significantly associated with greater morbidity and mortality in adults, whereas in children they found no difference between the early and late drainage groups.^[13] Bolton et al. examined 130 patients in their clinic and point out the requirement of surgical drainage if the diameter of the abscess is more than 2 cm. They also showed the efficacy of antimicrobial therapy alone.^[14] Our institutional experience and clinical practice is also similar. Puncture/drainage was performed to the patients who had ≥ 3 cm fluctuating abscess and majority of the cases were treated solely antibiotics.

Some researchers also claim that medical treatment alone is not enough to entirely cure deep neck abscesses and consider surgical drainage as the gold standard.^[15,16] On the other hand, the morbidity of surgery (such as the need for anesthesia, scar formation and complications)

should be taken into account. Advantages of initial medical treatment include avoidance of iatrogenic injury to great vessels or cranial nerves. Treatment algorithm for pediatric DNSI is summarized in Fig. 1.

Main limitations of this study are its retrospective design, small sample size, and lack of pus staining prior to antibiotherapy. Thus, a properly-designed prospective study should be performed to identify the results of successful non-operative management.

Otolaryngologists must be aware of such infections, microbiology of this disease and should not underestimate the potential risks of any surgical intervention especially in pediatric population. This study confirms that the medical treatment with appropriate doses of intravenous antibiotics could be a tolerable and safe option for the treatment of patients with uncomplicated small deep neck space infections.

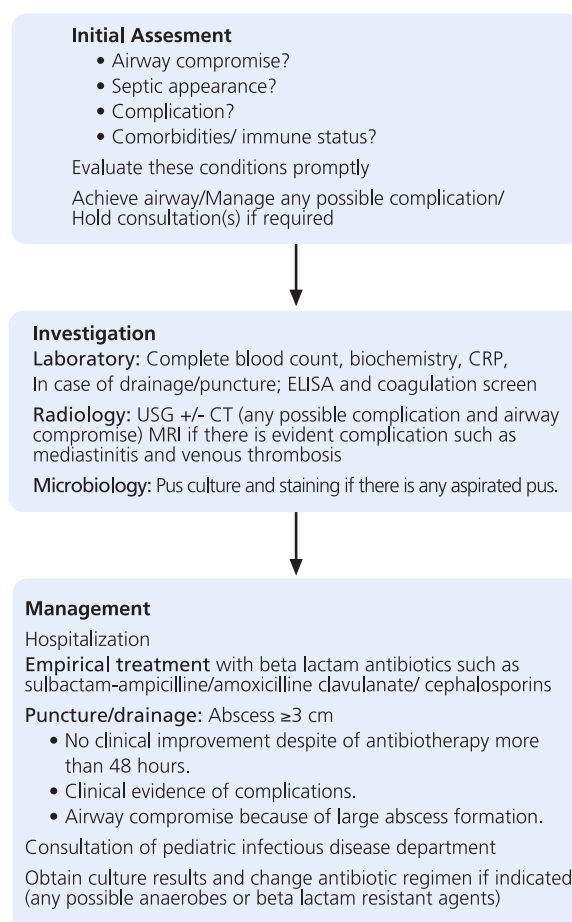


Fig. 1. Management algorithm for pediatric deep neck space infections.

Conclusion

In conclusion, most children with uncomplicated DSNIs can be successfully managed medically and initial surgery is not obligatory. In order to have surgical access to the deep neck spaces, the superficial tissues must be crossed with the risk of injury to the neurovascular structures in the neck. Fluctuating abscesses larger than 3 mm should be drained and pus culture should be obtained for the diagnosis of causative microorganism.

Conflict of Interest: No conflicts declared.

References

- Cheng J, Elden L. Children with deep space neck infections: our experience with 178 children. *Otolaryngol Head Neck Surg* 2013;148:1037–42.
- Wong DK, Brown C, Mills N, Spielmann P, Neeff M. To drain or not to drain – management of pediatric deep neck abscesses: a case–control study. *Int J Pediatric Otorhinolaryngol* 2012;76:1810–3.
- Carbone PN, Capra GG, Brigger MT. Antibiotic therapy for pediatric deep neck abscesses: a systematic review. *Int J Pediatr Otorhinolaryngol* 2012;76:1647–53.
- Songu M, Demiray U, Adibelli ZH, Adibelli H. Bilateral deep neck space infection in the paediatric age group: a case report and review of the literature. *Acta Otorhinolaryngol Ital* 2010;30:190–3.
- Bakir S, Tanriverdi MH, Gün R, et al. Deep neck space infections: a retrospective review of 173 cases. *Am J Otolaryngol* 2012;33:56–63.
- Meyer AC, Kimbrough TG, Finkelstein M, Sidman JD. Symptom duration and CT findings in pediatric deep neck infection. *Otolaryngol Head Neck Surg* 2009;140:183–6.
- Eftekharian A, Roozbahany NA, Vaezaefshar R, Narimani N. Deep neck infections: a retrospective review of 112 cases. *Eur Arch Otorhinolaryngol* 2009;266:273–7.
- Sauer MW, Sharma S, Hirsh DA, Simon HK, Agha BS, Sturm JJ. Acute neck infections in children: who is likely to undergo surgical drainage? *Am J Emerg Med* 2013;31:906–9.
- Flanary VA, Conley SF. Pediatric deep space neck infections: the Medical College of Wisconsin experience. *Int J Pediatr Otorhinolaryngol* 1997;3:38:263–71.
- Rozovsky K, Hiller N, Koplewitz BZ, Simanovsky N. Does CT have an additional diagnostic value over ultrasound in the evaluation of acute inflammatory neck masses in children? *Eur Radiol* 2010;20:484–90.
- Meyer AC, Kimbrough TG, Finkelstein M, Sidman JD. Symptom duration and CT findings in pediatric deep neck infection. *Otolaryngol Head Neck Surg* 2009;140:183–6.
- Raffaldi I, Le Serre D, Garazzino S, et al. Diagnosis and management of deep neck infections in children: the experience of an Italian paediatric centre. *J Infect Chemother* 2015;21:110–3.
- Cramer JD, Purkey MR, Smith SS, Schroeder JW Jr. The impact of delayed surgical drainage of deep neck abscesses in adult and pediatric populations. *Laryngoscope* 2016;126:1753–60.
- Bolton M, Wang W, Hahn A, Ramilo O, Mejias A, Jaggi P. Predictors for successful treatment of pediatric deep neck infections using antimicrobials alone. *Pediatr Infect Dis J* 2013;32:1034–6.
- Neff L, Newland JG, Sykes KJ, Selvarangan R, Wei JL. Microbiology and antimicrobial treatment of pediatric cervical lymphadenitis requiring surgical intervention. *Int J Pediatr Otorhinolaryngol* 2013;77:817–20.
- Baek MY, Park KH, We JH, Park SE. Needle aspiration as therapeutic management for suppurative cervical lymphadenitis in children. *Korean J Pediatr* 2010;53:801–4.

This is an open access article distributed under the terms of the Creative Commons Attribution-NonCommercial-NoDerivs 3.0 Unported (CC BY-NC-ND3.0) Licence (<http://creativecommons.org/licenses/by-nc-nd/3.0/>) which permits unrestricted noncommercial use, distribution, and reproduction in any medium, provided the original work is properly cited.

Please cite this article as: Tahir E, Süslü N, R. Günaydın Ö, Kuşçu O, Ergün O, Akyol U. Pediatric deep neck infections: efficacy of conservative treatment versus immediate surgical intervention. *ENT Updates* 2017;7(2):94–98.