

INVESTIGATION OF DEATH AFTER VIDEO-ASSISTED THORACOSCOPIC SURGERY IN TERMS OF MEDICAL MALPRACTICE: AN AUTOPSY CASE REPORT

VIDEO YARDIMLI TORAKOSKOPİK CERRAHİ İŞLEMİNDEN SONRA MEYDANA GELEN ÖLÜM OLAYININ TIBBİ MALPRAKTİS AÇISINDAN İNCELENMESİ: OTOPSİ OLGUSU

Talip VURAL¹ , Melike ERBAŞ² , Hüseyin Çetin KETENCİ¹ , Mehmet ASKAY² 

¹Trabzon Forensic Medicine Group Precidency, Trabzon, Türkiye

²Council of Forensic Medicine 2nd Specialization Board, İstanbul, Türkiye

ORCID IDs of the authors: T.V. 0000-0003-0720-5669; M.E. 0000-0002-6879-8165; H.Ç.K. 0000-0002-0062-1479; M.A. 0000-0003-1261-9962

Cite this article as: Vural T, Erbaş M, Ketenci HÇ, Askay M. Investigation of death after video-assisted thoracoscopic surgery in terms of medical malpractice: An autopsy case report. J Ist Faculty Med 2024;87(2):180-184. doi: 10.26650/IUITFD.1406102

ABSTRACT

Video-assisted thoracoscopic surgery (VATS) is considered a safe method and is commonly performed in recent years. However, as with other invasive medical procedures, some complications may be encountered during and after this procedure. Of late, medical malpractice cases have become a prominent issue in the healthcare field. The case under discussion was sent to us for autopsy because of an allegation of medical malpractice. The cause of death was claimed to be an invasive procedure, namely pulmonary wedge resection with level 5 lymph node biopsy and VATS. We contribute to the literature by sharing, discussing, and evaluating our autopsy findings with forensic and medical documents. The possible complications of the procedure in question are generally known to be rare, nonfatal, minor traumas.

Keywords: Video-assisted thoracoscopic surgery, medical malpractice, autopsy

ÖZET

Video yardımcı torakoskopik cerrahi (VATS) son yıllarda sıklıkla kullanılmakta olan güvenli bir yöntem olarak kabul edilmektedir. Ancak diğer invaziv tıbbi işlemlerde olduğu gibi bu işlem sonrasında ve sırasında da bazı komplikasyonlarla karşılaşılabilir. Tıbbi uygulama hatası davaları son yıllarda sağlık alanında öne çıkan konulardan biri haline geldi. Olgumuz tıbbi uygulama hatası iddiası nedeniyle otopsi için tarafımıza gönderilmişti. Ölüm nedeninin Seviye 5 lenf bezi biyopsisi ve VATS ile pulmoner kama rezeksiyonu gibi invaziv bir prosedür olduğu iddia ediliyordu. Otopsi bulgularını adli ve tıbbi belgelerle birlikte paylaşarak, tartışarak ve değerlendirerek literatüre katkıda bulunmayı amaçladık. Zira söz konusu işlemin olası komplikasyonları genellikle nadir görülen, ölümcül olmayan küçük travmalar olduğu bilinmektedir.

Anahtar Kelimeler: Video yardımcı torakoskopik cerrahi, tıbbi malpraktis, otopsi

Corresponding author/İletişim kurulacak yazar: Talip VURAL – tlpvrl25@gmail.com

Submitted/Başvuru: 17.12.2023 • **Revision Requested/Revizyon Talebi:** 29.01.2024 •

Last Revision Received/Son Revizyon: 05.02.2024 • **Accepted/Kabul:** 07.03.2024 • **Published Online/Online Yayın:** 22.03.2024



Content of this journal is licensed under a Creative Commons Attribution-NonCommercial 4.0 International License.

INTRODUCTION

Video-assisted thoracoscopic surgery (VATS), usually pulmonary wedge resection, is commonly used to diagnose and treat several pulmonary diseases (1). In the literature, certain complications, such as pneumothorax, chylothorax, pneumonia, acute renal failure, liver failure, pulmonary embolism, postoperative delirium, stroke, atrial fibrillation, and postoperative death, related to this procedure have been reported. However, no case of intraoperative death has so far been encountered. VATS is a reliable and safe approach for the diagnosis and treatment of lung diseases (1-3). We contribute to the literature by evaluating the autopsy findings and all medical and forensic documents in detail.

CASE PRESENTATION

Our patient was a 58-year-old man with a diagnosis of asthma, hypertension, and chronic obstructive pulmonary disease. The medical reports stated that the patient had multiple pulmonary hypermetabolic nodular structures of different sizes, which were prominent in the lower lobe of the left lung. Primary pulmonary malignancy and lymphatic metastases were considered. Using VATS, a biopsy of the level 5 lymph node and wedge resection of the left lung lower lobe were performed. According to medical documents pertaining to the procedure under consideration, 25–30 minutes postoperatively, shortness of breath developed suddenly in the recovery unit. Portal lung radiography was performed considering intrathoracic organ damage, and bleeding was interpreted as normal. The patient was intubated and taken into surgery again. As per the surgery notes, an emergency left thoracotomy was performed on the patient. There was no bleeding in the biopsy area or in the thorax, but massive bleeding that accumulated in the abdomen was observed, and a lesion

was seen on the left hemidiaphragm. The medical documents did not specify the exact location of the lesion on the diaphragm. The documents further stated that general surgery and cardiovascular surgery specialists were also called for the surgery. General surgeons detected 3–4 L of fluid in the abdomen, a 3–4 cm laceration on the anterior side of the spleen, and bleeding in the form of leakage in the tail of the pancreas. Splenectomy and suturing were performed in the tail of the pancreas. Cardiovascular surgeons examined the aorta and its surroundings, but no pathology was detected. The patient, who was intubated and under follow-up and treatment in the intensive care unit, died on the same day. Histopathological examination of the acquired samples revealed that non-small-cell carcinoma had metastasized to the lung and lymph nodes. In addition, predominant extramedullary hematopoietic cell infiltration and iron deposition from young cells of the myeloid series were observed in the splenectomy material.

The corpse was taken to the autopsy table for external examination, and the classical autopsy procedure was applied. Suture materials and bleeding areas resulted from medical procedures performed under the skin of the chest and abdomen, and wound trajectories resulted from medical procedures extending from the left midaxillary line. The ninth intercostal space in the chest was observed. Widespread ecchymotic areas were noted on both sides of the left dome of the diaphragm, and a sutured lesion was present in the anterior part of the left dome (Figure 1). A smooth-edged medical procedure-related (wedge resection) lesion on the distal left lower pulmonary lobe, suture materials, and bleeding areas were detected in the pancreatic tail and the outer surface of the stomach (Figure 2). The spleen was not perceived in its place (splenectomy), and hemorrhagic areas were spotted in the spleen lodge. The abdominal aorta and kidneys were in their natural morphology, and no signs of injury were discerned.

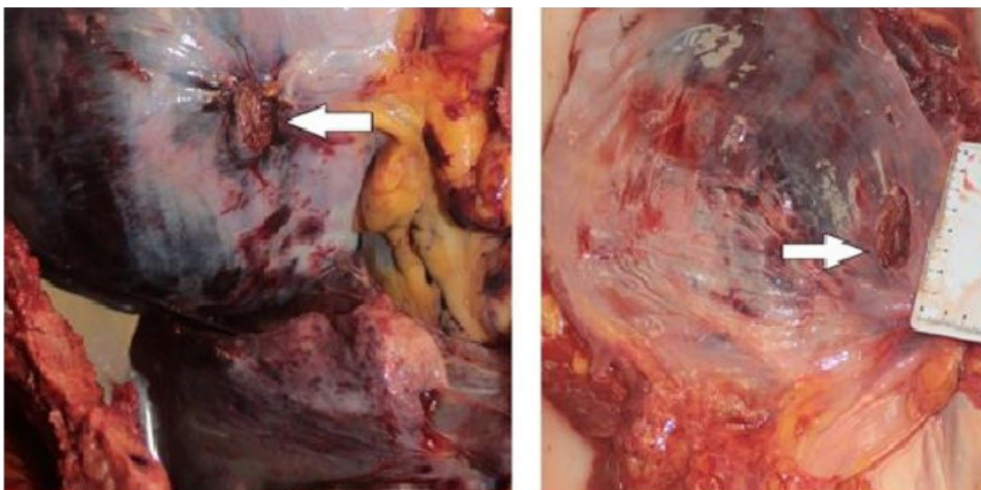


Figure 1: A: Sutured diaphragm lesion before organ dissection at autopsy. B: Sutured diaphragm lesion after organ dissection.

In lung and lymph node samples, which were examined at the macroscopic and microscopic levels, a congested atelectatic lung with malignant tumor infiltration and a hilar lymph node with malignant tumor metastasis were witnessed (Figure 3 A-B). The autopsy was performed as a team, and efforts were made to consult different medical specialties, as required. In toxicological examinations, drug levels were found at the treatment doses.

Medical documents play an essential role in the diagnosis and treatment of the patient and serve as evidences in the event of legal disputes. Therefore, these documents must be prepared accurately and completely (7). Although several medical procedures were performed in the case under study, medical documents were not maintained adequately and carefully.

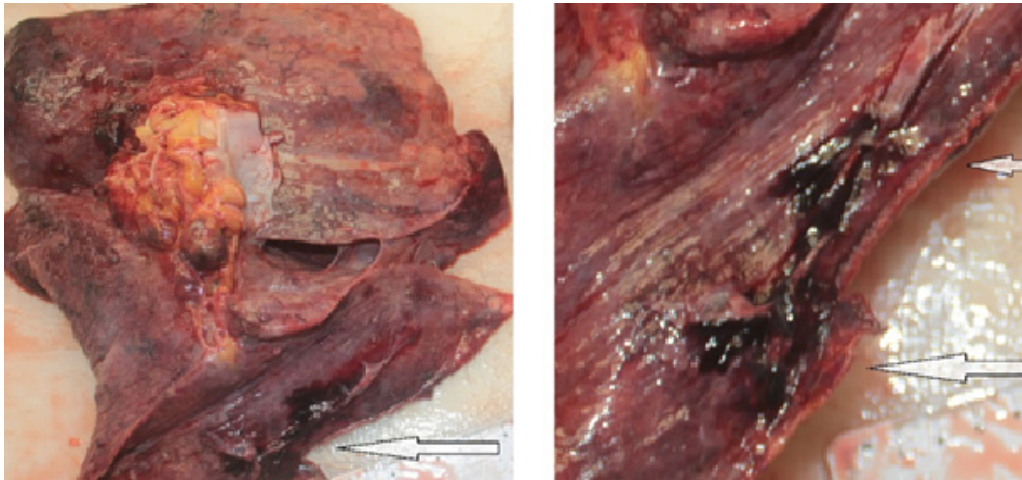


Figure 2: The region of wedge resection performed using the video-assisted thoracoscopic surgery method.

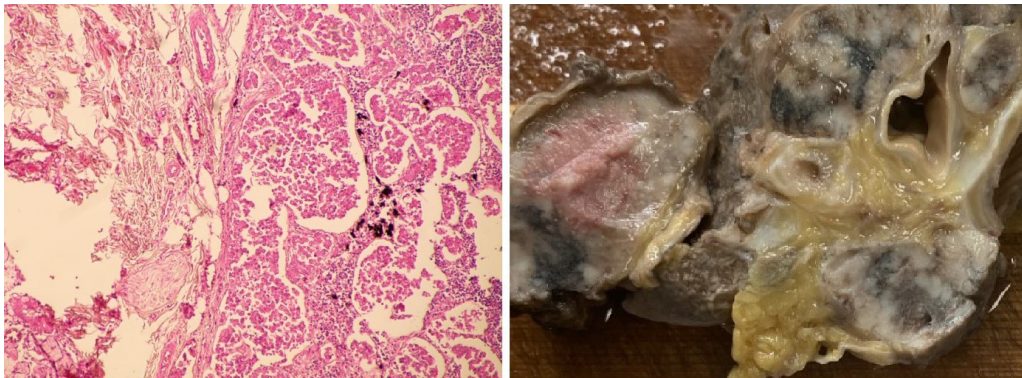


Figure 3: A: Samples of lungs for microscopic examination. B: Macroscopic appearance of a lung sample embedded in formaldehyde.

DISCUSSION

Harm to the patient owing to the physician's recklessness, negligence, or inexperience is termed medical malpractice (4). In the literature, surgical malpractices are classified as intraoperative wrong decisions, operative complications, and operative mistakes (5). Of late, the concept of malpractice has become one of the most frequently discussed topics in the healthcare field. Although the prevalence and size of malpractice litigations are unknown, there has been an increase in the number of accusations on all healthcare professionals, especially those on physicians, in recent years (6).

Lung cancer is one of the most common cancers worldwide, the frequency of which is increasing day by day, and it is the most common cause of cancer-related death (8). Cell blocks, cytological samples, resections, endobronchial biopsies, core biopsies, and fine-needle aspirations are conducted to diagnose lung cancer. These procedures should be performed safely and less invasively (9). In imaging studies performed in this study, hypermetabolic nodular structures were detected in the left lung, and primary pulmonary malignancy and lymphatic metastases were considered. Wedge resection of the lower lobe was performed.

VATS has now become a reliable approach that is commonly used in the diagnosis and treatment of lung diseases. This procedure is used for various purposes, such as pulmonary wedge resection, pleural and mediastinal biopsy, pleurectomy, and pneumothorax treatment (1). The literature has reported that complications occur at a rate of 7%–8.6% after this procedure. Pneumothorax, chylothorax, pneumonia, acute renal failure, liver failure, pulmonary embolism, postoperative delirium, stroke, and atrial fibrillation are the important and common complications. No case of intraoperative death has been reported in the literature. Postoperative mortality varies between 0.6% and 2% (1-3, 10). Vascular injury and intrathoracic bleeding have often been described in several studies (10-12). In a similar study in the literature, spleen injury was detected on computed tomography in a patient who was hypotensive and had low hematocrit values during postprocedure follow-up, and splenectomy was performed. These are some of the complications associated with the procedure (10).

Contrary to the complications commonly described in the literature, intraabdominal hemorrhage and spleen rupture were detected during the intraoperative and postoperative periods in our patient. In the autopsy, no traumatic lesion was detected either in the chest or in the abdomen, except for the surgical lesions. Contrary to the claims, the kidney and abdominal aorta were intact during the autopsy. The lesions observed on the diaphragm, pancreas, and stomach were determined to be surgical incisions. In this case, an opinion was also requested from the First Specialized Department of the Istanbul Forensic Medicine Institute by the relevant judicial body. The death of the patient was attributed to lymph cancer that had spread to other organs and the complications resulting from it (spleen rupture). Although splenic rupture and intraabdominal bleeding are not among the common complications of VATS, these have rarely been reported in the literature (10). We have emphasized this situation, which is quite rare, in our study. Another noteworthy point in this case is that patients and their relatives should be properly informed to prevent malpractice claims.

Although deficiencies prevailed in the medical documentation and in the stages of informing the patient's relatives, the complication was quickly evaluated. Radiological imaging, laboratory tests, and consultations were performed rapidly, the patient was immediately taken into surgery, and interventions were made to protect the patient's life as a team with the participation of relevant surgeons. Hence, it was concluded that the medical procedure was performed in accordance with the rules of scientific medicine and that the medical personnel did not have any legal responsibility.

CONCLUSION

Before VATS or similar medical interventions, patients and their relatives should be carefully and properly informed in detail by the physician who performs the procedure. Furthermore, physicians performing this procedure must have sufficient anatomical knowledge and the required technical equipment. The physicians must have adequate knowledge and experience regarding possible complications that may arise during the procedure and the necessary interventions.

Medical documents should be prepared elaborately and completely in case of legal disputes between the patient and the doctor after the procedure as these may also provide some evidence. Furthermore, facilities provided by the autopsy should be considered in medical malpractice cases to clarify the case and determine the truth. However, the duration of final decision and workload of the Council of Forensic Medicine are also important factors. Legal regulations should be formulated to enable appropriate consultations from relevant specialties at the place where the autopsy is initially performed.

Informed Consent: Written informed consent was obtained from patient who participated in this study.

Peer Review: Externally peer-reviewed.

Author Contributions: Conception/Design of Study- T.V., M.E., M.A.; Data Acquisition- T.V., M.E.; Data Analysis/Interpretation- T.V., M.A.; Drafting Manuscript- T.V., M.E., H.Ç.K.; Critical Revision of Manuscript- T.V., M.A.; Final Approval and Accountability- T.V., M.E.

Conflict of Interest: The authors have no conflict of interest to declare.

Financial Disclosure: The authors declared that this study received no financial support.

REFERENCES

1. Roviato GC, Varoli F, Vergani C, Maciocco M. State of the art in thoracoscopic surgery. *Surg Endosc* 2002;16:881-92. [\[CrossRef\]](#)
2. Solaini L, Prusciano F, Bagioni P, Di Francesco F, Poddie DB. Video-assisted thoracic surgery (VATS) of the lung: analysis of intraoperative and postoperative complications over 15 years and review of the literature. *Surg Endosc* 2008;22(2):298-310. [\[CrossRef\]](#)
3. Sezen CB, Dogru MV, Tanrikulu G, Aker C, Erduhan S, Saydam O, et al. Comparison of short-term results of subxiphoid and conventional video-assisted thoracoscopic surgery in diagnostic wedge resections. *Asian Cardiovasc Thorac Ann* 2023;31(2):115-22. [\[CrossRef\]](#)
4. Türk Tabipleri Birliği. Hekimlik mesleği etik kuralları. Türk Tabipleri Birliği Yayınları, 2021. 06.06.2023. www.ttb.org.tr/kutuphane/h_etikural.pdf

5. Tümer AR, Dener C. Evaluation of surgical malpractice in Turkey. *Leg Med* 2006;8(1):11-5. [CrossRef]
6. Erg H, Kiroğlu F. Tıbbi malpraktisde hekimlerin cezai sorumlulukları. *Atlas Journal* 2021;7(44):2227-42.
7. World Health Organization. Medical records manual: a guide for developing countries. 2006. February 15, 2023. https://iris.who.int/bitstream/handle/10665/208125/9290610050_rev_eng.pdf?sequence=1%26isAllowed=y Accessed
8. World Health Organization. Cancer2018. March 20, 2023. <https://www.who.int/news-room/fact-sheets/detail/cancer>.
9. Akyürek N, Öz B, Kaya H, Nart D, Bozkurtlar E, Mungan S, et al. Küçük Hücreli Dışı Akciğer Kanserinde ROS1 Rearanjmanı: Türkiye’de ROS1 Testine Yaklaşım. *J Curr Pathol* 2022;1:6-15.
10. Flores RM, Ihekweazu U, Dycoco J, Rizk NP, Rusch VW, Bains MS, et al. Video-assisted thoracoscopic surgery (VATS) lobectomy: catastrophic intraoperative complications. *J Thorac Cardiovasc Surg* 2011;142(6):1412-7. [CrossRef]
11. Imperatori A, Rotolo N, Gatti M, Nardecchia E, De Monte L, Conti V, et al. Peri-operative complications of video-assisted thoracoscopic surgery (VATS). *Int J Surg* 2008;6(Suppl 1):S78-81. [CrossRef]
12. Ryabov AB, Pikin OV, Bagrov VA, Aleksandrov OA, Barmin VV, Rudakov RV, et al. Intraoperative and early surgical complications after VATS lobectomy. *Khirurgiia* 2023;9:13-9. [CrossRef]