



Recurrent Mucoepidermoid Carcinoma of the Maxillary Sinus Maksiller Sinüste Tekrarlayan Mukoepidermoid Karsinom

Selin Alacahan¹, Büşra Geçgil¹, Arife Beyza Doğan¹, Fatma Şenel¹, Hatice Karaman¹

¹ University of Health Sciences, Kayseri City Training and Research Hospital, Department of Pathology, Kayseri, Türkiye

ABSTRACT

Mucoepidermoid carcinoma is a type of cancer that originates in the salivary glands, and while it's most commonly found in the parotid gland, it can also occur in the maxillary sinus. This is a very rare location for the cancer, but it can present significant challenges. Our patient was admitted to the hospital presenting with nonspecific symptoms such as nasal obstruction and nasal bleeding. Following a histopathological and immunohistochemical examination of the biopsy, the diagnosis of was diagnosed as "mucoepidermoid carcinoma." Postoperative radiotherapy was administered due to the incomplete removal of the mass caused by its anatomical location. The tumor recurred in the patient after a two-year period. In this article, we present a case of recurrent mucoepidermoid carcinoma in the maxillary sinus.

Keywords: Maxillary sinus, mucoepidermoid carcinoma, recurrent

ÖZET

Mukoepidermoid karsinom, tükürük bezlerinde ortaya çıkan bir kanser türüdür ve en sık parotis bezinde bulunmasına rağmen maksiller sinüste de görülebilir. Bu kanser için çok nadir bir yerleşim yeridir, ancak önemli zorluklara yol açabilir. Hastamız burun tıkanıklığı ve burun kanaması gibi nonspesifik semptomlarla hastaneye kaldırıldı. Biyopsinin histopatolojik ve immünohistokimyasal incelemesi sonrasında tanı "mukoepidermoid karsinom" olarak konuldu. Kitle anatomik konumundan dolayı tam olarak çıkarılmadığı için ameliyat sonrası radyoterapi uygulandı. Tümör iki yıllık bir süreden sonra hastada tekrarladı. Bu yazıda maksiller sinüste tekrarlayan mukoepidermoid karsinom vakasını sunuyoruz.

Anahtar Kelimeler: Maksiller sinüs, mukoepidermoid karsinom, tekrarlayan

INTRODUCTION

Malignancies of the paranasal sinuses and nasal cavity account for less than 1% of all malignancies (1). The majority of tumors in the maxillary sinus are squamous cell carcinomas (2). Nonsquamous cell cancers of the maxillary sinus are rare (3). Although the exact pathogenesis is not fully understood, some studies have identified tobacco use, alcohol consumption, and previous exposure to radiation as potential risk factors (4). This type of cancer is twice as common in males as in females, with the most prevalent age range being 50-70 years old (5). Mucoepidermoid carcinoma (MEC) is a type of salivary gland cancer that can occur in various locations, including the maxillary sinus, which is a cavity in the facial area. The cancer is characterized by a mix of mucous-secreting cells and squamous cells. The prognosis of MEC depends on early detection, histological grade, and the clinical stage of the

tumor. Treatment options include surgery, radiotherapy, and chemotherapy (6). In this article, we present a case of recurrent mucoepidermoid carcinoma in the maxillary sinus.

CASE REPORT

An 82-year-old female patient was admitted to our hospital with complaints of nasal obstruction and intermittent nasal bleeding. Magnetic resonance imaging revealed a 4.5x3 cm lobular contoured mass lesion in the left maxillary sinus floor. The left maxillary sinus floor and medial and lateral walls showed an infiltrated appearance. An incisional biopsy was performed on the mass. The histopathological examination revealed cystic enlarged glands surrounded by mucinous epithelium, leading to a diagnosis of a biopsy was recommended for a definitive diagnosis. Subsequently,

Corresponding Author: Selin Alacahan, Kayseri City Hospital, Department of Pathology, Kayseri, Turkey **Email:** s_urhan5860@windowslive.com

Cite this article as: Alacahan S, Geçgil B, Doğan AB, Şenel F, Karaman H. Recurrent Mucoepidermoid Carcinoma of the Maxillary Sinus. JAMER 2024;9(2):80-83.

Received : 2023.12.26

Accepted : 2024.03.24

Online Published : 2024.08.15

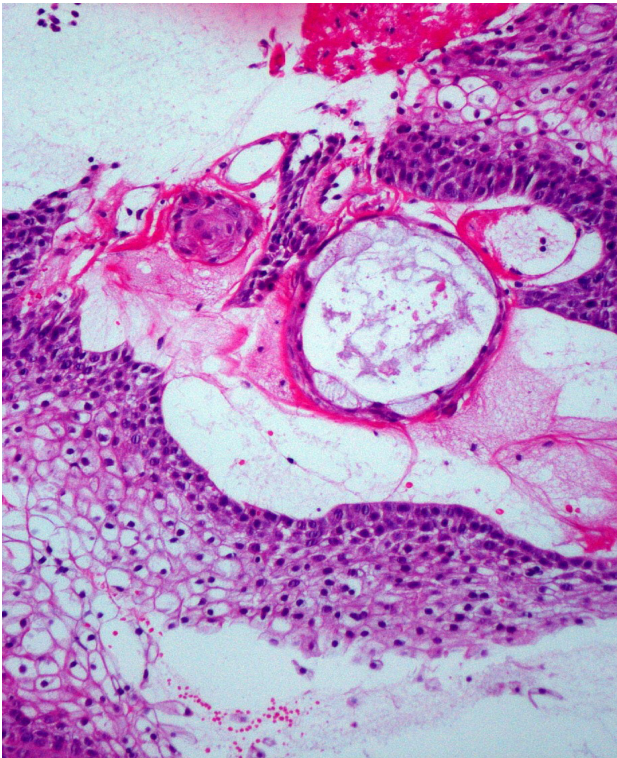


Figure 1. Cystic enlarged glands surrounded by mucinous epithelium in some areas (HEX40).

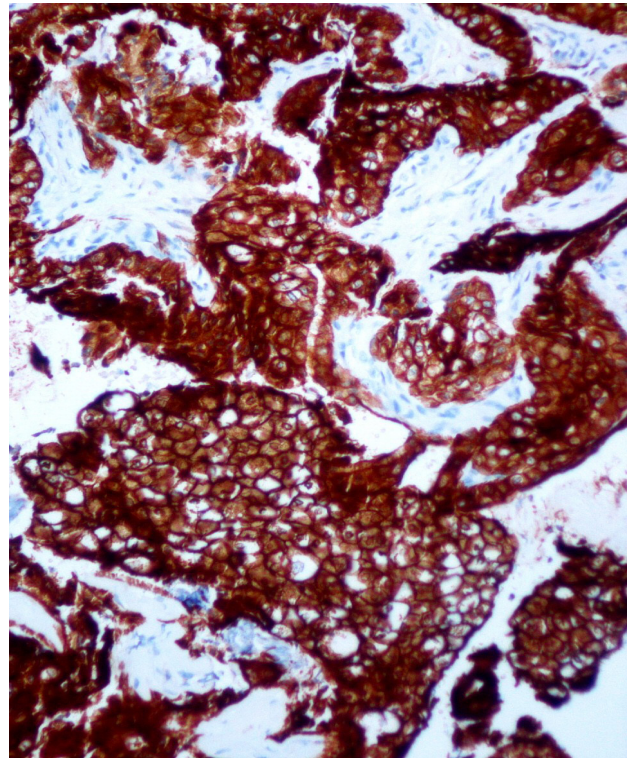


Figure 2. CK7 was positively stained in the epithelial areas (IHCx40)

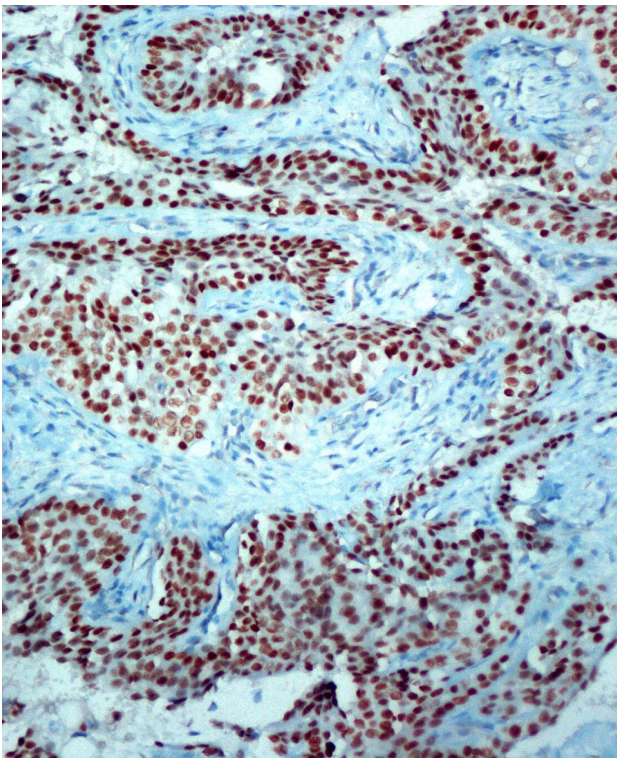


Figure 3. P63 was positively stained in the epithelial areas (IHCx40).

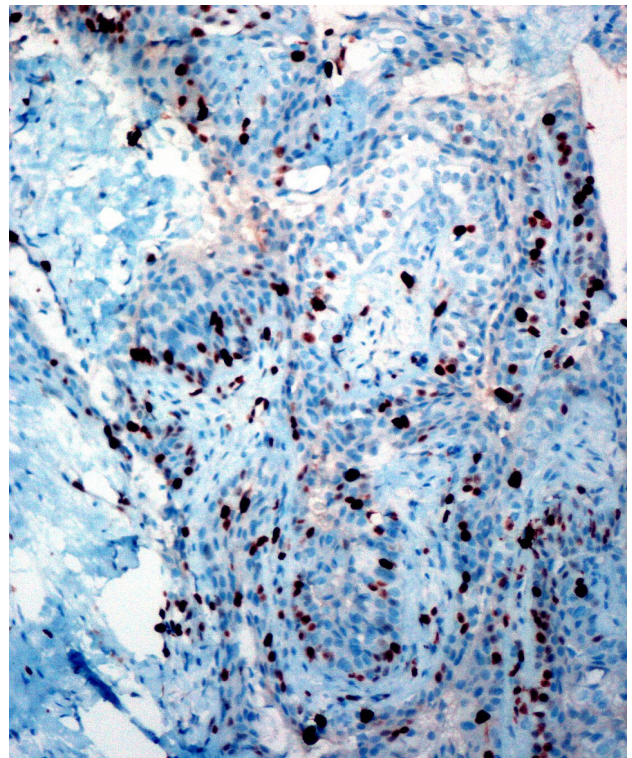


Figure 4. Ki-67 immunohistochemical staining (IHCx40).

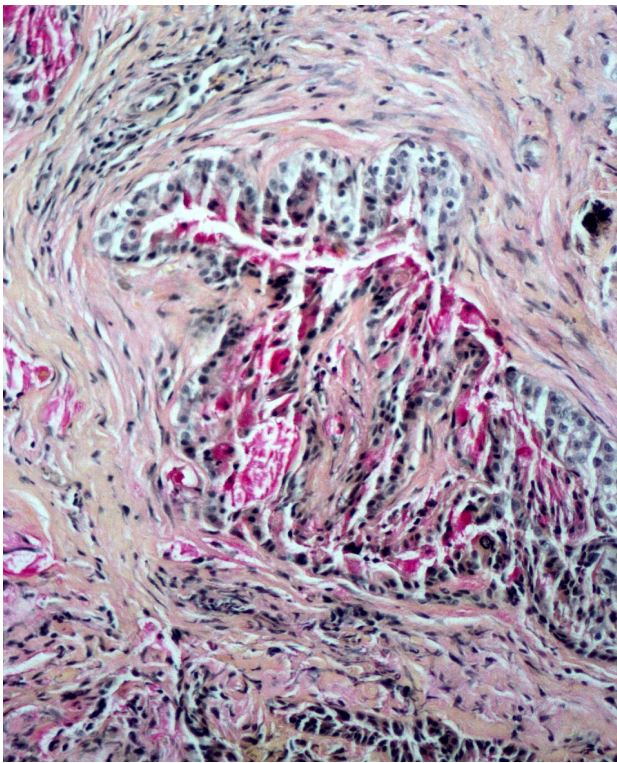


Figure 5. Mucinous areas stained positively with mucicarmine stain (Mucicarmine x40).

a 0.7-cm tissue sample was obtained from the patient.

The histopathological examination of this tissue revealed islands of squamous cells. Additionally, cystic enlarged glands surrounded by mucinous epithelium were observed in some areas (Fig. 1). Immunohistochemical examination showed positive staining for CK7 and P63 in the epithelial areas. The Ki67 proliferation index was approximately 5-10% (Figs. 2, 3, 4). Histochemically, mucinous areas stained positively with mucicarmine stain (Fig. 5). The case was reported as “mucoepidermoid carcinoma, intermediate grade” with these findings.

Subsequently, the patient received 12 cures of radiotherapy were administered to the patient’s symptoms recurred after two years. A PET/CT scan revealed intense hypermetabolism at the left maxilla floor, indicating a moderate hypermetabolic soft tissue increment area extending superiorly to the infraorbital section and nasal cavity. A biopsy was performed, and the histopathological and immunohistochemical examination results of a 0.7-cm tissue were consistent with the previous findings. The case was once again diagnosed as “mucoepidermoid carcinoma.”

DISCUSSION

Mucoepidermoid carcinoma is a malignant epithelial neoplasm that contains both mucus-secreting cells and epidermoid-type cells (7). MEC of the maxillofacial region

originates from the epithelium surrounding the maxillary sinus, salivary glands, or bones of the mandible (8).

Mucoepidermoid carcinoma is rare in the paranasal sinuses. In a study, the majority of 220 nasal and paranasal sinus carcinomas (126 cases) were squamous cell carcinomas. Others included adenoid cystic carcinoma (35 cases), undifferentiated carcinoma (30 cases), adenocarcinoma (25 cases), and MEC in only 4 cases, respectively (9). Mucoepidermoid carcinoma of the maxillary sinus is asymptomatic in the early stage. Nonspecific symptoms such as nasal obstruction, pain, nasal bleeding, facial swelling, and dysphagia can be observed (10).

Maxillary sinus malignancies are challenging tumors to treat and often have a poor prognosis (11). Surgical resection is complicated due to the tumor’s anatomical location. Achieving a negative surgical margin during resection is technically challenging, and radiotherapy is typically used for palliative treatment (12). In our case, complete surgical resection of the tumor was not possible, so postoperative radiotherapy was administered.

These tumors are often identified in advanced stages and lead to frequent local recurrence, with a 5-year survival rate of 36% (13). The tumor in our case also recurred after two years.

Early diagnosis is crucial for the prognosis of this tumor. MEC should also be considered in the differential diagnosis of maxillary masses.

Conclusion

MEC of the maxillary sinus is rare and causes nonspecific symptoms. Early diagnosis is crucial for the prognosis of MEC, so it should also be considered in cases of maxillary sinus tumors.

Informed Consent: Written informed consent was obtained from the subject for the publication of the study.

Conflict of Interest: The authors declare no conflict of interest in this study.

Financial Disclosure: No financial support was received from any institution or organization for this study.

REFERENCES

1. Dulguerov P, Jacobsen MS, Allal AS, Lehmann W, Calcaterra T. Nasal and paranasal sinus carcinoma: are we making progress? A series of 220 patients and a systematic review. *Cancer*. 2001 Dec 15;92(12):3012-3029.
2. Osguthorpe JD, Richardson M. Frontal sinus malignancies. *Otolaryngol Clin North Am* 2001;34:269-281.

3. Bhattacharyya N. Survival and staging characteristics for nonsquamous cell malignancies of the maxillary sinus. *Arch Otolaryngol Head Neck Surg* 2003;129:334-337.
4. 't Mannelje A, Kogevinas M, Luce D, Demers PA, Bégin D, Bolm-Audorff U, et al. Sinonasal cancer, occupation, and tobacco smoking in European women and men. *Am J Ind Med*. 1999 Jul;36(1):101-107.
5. Carrau RL, Myers EN, Johnson JT. Paranasal sinus carcinoma - diagnosis, treatment, and prognosis. *Oncology* 1992;6:43-50.
6. Bishop JA. Recently described neoplasms of the sinonasal tract. *Semin Diagn Pathol*. 2016 Mar;33(2):62-70.
7. Seifert G, Sobin LH. Histological typing of salivary gland tumours. In *International Classification of tumours*. New York: Springer-Verlag; 1991.
8. Brookstone MS, Huvos AG. Central salivary gland tumors of the maxilla and mandible: A clinicopathologic study of 11 cases with an analysis of the literature. *J Oral Maxillofac Surg* 1992;50:229-236.
9. Dulguerov P, Jacobsen MS, Allal AS, Lehmann W, Calcaterra T. Nasal and paranasal sinus carcinoma: are we making progress? A series of 220 patients and a systematic review. *Cancer*. 2001 Dec 15;92(12):3012-3029.
10. Stevens CM, Huang SH, Fung S, Bayley AJ, Cho JB, Cummings BJ, et al. Retrospective study of palliative radiotherapy in newly diagnosed head and neck carcinoma. *Int J Radiat Oncol Biol Phys*. 2011 Nov 15;81(4):958-963.
11. Triantafyllou V, Maina IW, Kuan EC, Kohanski MA, Tong CC, Patel NN, et al. Sinonasal mucoepidermoid carcinoma: a review of the National Cancer Database. *Int Forum Allergy Rhinol*. 2019 Sep;9(9):1046-1053.
12. Barcello AN, Carvalbo CP, Teixeira DC, Machado JA, Barreiro AC, Barcellos TN. A rare case of mucoepidermoid carcinoma of the nasal septum. *Intl Arch Otorhinolaryngol. Sao Paulo* 2008;12(4):582-586.
13. da Cruz Perez DE, Pires FR, Lopes MA, de Almeida OP, Kowalski LP. Adenoid cystic carcinoma and mucoepidermoid carcinoma of the maxillary sinus: report of a 44-year experience of 25 cases from a single institution. *J Oral Maxillofac Surg*. 2006 Nov;64(11):1592-1597.