



CASE REPORT

Maxillary Sinus Barotrauma with Infraorbital Nerve Paresthesia After Scuba Diving: A Case Report

Mehmet Zahit BAŞ, Assist. Prof., Semiha Seda ŞAHİN, PhD

Department of Oral and Maxillofacial Surgery, Faculty of Dentistry, University of Health Sciences, Istanbul, Türkiye

ABSTRACT

Barotrauma is defined as pressure-induced tissue injury. Paranasal sinus barotrauma of descent (sinus squeeze) is the result of negative pressure in the sinus cavity. Upper respiratory tract infections, nasosinusal pathologies, inappropriate diving techniques and forceful Valsalva's manoeuvres are common predisposing factor for paranasal sinus barotrauma. The management of paranasal sinus barotrauma includes: Prevention with vasoconstrictor drops, hyperbaric oxygen therapy and surgery. The aim of this case report is to evaluate diagnosis and treatment options of maxillary sinus barotrauma that is a very rare condition in dentistry.

Keywords: barotrauma, maxillary sinus, oral surgery

INTRODUCTION

Paranasal sinus barotrauma or aeorosinusitis is defined as tissue damage due to sudden pressure changes. It results from an inability to balance pressure in the sinuses, which is caused by the rapid change in barometric pressure difference between the intrasinusal air and the surrounding atmosphere^{1,2}.

Sinus barotrauma due to negative air pressure during descent while diving is termed 'sinus squeeze' which causes, oedema, mucosal congestion and haemorrhage within the cavity, accompanied by immediate facial pain².

Paranasal sinus barotrauma is the result of negative pressure in the sinus cavity and it is the most common type of barotrauma following middle ear barotrauma in diving related problems among SCUBA divers^{3,4}. Maxillary sinus barotrauma is the most common type of paranasal sinus barotrauma⁵.

In this case, we present the treatment of left maxillary sinus barotrauma accompanied by infraorbital nerve involvement after scuba diving.

CASE REPORT

A 25 years old systematically healthy male patient was applied to University of Health Sciences, Oral and Maxillofacial Surgery

Department with complaints of pain in the left maxillary sinus area and infraorbital nerve paresthesia after scuba diving. The final diagnosis of paranasal sinus barotrauma is made after clinical and radiographic examination (panoramic radiograph and magnetic resonance imaging (MRI). Congestion filling the left maxillary sinus was observed on MRI. (Fig.1) The patient had complaints of numbness and tingling sensation in the left upper lip, cheek and lateral of the nose. This was due to compression on the infraorbital nerve.

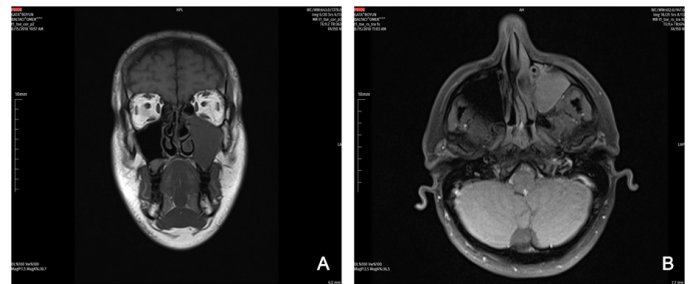


Fig. 1. Pre-operative magnetic resonance imaging (MRI).

A. Coronal plane. Congestion in the left maxillary sinus [arrow].
B. Axial plane. Congestion in the left maxillary sinus [arrow].

His complaints didn't decrease with conservative treatment. Therefore, Caldwell-Luc operation was applied to the patient under local anesthesia and the left maxillary sinus was treated surgically. In the surgical treatment, sinus drainage was

Corresponding Author: Mehmet Zahit Baş, Assist. Prof.

Address : Sultan Abdulhamid Han Research Hospital, University of Health Sciences, Tibbiye Street, Number: 38 34668
Uskudar/İstanbul

Mobile : +90 (533) 039 74 48

e-mail : mehmet_bass@windowslive.com ORCID: 0000-0003-0892-4067

performed with the Caldwell Luc procedure. (Fig.2) After the procedure oral antibiotics, analgesics and nasal decongestants were prescribed. In addition post-operative sinus precautions were explained to the patient and he was followed up for 3 years and no complaints received (Fig. 3)

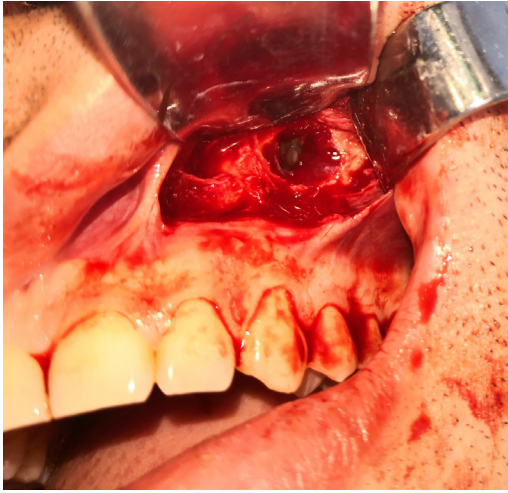

Fig. 2. Caldwell-Luc surgery in the left maxillary sinus.

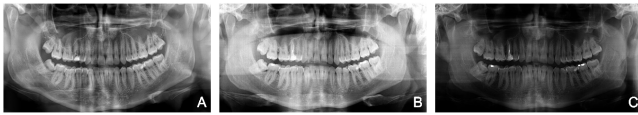

Fig. 3. Post-operative controls after Caldwell-Luc surgery.

- A. First year after the surgery.
- B. Second year after the surgery.
- C. Third year after the surgery.

DISCUSSION

Barotrauma is the damage caused by the direct effect of pressure on the tissues. Generally, recreational scuba diving takes place at depths of 60 to 130 ft (~18-40 m), where a pressure level of 3 to 5 atm is equivalent to absolute pressure.

The sinus ostia must remain open throughout the dive to equalize the ambient pressure through the nose. If it fails to equalize the pressure during descent, a vacuum effect occurs within the sinus and mucosal congestions, eodema, hemorrhagic bullae and free blood may be seen⁶.

In our case, maxillary sinus barotrauma was observed in the patient who was afraid of diving at a depth of 5 meters and made a rapid ascent, didn't equalize the pressure.

Maxillary sinus is one of the most common site for paranasal sinus barotrauma. In addition the frontal, ethmoid, and sphenoid sinuses may also be affected as well as more than one sinus can be affected in one patient. Maxillary sinus squeeze causes pain that can be seem as caused by the teeth

of the upper jaw. The maxillary division of the fifth cranial nerve can be damaged by excessive pressure as it passes through the sinus covered with the mucous membrane. This can cause a loss of sensation over unilateral side of the upper face^{7,8,9}.

In the literature, cases of paraesthesia of the nerve infraorbital nerve related to maxillary sinus barotrauma have been reported^{7,8,9}. In this case, in accordance with these cases, reflected pain in the maxillary teeth caused by the pressure on the posterior superior alveolar branch, and numbness and tingling in the lips and cheeks due to the presthesis of the infraorbital nerve were observed.

Although radiological reports of sinus barotraumias are scarce; they can be detected with plain films, computed tomography and magnetic resonance imaging².

Recurrent sinus barotrauma should be differentiated from chronic sinusitis. Patients with evidence of chronic sinusitis should be treated with appropriate medical therapy¹⁰. Sinus surgery is recommended if radiological signs of the disease persist. In addition, patients who have clinical and radiological signs of sinusitis are always at risk for barotrauma while scuba diving due to ostial insufficiency⁶.

Primarily, medical treatment was chosen, and when it was unsuccessful, patient was treated surgically. After the surgery, the patient's current pain and paresthesia complaints disappeared and no symptoms were observed except chronic sinusitis symptoms during the follow-up period.

ACKNOWLEDGEMENT

Source of Finance

The study needs no financial support.

Conflict of Interest

The authors have no conflict of interest to declare.

Authorship of Contributions

Mehmet Zahit Baş and Semiha Seda Şahin designed the study and gathered the data. Mehmet Zahit Baş analyzed the data. Mehmet Zahit Baş and Semiha Seda Şahin wrote the majority of draft.

REFERENCES

1. R V, B van H, I C, J M. Frontal Sinus Barotrauma. *J Belgian Soc Radiol.* 2016;100(1). doi:10.5334/JBR-BTR.908
2. C B, A G. Sphenoid sinus barotrauma after free diving. *Am J Otolaryngol.* 2011;32(2):159-161. doi:10.1016/J.AMJOTO.2009.10.005
3. P MM, S DA, G JL, M WL E. Underwater medicine: otolaryngologic considerations of the skin and scuba diver. In: Reuter SH, ed. *Otolaryngology.* WB Saunders; 1991:3231-57.
4. LM N. Otolaryngology and sport scuba diving. Update and guidelines. *Ann Otol Rhinol Laryngol Suppl.* 1985;115:1-12. Accessed September 6, 2021. <https://pubmed.ncbi.nlm.nih.gov/2857546/>
5. P F, B M, C E. Sinus barotrauma in divers. *Ann Otol Rhinol Laryngol.* 1976;85(1 Pt 1):61-64. doi:10.1177/000348947608500110
6. GD B, GJ P. Barotrauma of the ears and sinuses after scuba diving. *Eur Arch Otorhinolaryngol.* 2001;258(4):159-163. doi:10.1007/S004050100334
7. B FK, B AA. Infraorbital hypesthesia after maxillary sinus barotrauma. *Undersea Hyperb Med.* 1999;26(4):257-259.
8. G LM. Maxillary sinus barotrauma - Case report and review. *Aviat Sp Environ Med.* 1985;56(8):796-802.
9. AW M, DJ S, TJ F, RT C. Maxillary sinus barotrauma with fifth cranial nerve involvement. *J Laryngol Otol.* 1991;105(3):217-219. doi:10.1017/S0022215100115415
10. T S, I B, T B, N C, PK P, C K. Medical and surgical treatment in divers with chronic rhinosinusitis and paranasal sinus barotrauma. *Eur Arch Otorhinolaryngol.* 2012;269(3):853-860. doi:10.1007/S00405-011-1742-4