

# Diagnostic Value of Ultrasonographic Septation in the Differentiation of Scrotal Hematocele and Hydrocele: A Single-Center, Retrospective Study

## Skrotal Hematosel ve Hidrosel Ayırımında Ultrasonografik Septasyonun Tanısal Değeri: Tek Merkezli, Retrospektif Bir Çalışma

Reşad Beyoğlu<sup>1\*</sup>, Ramazan Serdar Arslan<sup>2</sup>, Murat Seyit<sup>3</sup>, Mert Özen<sup>3</sup>

1. Emergency medicine specialist. Denizli Servergazi state hospital, Emergency department, Denizli, Türkiye

2. General surgeon. Denizli Servergazi state hospital, General surgery clinic, Denizli, Türkiye.

3. Emergency medicine assistant professor. Pamukkale university faculty of medicine. Denizli, Türkiye

### ABSTRACT

**Aim:** Since the scrotum and testicles are superficial organs, they can be easily examined by palpation and sometimes transillumination. However, it is not possible to distinguish whether the fluid in the scrotum is hydrocele or hematocele. This study attempts to find an ultrasonographic distinction between hematocele and hydrocele based on a simple finding (septation) that every physician can recognize.

**Methods:** Patients who were admitted to the emergency department (ED) with complaints of scrotal pain, swelling or redness were divided into two groups: those whose complaints developed due to trauma and those whose complaints developed spontaneously. All included patients underwent scrotal US/Doppler by an emergency medicine specialist with US training.

**Results:** Of the 61 patients included in the study, 36 (59%) presented with scrotal trauma and 25 (41%) with non-traumatic complaints. While hematocele was detected in 8 (22.2%) and hydrocele was detected in 1 (2.8%) of 36 patients with a history of trauma, neither hematocele nor hydrocele was detected in 27 (75%). On the other hand, septation was detected in 6 of 8 hematocele patients (75%), but no septation was detected in 2 (25%) patients ( $p = 0.013$ ). However, no signs of septation were found in any of the 28 patients who presented due to scrotal trauma and had no signs of hematocele. When patients with a history of scrotal trauma were categorized according to duration, no signs of septation were detected in 12 patients who had acute or scrotal trauma within 1 week, while signs of septation were detected in 6 of 24 patients (25%) with a history of scrotal trauma 1-4 weeks ago ( $p = 0.043$ ).

**Conclusion:** When septation is seen on the US of a patient who presents to the ED with scrotal pain, swelling, or ecchymosis, hematocele must first be ruled out. The presence of septation is not useful in acute trauma for distinguishing hematocele from hydrocele, but it may be useful in distinguishing chronic hematocele from acute hematocele or hydrocele.

Key words: hematocele, hydrocele, septation, ultrasound, emergency department.

### ÖZ

**Amaç:** Skrotum ve testisler yüzeysel organlar olduğundan dolayı palpasyonla ve bazen de transillüminasyonla kolaylıkla incelenebilir. Ancak bu yöntemlerle skrotumdaki sıvının hidrosel mi yoksa hematosel mi olduğunu ayırt etmek mümkün değildir. Bu çalışma, her hekimin tanıyabileceği basit bir bulguya (septasyon) dayanarak hematosel ve hidrosel arasındaki ultrasonografik ayrımı bulmaya çalışmaktadır.

**Yöntem:** Acil servise (AS) skrotal ağrı, şişlik veya kızarıklık şikayeti ile başvuran hastalar, şikayetleri travmaya bağlı ve şikayetleri spontan olarak gelişenler olmak üzere iki gruba ayrıldı. Çalışmaya dahil edilen tüm hastalara US/ Doppler eğitimini almış bir acil tıp uzmanı tarafından skrotal US/Doppler yapıldı.

**Bulgular:** Çalışmaya dahil edilen 61 hastanın 36'sı (%59) skrotal travma, 25'i (%41) ise travma dışı şikayetlerle başvurdu. Travma öyküsü olan 36 hastanın 8'inde (%22,2) hematosel, 1'inde (%2,8) hidrosel saptanırken, 27'sinde (%75) ne hematosel ne de hidrosel saptandı. Sekiz hematosel hastasının 6'sında (%75) septasyon saptanırken, 2'sinde (%25) septasyon saptanmadı ( $p=0,013$ ). Öte yandan; skrotal travma nedeniyle başvuran ve hematosel bulgusu olmayan 28 hastanın hiçbirinde septasyon bulgusu rastlanmadı. Skrotal travma öyküsü olan hastalar, süreye göre gruplandırıldığında, akut veya 1 hafta içinde skrotal travma geçiren 12 hastanın hiçbirinde septasyon bulgusu rastlanmamışken, 1-4 hafta önce travma geçiren 24 hastanın 6'sında (%25) septasyon bulgusu saptanmıştır ( $p=0,043$ ).

**Sonuç:** Acil servise skrotal ağrı, şişlik veya ekimoz şikayetiyle başvuran bir hastanın US'de septasyon görüldüğünde öncelikle hematosel dışlanmalıdır. Septasyon varlığı akut travmada hematoselin hidroselden ayırımında yararlı değildir, ancak kronik hematoselin akut hematosel veya hidroselden ayırımında yararlı olabilir.

Anahtar kelimeler: hematosel, hidrosel, septasyon, ultrason, acil servis.

RECEIVED: 31.01.2024 ACCEPTED: 05.05.2024 PUBLISHED (ONLINE): 30.08.2024

\*Corresponding Author: Reşad Beyoğlu, MD. Bereketler, Bereket Cd. No:1, 20000 Merkezefendi/ Denizli, Türkiye. e-mail: resadbeyoglu@gmail.com Phone: +905360584611

ORCID: 0000-0001-7321-5131

**To cited:** Beyoğlu R, Arslan RS, Seyit M, Özen M. Diagnostic Value of Ultrasonographic Septation in the Differentiation of Scrotal Hematocele and Hydrocele: A Single-Center, Retrospective Study. Acta Med. Alanya 2024;8(2): 93-98 doi: 10.30565/medalanya.1537200

## Introduction

Patients suffering from scrotal trauma generally complain of pain, nausea, vomiting, fainting, and swelling in the scrotum. On physical examination, significant tenderness, swelling, redness, and ecchymosis may be observed [1]. The most important evaluation method for patients with scrotal region trauma is US/Doppler evaluation in the supine position. In the ultrasonographic evaluation of a normal adult, the testicles are homogeneously echogenic, and their dimensions are around 5cm x 3cm x 2cm [2]. As a result of this examination, we can obtain clearer information about the pathological condition of the scrotal region, but sometimes the distinction between some scrotal pathological conditions, such as hematocele and hydrocele, may require experience and expertise.

While normally there is 0.5–1 ml of fluid between the testicle and these membranes to ensure the lubrication of the testicle, in hydrocele, this amount of fluid can reach 100–200 ml and sometimes much more [3]. Although hydrocele is the most common cause of scrotal swelling, occurring in 1 in every 10 children and 1 in every 100 adults, it is often considered a benign condition [4]. On the other hand, hematocele can develop secondary to trauma and cause serious consequences [1,4]. Fluid or blood may accumulate in the tunica vaginalis of the scrotum due to trauma and accidents such as kicking the testicle, falling, or riding a bicycle for a long time. Since the fluid will resorb on its own, it should not be drained unless necessary [5]. There is no need for urgent surgery in small hematoceles and hematomas as long as the tunica albuginea is intact. Sometimes, if the hematocele is large and tense enough to impair testicular blood flow, drainage may be necessary as it can cause compartment syndrome and thus ischemia of the testicle [2-4]. It is extremely important to detect testicular rupture, which can rarely develop after trauma, at an early stage. The rate of testicular salvage with operations performed in the first 72 hours is 90% [5,6]. Additionally, attention should be paid to child abuse. In this context, hematocele is a very important finding, as it can be a sign of serious pathologies.

The most valuable diagnostic method to distinguish

hematocele from hydrocele is Doppler/ultrasound. In fact, to date, except for a few individual cases, no study has been found to distinguish these two important pathological conditions radiologically. According to our emergency department (ED) experience, we were able to observe that septation findings were detected more frequently among the ultrasonographic findings of hematocele cases compared to hydrocele cases. Based on this hypothesis, this study aims to make an ultrasonographic distinction between hematocele and hydrocele based on a simple finding (septation) that every physician can recognize.

## Patients and Method

This study was carried out between November 15, 2022, and January 15, 2024, in the emergency department (ED) of Denizli Servergazi State Hospital treating approximately 200,000 ED patients annually. Patients who applied to the ED with complaints of scrotal pain, swelling, and redness were divided into two groups to find out the duration of ultrasonographic septations and to determine whether this formation occurs in acute situations or not:

Group 1: Patients whose symptoms develop due to trauma (those with a history of trauma in the last 4 weeks).

Group 2: Patients whose symptoms develop spontaneously.

After obtaining written consent forms, detailed medical histories were taken, and clinical examinations were performed for all patients included in the study. Then, scrotal US/Doppler was applied on all patients by an emergency medicine specialist with US/Doppler training using a GE LOGIQ 7 Ultrasound machine with 4C-M12L-9L probe. All patients were evaluated for all possible scrotal pathologies, and necessary intervention and treatment procedures were applied to cases in which pathological conditions such as epididymitis-orchitis, testicular torsion, etc. were detected by US/Doppler. For the definitive diagnosis and treatment of each patient with scrotal pathology, consultation was requested from the urology and radiology departments, and thus definitive diagnoses were made clinically and radiologically by a radiologist and a urologist.

Patients during their stay in the ED were given detailed information about the procedure, their safety was ensured, and preparations were made for all kinds of emergencies.

Criteria for inclusion in the study:

- Patients over 18 years old who were admitted to the ED with complaints of scrotal pain, swelling, and redness.

Exclusion criteria:

- Patients with disease in the scrotal area (e.g., testicular tumors).
- Patients with a history of scrotal area surgery
- Patients under 18 years of age
- Patients who did not agree to participate in the study

**Statistics and analysis**

In the analysis of the collected data, descriptive statistics (number, percentage, mean, and standard deviation), the Kolmogorov-Smirnov analysis method for the suitability of a normal distribution, the t-test for the analysis of parametric binary variables, the Mann-Whitney U test for non-parametric ones, the analysis of variance for the analysis of more than two parametric variables, and the Kruskal-Wallis test were used for non-parametric ones. In statistical analysis,  $p < 0.05$  will be considered significant, and the data were analyzed using the SPSS-22 (Statistical Package for Social Sciences) program.

**Results**

During the period of the study, a total of 68 patients were admitted to the ED with scrotal trauma, pain, swelling, and redness. These patients were given detailed information about our study while the necessary interventions were being performed. While 61 of the 68 patients admitted to the ED agreed to participate in the study and signed the consent form, 7 patients were not included in the study because they did not give written consent. The median age of the patients included in the study is 34(19-68), and the average age is 37.7 ±13.9. In terms of presenting complaints, 36 of 61 patients (59%) presented with scrotal trauma

and 25 (41%) with non-traumatic complaints. US/ Doppler was performed on all 61 patients included in the study (Figure 1). According to US/Doppler results, the most common causes of scrotal pain, swelling, and redness were epididymo-orchitis and varicocele, while the least common causes were orchitis and Mid. ureteral stone, respectively [13 (21.3%), 12 (19.7%), 1 (1.6%) and 1 (1.6%)] (Table 1). Hematocele was detected in 8 (22.2%) and hydrocele was detected in 1 (2.8%) of 36 patients with a history of trauma, while neither hematocele nor hydrocele was detected in 27 (75%) (Table 2). While septation was detected in 6 of 8 patients (75%), no septation was detected in 2 (25%) patients (Figure 2). According to this distribution, septation findings were detected more in patients with hematocele, and the difference was found to be statistically significant ( $p = 0.013$ ). On the other hand, no signs of septation were detected in any of the 28 patients who presented due to scrotal trauma and had no signs of hematocele. (Table 2).

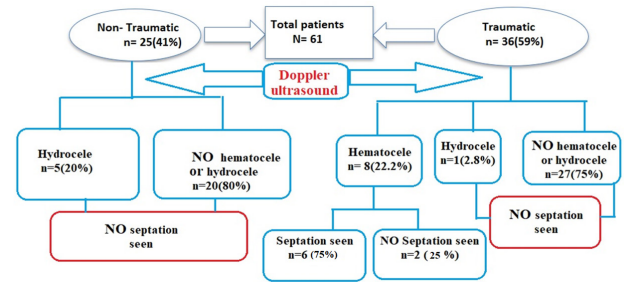


Figure 1. Algorithmic distribution of patients participating in the study.

Table 1. Doppler/US results of the patients included in the study.

Doppler findings	Traumatic group n	Non-traumatic group n	Total n(%)
Testicular torsion	9	2	11(18)
Epididymitis	2	5	7(11.5)
Orchitis	0	1	1(1.6)
Epididymo-orchitis	9	4	13(21.3)
Varicocele	5	7	12(19.7)
Hematocele	8	0	8(13.1)
Hydrocele	1	5	6(9.8)
Strangulated inguinal hernias	2	0	2(3.3)
Mid. ureteral stone	0	1	1(1.6)
Total	36	25	61(100.0)

When the patients with a history of scrotal trauma were categorized according to duration, no signs

of septation were detected in 12 patients who had acute or scrotal trauma within 1 week, while signs of septation were detected in 6 of 24 patients (25%) with a history of scrotal trauma 1-4 weeks ago. The difference between both groups in terms of trauma history was statistically significant ( $p = 0.043$ ) (Table 3).

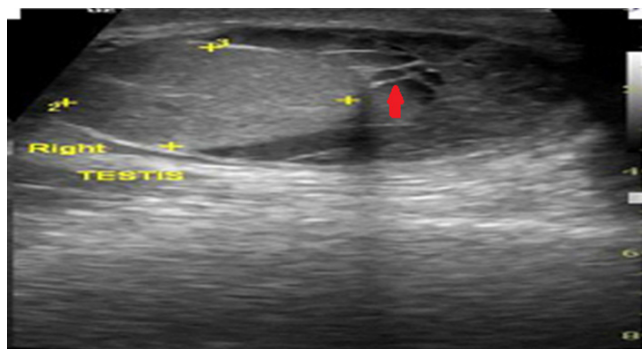


Figure 2. This US image is belong to 21-year-old patient who had a history of blunt trauma 18 days ago. A moderate-grade septal hydrocele with echo in the right testicle (red arrow).

On the other hand, while hydrocele was detected in 5 of 25 non-traumatic patients (20%), neither hematocele nor hydrocele were detected in the remaining 20 patients, and no signs of septation were observed in any patient in this group.

Table 2. The relationship between Doppler/US findings and septation.

Doppler/US findings	Non-traumatic group	Traumatic group	$P^*$	Septation (+)	Septation (-)	$P^*$
Hematocele	0	8	0.115	6	2	0.013
Hydrocele	5	1		0	6	
No hematocele or hydrocele	20	27		0	47	
Total	25	36		6	55	

\* Pearson Chi-square was used.

Table 3. The relationship between the presence of septation and trauma time.

Septation status	≤ 1 week	> 1 week	$p^*$
Septation seen	0	6	0.043
No septation seen	12	18	
Total	12	24	

\* Pearson Chi-square was used.

## Discussion

Hydrocele is the most common non-traumatic cause of scrotal swelling, affecting 1 in every 10 children and 1 in every 100 adults [7,8]. In adult

men and older people, hydrocele may occur due to reasons such as trauma to the scrotum, inflammatory diseases of the testicles and their appendages, testicular tumors, varicocele surgeries, and after radiotherapy. Unilateral hydrocele occurs in 70% of kidney transplant patients. Testicular torsion (sudden rotation of the testicular around itself) can cause reactive hydrocele in 20% of patients and may mask testicular torsion that requires urgent intervention [9]. On the other hand, hematocele, which occurs when blood accumulates between the tunica vaginalis leaves, is common after blunt trauma [10,11]. Large hematoceles (increasing the volume of the affected testicle > 3 times) can cause compression of the blood vessels, mimicking torsion [11,12]. In this case, urgent surgery may be required to ensure testicular perfusion. Unlike a hydrocele, a hematocele has increased echogenicity, and septa can often be seen within it [13]. It should be remembered that if the hematocele is large, it will be difficult for the US to detect tunica albuginea rupture [14].

In patients who presented to the ED with complaints of acute scrotal pain, scrotal redness, or swelling, the most common diagnoses were epididymo-orchitis and testicular torsion, while the least common diagnoses were orchitis and mid-ureteral stones. In a review article by Velasquez et al., they reported that the most common infective cause of acute scrotal pain is epididymitis and epididymo-orchitis, while the most common ischemic cause is testicular torsion. These results are parallel to the study titled "Acute scrotal pain" conducted by Burgher et al. and are also compatible with our study [10,15].

In this study, according to the US results of 36 traumatized patients, hematocele or hydrocele was not detected in 27 patients (75%), while hematocele was detected in 8 patients (22.2%) and hydrocele was detected in 1 patient (2.8%). None of the individuals with pathological diseases other than hydrocele and hematocele had septation. Conversely, in 6 out of 8 patients (75%) who developed hematocele, septation findings were found; in 2 patients (25%), no septation was found. This difference was statistically significant ( $p=0.013$ ). In a study by Cunningham, three patients who had scrotal swelling for 2 days, a year, and many years, respectively, were shown



to eventually develop hematocele, although their clinical history and physical findings were atypical [16]. All of these lesions showed an essentially anechoic mass crossed by thick, irregular septa. It has also been observed that the size and number of septations in an acute case decrease within 10 days. In a case report published by Bickle et al., it was emphasized that hematocele was associated with increased echolocation and separation [17]. These results are parallel to the results of the recently published study by Sood et al. Sood et al.'s study titled "Post-traumatic ruptured scrotal collection: pyocele or hematocele?" In the study, it was stated that hematocele was associated with increased echogenicity and septation [18].

On the other hand, Symeonidis et al. In a case report they published, a young patient who presented with a complaint of long-term swelling in the scrotal region was observed to have a thick and irregular septation along with a complex hydrocele in the left hemiscrotum on US, and it was determined during surgery that the assumed "complex hydrocele" was actually a multicystic testicular tumor [19].

Although no significant case-based study has been found explaining the relationship between hematocele and hydrocele and ultrasonographic septation findings, the results of the above-mentioned studies and case reports seem to be compatible with the results of our study. According to the results of our study, while no signs of septation were detected in hydrocele cases, septation was observed in most (n = 6) hematocele cases (n = 8). It was observed that all cases with septation findings had a history of trauma at least 1 week ago, and it was not detected in patients with a history of acute trauma or trauma within 1 week. A statistically significant difference was detected between septation formation and hematocele formation history (p = 0.043). It is thought that the sign of septation may be seen, especially in chronic hematocele and complicated hydrocele (hematocele and pyocele) findings [20]. In a study conducted by Patil et al., it was observed that septation findings were seen in chronic and complicated hydrocele cases, as well as being detected more frequently in hematocele cases [21]. These results are also compatible with the results obtained in our study. When the

fluid accumulated in the scrotum contains high amounts of protein or cholesterol, hydrocele becomes complex, and septation symptoms begin to develop. Thus, ultrasonographically, separation and loculations may occur in cases of hematocele or complex hydrocele.

**Limitations:** Since most of the patients did not have a previous scrotal US, the results obtained could not be compared with previous results. Therefore, it has made it difficult to determine whether the detected pathological events are acute or not. On the other hand, since this study was conducted in the ED, patients could not be called for control. As a result, it was unable to gather data regarding the progression of scrotal pathological diseases.

**Conclusions:** When septation is seen on the US of a patient who presents to the ED with scrotal pain, swelling, or ecchymosis, hematocele must first be ruled out. If septation is observed, it should be considered that hematocele is not an acute event. In other words, the presence of septation is not useful in acute trauma for distinguishing hematocele from hydrocele, but it may be useful in distinguishing chronic hematocele from hydrocele. We think that this finding can be easily recognized by emergency physicians who do not have advanced training in the US.

**Conflict of Interest:** The authors declare no conflict of interest related to this article.

**Funding sources:** The authors declare that this study has received no financial support.

**Ethics Committee Approval:** In this study, national and international ethical rules are observed. Pamukkale University Faculty of Medicine Ethics Committee was approved for the study (21.11.2022-E.289517).

**ORCID and Author contribution:** **R.B. (0000-0001-7321-5131):** Concept and Design, Data Collection, Interpretation of Results, Literature Search, Writing, Critical Review. Final Approval, **R.B. (0000-0001-7321-5131):** Data Collection, Literature Search, Writing. Editing **R.B. (0000-0001-7321-5131):** Concept and Design, Data Collection, Critical Review. Final Approval **R.B. (0000-0001-7321-5131), R.S.A. (0000-0002-**

**3139-9531), M.S. ( 0000-0002-8324-9471) and M.Ö. (0000-0001-6653-3756):** Data Collection, Interpretation Literature Search, Critical Review. Final Approval

**Peer-review:** Externally peer reviewed.

#### REFERENCES

- Liu, L. Chapter 1 - Applied Anatomy of the Scrotum and Its Contents. In *Scroscopic Surgery*; Yang, J., Ed.; Academic Press, 2019; pp 1–8. <https://doi.org/10.1016/B978-0-12-815008-5.00001-7>.
- Kühn AL, Scortegagna E, Nowitzki KM, Kim YH. Ultrasonography of the scrotum in adults. *Ultrasonography*. 2016;35(3):180-97. doi: 10.14366/usg.15075.
- Buckley JC, McAninch JW. Use of ultrasonography for the diagnosis of testicular injuries in blunt scrotal trauma. *J Urol*. 2006;175(1):175-8. doi:10.1016/S0022-5347(05)00048-0.
- Prajapati DK, Rampal K, Prajapati JM. Review of diagnosis and management of scrotal trauma with a case report. *Int J Med Res Prof*. 2016;2(3):197-200. doi: 10.21276/ijmp.2016.2.3.043.
- Monga M, Hellstrom WJ. Testicular Trauma. *Adolesc Med*. 1996 Feb;7(1):141-148. PMID: 10359963.
- Prajapati DK, Rampal K, Prajapati JM. Review of diagnosis and management of scrotal trauma with a case report. *Int J Med Res Prof*. 2016;2(3):197-200. doi: 10.21276/ijmp.2016.2.3.043.
- Lundström KJ, Söderström L, Jernow H, Stattin P, Nordin P. Epidemiology of hydrocele and spermatocele; incidence, treatment and complications. *Scand J Urol*. 2019 Apr-Jun;53(2-3):134-138. doi: 10.1080/21681805.2019.1600582.
- Beard JH, Ohene-Yeboah M, devries CR, Schechter WP. Hernia and Hydrocele. In: Debas HT, Donkor P, Gawande A, Jamison DT, Kruk ME, Mock CN, editors. *Essential Surgery: Disease Control Priorities, Third Edition (Volume 1)*. Washington (DC): The International Bank for Reconstruction and Development / The World Bank; 2015 Apr 2. Chapter 9. PMID: 26741001.
- Dagur G, Gandhi J, Suh Y, Weissbart S, Sheynkin YR, Smith NL, Joshi G, Khan SA. Calcifying Hydroceles of the Pelvis and Groin : An Overview of Etiology Secondary Complications, Evaluation, and Management . *Curr Urol*. 2017 Apr; 10(1):1-14. Doi: 10.1159/000447145.
- Velasquez J, Boniface MP, Mohseni M. Acute Scrotum Pain. 2023 May 8. In: *StatPearls [Internet]*. Treasure Island (FL): StatPearls Publishing; 2024 Jan-. PMID: 29262236.
- Bhatt S, Dogra VS. Role of US in testicular and scrotal trauma. *Radiographics*. 2008;28(6):1617-29. doi: 10.1148/rg.286085507.
- Tiguert R, Harb JF, Hurley PM, Gomes De Oliveira J, Castillo-Frontera RJ, Triest JA, et al. Management of shotgun injuries to the pelvis and lower genitourinary system. *Urology*. 2000;55(2):193-7. doi: 10.1016/s0090-4295(99)00384-2.
- Howe AS, Vasudevan V, Kongnyuy M, Rychik K, Thomas LA, Matuskova M, et al. Degree of twisting and duration of symptoms are prognostic factors of testis salvage during episodes of testicular torsion. *Transl Androl Urol*. 2017;6(6):1159-66. doi: 10.21037/tau.2017.09.10.
- Patil V, Shetty SM, Das S. Common and Uncommon Presentation of Fluid within the Scrotal Spaces. *Ultrasound Int Open*. 2015 Nov;1(2):E34-40. doi: 10.1055/s-0035-1555919.
- Burgher SW. Acute scrotal pain. *Emerg Med Clin North Am*. 1998 Nov;16(4):781-809, vi. doi: 10.1016/s0733-8627(05)70033-x.
- Cunningham JJ. Sonographic findings in clinically unsuspected acute and chronic scrotal hematoceles. *AJR Am J Roentgenol*. 1983 Apr;140(4):749-52. doi: 10.2214/ajr.140.4.749.
- Bickle I, El-Feky M, Weerakkody Y. Scrotal hematocele. *Radiopaedia.org* (Accessed on 18 Jan 2024). doi.org/10.53347/rfID-26153.
- Sood A, Mishra GV, Khandelwal S, Saboo K, Suryadevara M. Post-traumatic Ruptured Scrotal Collection: Pyocele or Hematocele? *Cureus*. 2023 Sep 13;15(9):e45198. doi: 10.7759/cureus.45198.
- Symeonidis EN, Sountoulides P, Asouhidou I, Gkekac C, Tsifountoudis I, Tsantila I, Symeonidis A, Georgiadis C, Malioris A, Papathanasiou M. Be cautious of "complex hydrocele" on ultrasound in young men. *Arch Ital Urol Androl*. 2020 Apr 7;92(1):61-63. doi: 10.4081/aiua.2020.1.61.
- Ying-Bei Chen, Chapter 244 - Hydrocele, Editor(s): Ming Zhou, George J. Netto, Jonathan I. Epstein, *Uropathology (Second Edition)*, Elsevier, 2023, Pages 541-542, ISBN 9780323653954, <https://doi.org/10.1016/B978-0-323-65395-4.00253-0>
- Patil V, Shetty SM, Das S. Common and Uncommon Presentation of Fluid within the Scrotal Spaces. *Ultrasound Int Open*. 2015 Nov;1(2):E34-40. doi: 10.1055/s-0035-1555919.