

## ASSESSMENT OF STAFNE BONE DEFECTS PREVALENCE AND CHARACTERISTICS BY USING CONE BEAM COMPUTED TOMOGRAPHY: A RETROSPECTIVE STUDY

*Konik Işınlı Bilgisayarlı Tomografi Kullanarak Stafne Kemik Kavitelerinin Prevalansının ve Özelliklerinin Araştırılması: Retrospektif bir Çalışma*

Kemal Özgür DEMİRALP<sup>1</sup>, Seval BAYRAK<sup>2</sup>, Emine Şebnem KURŞUN ÇAKMAK<sup>1</sup>

<sup>1</sup>Türkiye Public Hospitals Agency, Ministry of Health, ANKARA, TÜRKİYE

<sup>2</sup>Abant İzzet Baysal University, Dentistry Faculty, Dentomaxillofacial Radiology Department, BOLU, TÜRKİYE

### ABSTRACT

### ÖZ

**Objective:** Stafne bone defects (SBDs) are asymptomatic radiolucent cavities usually located between mandibular angle and the third molar, below the inferior alveolar canal and above the basis of the mandible. The aim of this retrospective study is to estimate the frequency, age and sex distribution and types of SBDs from Cone Beam Computed Tomography (CBCT) images of 169 subjects.

**Material and Methods:** CBCT images between the years 2014 and 2016 were obtained in Bolu İzzet Baysal University, Dentistry Faculty by using I-CAT 3D Imaging System from 169 subjects and analysed by one observer by utilizing axial, sagittal, cross-sectional, panoramic images and 3D reconstructions.

**Results:** Results of this study showed that SBDs frequency was 3.5% with the mean age of 51. Detected SBDs patients were all male. All cases were asymptomatic and unilateral.

**Conclusion:** Although the radiological appearance of the SBDs is usually pathognomonic, in indeterminate cases 3 dimensional examination as CBCT is recommended.

**Keywords:** Stafne bone defect, cone beam computed tomography, mandible

**Amaç:** Stafne Kemik Kaviteleri (SKK) asemptomatik radyolüsent boşluklar olup genellikle mandibuler açı ve üçüncü molar arasında, inferior alveolar kanal altında ve mandibula korpusu üzerinde konumlanmaktadır. Bu retrospektif çalışmanın amacı 169 adet hastadan elde edilmiş Konik Işınlı Bilgisayarlı Tomografi (KIBT) görüntülerinde SKK sıklığını, yaş ve cinsiyet dağılımını ve tipini tespit etmektir.

**Gereç ve Yöntemler:** Bolu İzzet Baysal Üniversitesi Dış Hekimliği Fakültesine 2014 ile 2016 yılları arasında başvuran ve 3 boyutlu görüntüleme sistemi I-CAT cihazı ile elde edilen 169 hastanın KIBT görüntüleri, bir gözlemci tarafından aksiyal, sagittal, krossseksiyonel, panoramik ve 3 boyutlu rekonstrüksiyonlar kullanılarak değerlendirilmiştir.

**Bulgular:** Bu çalışmanın sonuçları SKK frekansının %3.5 olduğunu ve ortalama yaşın 51 olduğunu göstermiştir. Tespit edilen SKK hastalarının hepsi erkek olup, tüm hastalar asemptomatik ve SKK tek taraflıdır.

**Sonuç:** SKK radyolojik görünümü genellikle patognomik olmasına rağmen şüpheli durumlarda KIBT gibi 3 boyutlu inceleme tavsiye edilmektedir.

**Anahtar Kelimeler:** Stafne kemik kavitesi, konik ışınlı bilgisayarlı tomografi, mandibula



Correspondence / Yazışma Adresi:

Türkiye Kamu Hastaneleri Kurumu, Nasuh Akar Mah, Ziyabey Cad, 1407.Sokak, Balgat, ANKARA, TÜRKİYE

Phone: +90 312 7051680

Received / Geliş Tarihi: 13.06.2017

Dr. Emine Şebnem KURŞUN ÇAKMAK

E-mail: sebnemkursun@yahoo.com.tr

Accepted / Kabul Tarihi: 04.12.2017

## INTRODUCTION

Stafne bone defects (SBDs) were first described in 1942 by Edward Stafne who reported 35 cases. Stafne defined these entities as asymptomatic radiolucent cavities located between mandibular angle and the third molar, below the inferior alveolar canal and above the basis of the mandible (1). The anterior variant of the lesion in the canine-premolar region was first reported in 1957 by Richard and Ziskind (2). Anterior located SBDs are prone to be confused with other pathological entities like benign odontogenic inflammatory or cystic lesions and need to be identified with advanced imaging techniques or surgical procedures (3). Because the patients are usually asymptomatic, SBDs are incidentally detected on routine dental examination (4). Despite many existing theories, etiology and pathophysiology of SBDs are not fully understood up to now although most authors concur that this cavity might be related with the pressure exerted by the submandibular gland on the lingual mandibular plate (4). The submandibular gland is directly related with the posterior type of SBDs. The sublingual gland could be related with the anterior type while the parotid gland is related with the two types of SBDs of the mandibular ramus (5).

A sialography can be useful to visualize the content of the cavity but has several disadvantages like the pain produced by the injection of the contrast agent and the exposure to ionizing radiation (6). Although MRI is suggested as an essential tool for SBDs imaging because of its superior soft tissue discrimination, it has also disadvantages including cost, discomfort to patients and possible image distortion (7).

CBCT is being widely used in recent years with high resolution and low-dose radiation in dentomaxillofacial radiology. Several authors have recently described CBCT procedure as a non-invasive, easy method for diagnosis of SBDs (8).

The aim of this retrospective study is to estimate the frequency, age and sex distribution and type of SBDs.

## MATERIALS AND METHODS

CBCT images were obtained using I-CAT 3D Imaging System (Imaging Sciences International, Hatfield, PA, USA) with following parameters: 5 mA, 120 kVp, 16 X 9-12 FOV and voxel size of 0.3 mm. The study population comprised of 169 subjects (70 male and 99 female) who had undergone CBCT imaging for different purposes in Abant İzzet Baysal University, Dentistry Faculty from 2014 to 2016. The mean age of the subjects was 25.4 years (age range 9-70 years). Images with efficient image quality and suitable field of view for detection of SBDs were included in the study. Exclusion criterias were the presence of cyst, tumors or previous surgical operations due to these pathologies. The images were examined by one investigator with an experience of 10 years in Dentomaxillofacial Radiology. Axial, sagittal, cross-sectional and panoramic images were reconstructed for all mandibles and 3D reconstructions were used if necessary.

After CBCT examination, if SBDs is detected, the sample was evaluated according to age, gender, size, location and the type of defect as the following criteria (9) (Table 1).

Table 1: Radiographical classification of Stafne Bone Defects

Type	Description
I	The inferior border of the mandible is involved.
II	The lesion is situated above the inferior border of the mandible but below the mandibular canal.
III	Deviation of the mandibular canal is suspected
IV	The radiolucency is located in the anterior portion of the mandible

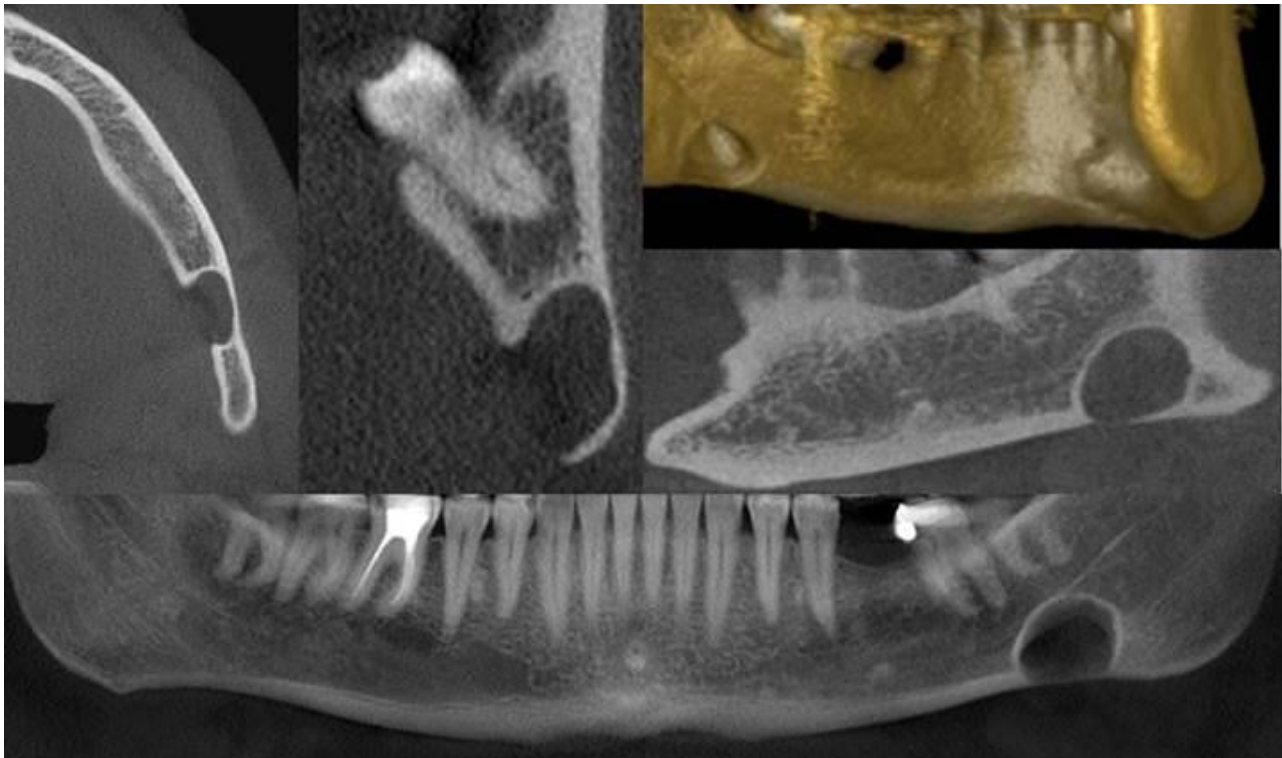
## RESULTS

Six cases of SBDs were detected among 169 cases of CBCT images (3.5 %). All defects were asymptomatic and unilateral. Half of the SBDs was in the right side and the other half was in the left side. Detected SBDs

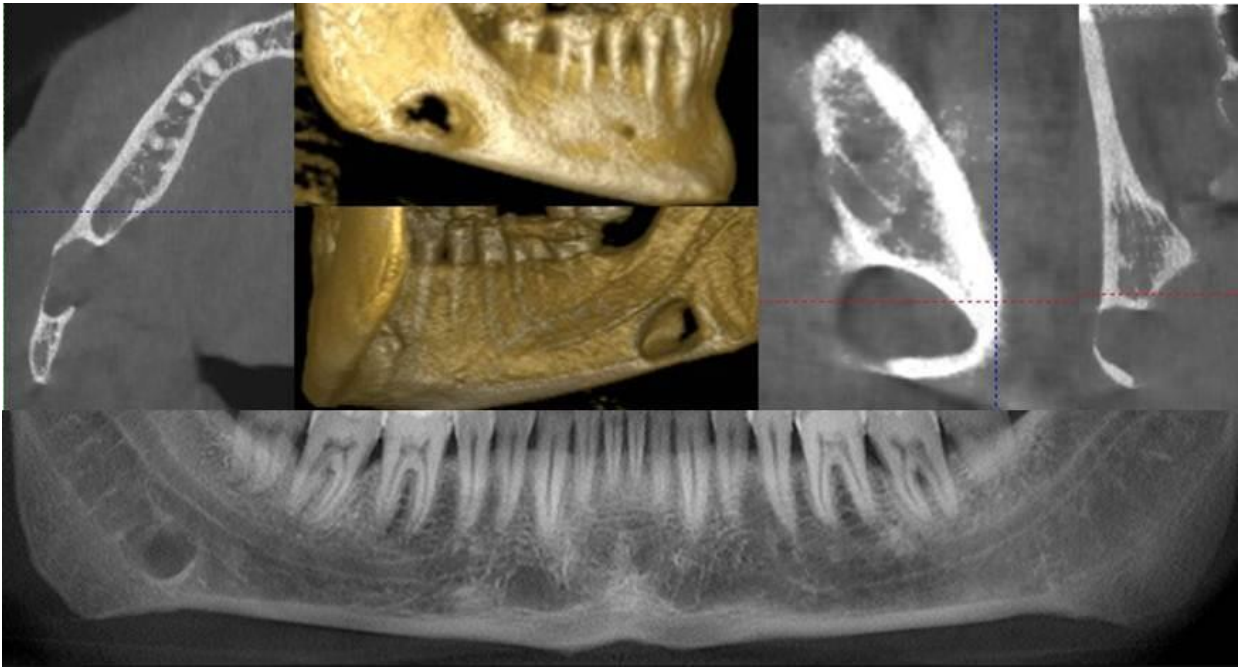
patients were all male. Their mean age was 51 with a range of 38 to 70. According to classification, 4 cases were Type I (Figure 1), one case was Type II (Figure 2) and one case was Type III (Figure 3). In the anterior region of the mandible, no SBDs was detected (Table 2).

**Table 2:** Clinical data of 6 cases of Stafne Bone Defects

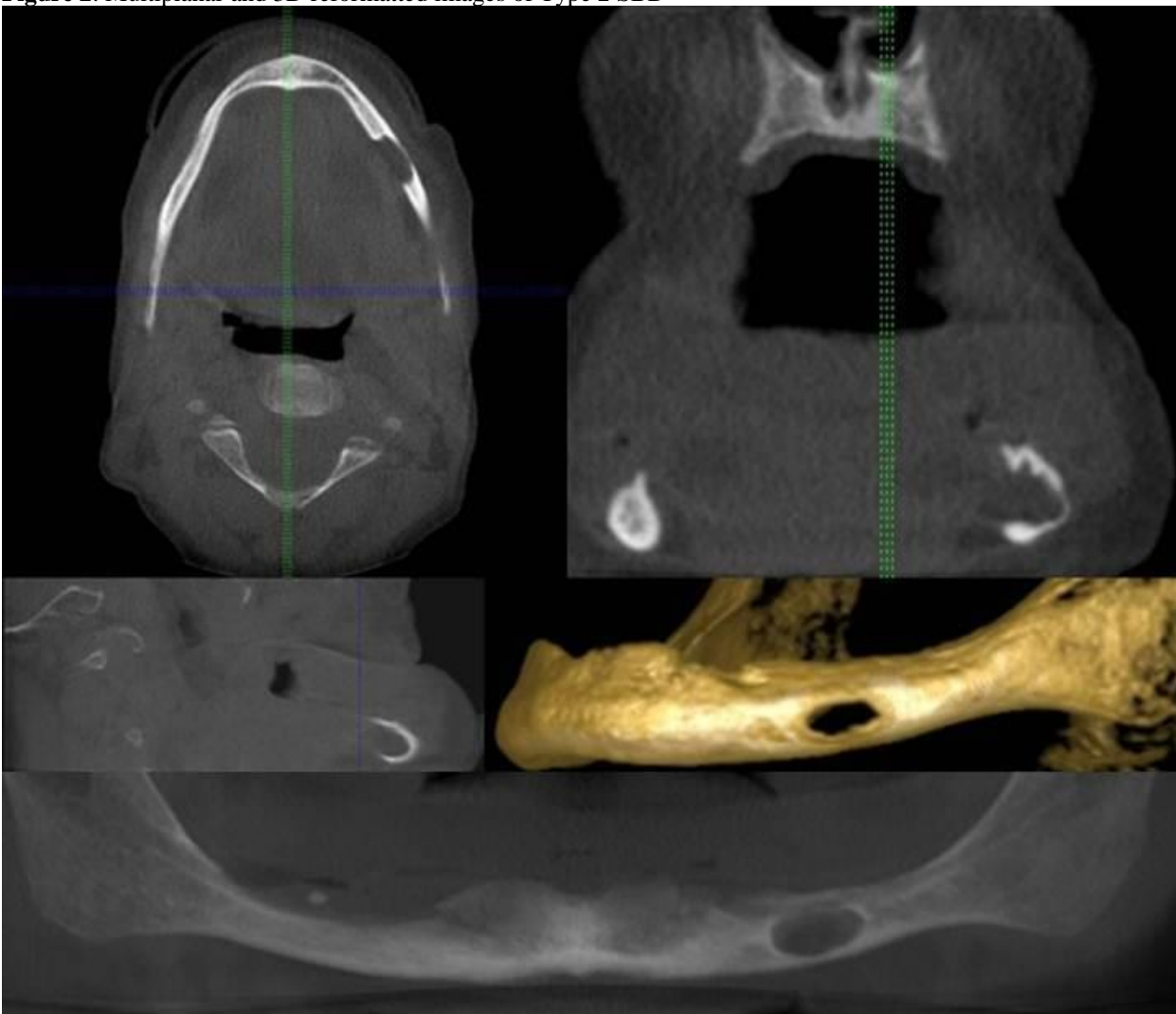
No	Age	Gender	Size (Mm)	Location	Type
1	38	Male	14x11	Left	I
2	53	Male	9 X 9	Right	I
3	62	Male	18 X 10	Right	II
4	41	Male	7 X 5	Left	I
5	70	Male	14 X 9	Left	III
6	43	Male	22 X 9	Right	I



**Figure 1.** Multiplanar and 3D reformatted images of Type 1 SBD



**Figure 2.** Multiplanar and 3D reformatted images of Type 2 SBD



**Figure 3.** Multiplanar and 3D reformatted images of Type 3 SBD.

## DISCUSSION

The typical presentation of a SBDs is an elliptical, homogeneous radiotransparency, with a well-defined border located below the inferior alveolar canal, often involving the lower border of the mandible (4).

SBDs are mostly detected in male population in their fifth or seventh decade of life with a prevalence between 0.1% and 6.06 % (10-12). This rather large difference in prevalence between studies has been attributed to the difficulty in identifying these entities radiographically. Higher incidences were reported in dried mandibles and may be the result of the authors being able to detect the defect in the dried specimens more readily than on a radiograph of the jaw of a living patients (8, 11, 13). The prevalence of SBDs is estimated as 3.5% and is in accordance with the published studies. The mean age of 12 SBDs patients reported by Minowa (14) was 57 years. In the study of Philipsen et al. (11) SBDs ratio was 6 times higher for male patients than for female patients. Quesada-Gomez et al. (5) also reported 11 cases of SBD, of which 8 were detected in males. In the current study, all of the patients who have SBDs were male and the average age was 51, in line with the previous studies. Anterior variant of SBDs is reported to be rare with a prevalence of 0.1% and 0.48% (3). Type 4 SBDs was not observed in the current research.

SBDs are generally found incidentally on routine radiographic examinations (7). All the SBDs patients were referred to our clinic after routine dental examination and suspected in orthopantomography examination. Several authors examined SBDs with various imaging modalities. In the present investigation, CBCT was used for its higher resolution when compared to medical CT and also CBCT scans produce reconstructed multiplanar images that allow the clinician to assess the area of interest three-dimensionally. Studies showed that CBCT proved to be as accurate as routinely used multislice CT in revealing

the SBDs. Katz et al. (12) reported that CBCT is a perfect diagnostic tool as it provides detailed information for SBDs estimation.

In conclusion, SBDs diagnosis is coincidental because of its asymptomatic nature and nonprogressive characteristic. Radiological examination is the most suitable approach for its routine follow-ups. In cases whose radiological appearance is not pathognomonic, 3 dimensional radiological examination such as CBCT is an effective diagnostic tool for the diagnosis of these entities.

## REFERENCES

1. Stafne EC. Bone cavities situated near the angle of the mandibula. *J Am Dent Ass.* 1942; 29: 1969-72.
2. Richard EL, Ziskind J. Aberrant salivary gland tissue in the mandible. *Oral Surg Oral Med Oral Pathol.* 1957; 10: 1086-90.
3. Ozaki H, Ishikawa S, Kitabatake K, Yusa K, Tachibana H, Iino M. A case of simultaneous anterior and posterior Stafne bone defects. *Case Reports in Dentistry.* 2015; <http://dx.doi.org/10.1155/2015/983956>.
4. Herranz-Aparicio J, Figueiredo R, Gay-Escoda C. Stafne's bone cavity: an unusual case with involvement of the buccal and lingual mandibular plates. *J Clin Exp Dent.* 2014; 6(1): 96-9.
5. Quesada-Gomez C, Valmaseda-Castellon E, Berini-Aytes L, Gay-Escoda C. Stafne bone cavity: a retrospective study of 11 cases. *Med Oral Patol Oral Cir Bucal.* 2006; 11: 277-280.
6. Branstetter BF, Weissman JL, Kaplan SB. Imaging of a Stafne bone cavity: what MR adds and why a new name is needed. *AJNR.* 1999; 20: 587-9.
7. Li B, Long X, Cheng Y, Wang S. Cone beam CT sialography of Stafne bone cavity. *Dentomaxillofac Radiol.* 2011; 40: 519-23.

8. Slasky BS, Bar-Ziv J. Lingual mandibular bony defects: CT in the buccolingual plane. *J Comput Assist Tomogr.* 1996; 20: 439-44.
9. Shigematsu H, Suzuki S, Osuga T, Okumura Y, Fujita K. A radiographical classification of Stafne's bone cavity. *Oral Radiology.* 1993; 9 (2): 13-8.
10. Taysi M, Ozden C, Cankaya B, Olgac V, Yıldırım S. Stafne bone defect in the anterior mandible. *Dentomaxillofac Radiol.* 2014; 43: 20140075. doi: 10.1259/dmfr.20140075.
11. Philipsen HP, Takata T, Reichart PA, Sato S, Suei Y. Lingual and buccal mandibular bone depressions: A review based on 583 cases from a world-wide literature survey, including 69 new cases from Japan. *Dentomaxillofac Radiol.* 2002; 31: 281-90.
12. Katz J, Chaushu G, Rotstein I. Stafne's bone cavity in the anterior mandible: a possible diagnostic challenge. *J Endod.* 2001; 27: 304-7.
13. Grellner TJ, Frost DE, Brannon RB. Lingual mandibular bone defect: report of three cases. *J Oral Maxillofac Surg.* 1990; 48: 288-96.
14. Minowa K, Inoue N, Sawamura T, Matsuda A, Totsuka Y, Nakamura M. Evaluation of static bone cavities with CT and MRI. *Dentomaxillofac Radiol.* 2003; 32: 2-7.