

Comparison of short-term radiographic outcomes of medial parapatellar, mini-midvastus, and subvastus surgical approaches in fast-track total knee arthroplasty

Fast-track total diz artroplastisinde medial parapatellar, mini-midvastus ve subvastus cerrahi yaklaşımlarının kısa dönem radyografik sonuçlarının karşılaştırılması

Hakan Zora, Harun Reşit Güngör, Gökhan Bayrak

Posted date:16.02.2024

Acceptance date:03.04.2024

Abstract

Purpose: Due to the difficulties in accessing the knee joint, correct prosthesis placement is of great importance during the implementation of total knee arthroplasty (TKA). This study aimed to compare short-term radiographic X-ray outcomes in patients who underwent fast-track TKA with medial parapatellar (MPP), mini-midvastus (mMV), or subvastus (SV) surgical approaches.

Materials and methods: Between 2018 and 2020, 93 patients operated with MPP, mMV, and SV surgical approaches and who had complete data of radiographic outcomes before and sixth-week postoperative were retrospectively analyzed and patients divided into three groups: MPP (n=31), mMV (n=31), and SV (n=31). The alignments of preoperative and sixth-week postoperative X-ray images of the surgical approaches were measured. The operative time of fast-track TKA implementation with MPP, mMV, and SV surgical approaches was recorded.

Results: The MPP group had a higher preoperative lateral distal femoral angle than the mMV group and a higher preoperative lateral proximal femoral angle than the SV group ($p=0.018$ and $p=0.027$, respectively). The mMV group had a higher postoperative proximal medial tibial angle than the SV group ($p=0.011$). In the postoperative sixth week, the MPP and mMV groups had a lower posterior tibial slope angle than the SV group ($p=0.001$). The MPP approach had significantly shorter operative time than the mMV and SV approaches ($p=0.001$).

Conclusion: The outcomes indicate that MPP, mMV, and SV surgical approaches are preferable and feasible in obtaining a satisfactory prosthesis alignment during fast-track TKA. The MPP approach may be preferable because of its shorter operative time and potential advantage in minimizing surgical complication risks.

Keywords: Total knee replacement, surgical approaches, radiography, operative time.

Zora H, Gungor HR, Bayrak G. Comparison of short-term radiographic outcomes of medial parapatellar, mini-midvastus, and subvastus surgical approaches in fast-track total knee arthroplasty. Pam Med J 2024;17:522-532.

Öz

Amaç: Diz eklemine erişimdeki zorluklar nedeniyle, total diz artroplastisi (TDA) uygulaması sırasında doğru protez yerleşimi büyük önem taşımaktadır. Bu çalışmanın amacı medial parapatellar (MPP), mini-midvastus (mMV) veya subvastus (SV) cerrahi yaklaşımları ile fast-track TDA uygulanan hastalarda kısa dönem radyografik X-ray sonuçlarını karşılaştırmaktır.

Gereç ve yöntem: 2018-2020 yılları arasında MPP, mMV ve SV cerrahi yaklaşımlarıyla opere edilen ve cerrahi öncesi ve cerrahi sonrası altıncı hafta radyografik sonuçları eksiksiz olan 93 hastanın verisi retrospektif olarak analiz edildi ve hastalar üç gruba ayrıldı: MPP (n=31), mMV (n=31) ve SV (n=31). Cerrahi yaklaşımların cerrahi öncesi ve cerrahi sonrası altıncı hafta X-ray görüntülerine ait dizilimleri ölçüldü. MPP, mMV ve SV cerrahi yaklaşımlarıyla uygulanan fast-track TDA'nın operasyon süresi kaydedildi.

Bulgular: MPP grubu, cerrahi öncesinde mMV grubuna göre daha yüksek lateral distal femoral açığa ve SV grubuna göre daha yüksek lateral proksimal femoral açığa sahipti (sırasıyla $p=0,018$ ve $p=0,027$). mMV grubunun cerrahi sonrası proksimal medial tibial açısı SV grubuna göre daha yüksekti ($p=0,011$). Cerrahi sonrası altıncı haftada, MPP ve mMV grupları SV grubuna göre daha düşük posterior tibial eğim açısına sahipti ($p=0,001$). MPP yaklaşımı, mMV ve SV yaklaşımlarına göre anlamlı derecede daha kısa operasyon süresine sahipti ($p=0,001$).

Sonuç: Sonuçlar, MPP, mMV ve SV cerrahi yaklaşımlarının fast-track TDA sırasında memnun edici bir protez dizilimi elde etmede tercih edilebilir ve uygulanabilir olduğuna işaret etmektedir. MPP yaklaşımı daha kısa operasyon süresi ve cerrahi komplikasyon risklerini en aza indirmedeki potansiyel avantajı nedeniyle tercih edilebilir.

Hakan Zora, Private Medicabil Hospital, Department of Orthopedics and Traumatology, Bursa, Türkiye, e-mail: mdhakanzora@gmail.com (<https://orcid.org/0000-0002-5323-8245>)

Harun Reşit Güngör, Prof. Pamukkale University, Faculty of Medicine, Department of Orthopedics and Traumatology, Kınıklı Campus, University Street, 20070, Pamukkale, Denizli, Türkiye, e-mail: hrgungor@gmail.com (<https://orcid.org/0000-0002-0721-0890>)

Gökhan Bayrak, Muş Alparslan University, Physiotherapy and Rehabilitation Department of Faculty of Health Sciences, Muş, Türkiye, e-mail: gokhan2803@gmail.com (<https://orcid.org/0000-0001-9224-996X>) (Corresponding Author)

Anahtar kelimeler: Total diz artroplastisi, cerrahi yaklaşımlar, radyografi, operasyon süresi.

Zora H, Güngör HR, Bayrak G. Fast-track total diz artroplastisinde medial parapatellar, mini-midvastus ve subvastus cerrahi yaklaşımlarının kısa dönem radyografik sonuçlarının karşılaştırılması. Pam Tıp Derg 2024;17:522-532.

Introduction

Total knee arthroplasty (TKA) is a standard surgical treatment for end-stage knee osteoarthritis (KOA) patients [1]. Fast-track procedures in the surgery of TKA include preoperatively informing the patients regarding nutrition and optimal pain control, transition to early postoperative oral nutrition, early mobilization, early rehabilitation, and early discharging [2]. Recent evidence indicates that fast-track surgical procedures support early rehabilitation and recovery after TKA [3]. The outcomes of TKA, as determined mainly by patient-reported scales, are entirely acceptable; however, certain factors may affect patient satisfaction and comfort [4]. Notably, correct alignment of the prosthesis implemented in the knee radiologically and planarly in the desired angle ranges significantly affects knee kinematics, knee range of motion, knee functional scores, and implant failure rates [5].

Various surgical approaches have been utilized for satisfactory postoperative recovery, shortest hospital stay, best joint alignment, and minimal risk of complications [6]. These approaches employed in TKA surgery are the traditional medial parapatellar (MPP), mini-midvastus (mMV), and subvastus (SV) surgical approaches [6, 7]. The MPP surgical approach, generally used in TKA surgery, is considered a simple and standardized approach that visually provides a broad and desired joint opening during surgery [6]. However, the MPP approach is known to carry functional risks, including decreased knee extensor strength, decreased blood supply to the patellar region, and proximal deep venous thrombosis in the short and long term [8-10]. The mMV and SV approaches, considered minimally invasive surgical methods, have advantages and disadvantages [11]. The mMV surgical approach has demonstrated proficiency in preserving the quadriceps tendon and achieving precise component alignment, even in knees with substantial deformities [8, 11, 12]. However, the drawback of the mMV surgical approach is that it requires some splitting of

the extensor mechanism [9]. The SV approach is one of the alternative methods used in TKA surgery. The SV approach is an anatomical surgery that protects the medial retinaculum and vastus medialis obliquus muscle and minimizes blood loss [9, 11]. Nevertheless, the SV surgical approach could potentially induce adverse effects on the positioning of prostheses and the alignment of extremities due to constraints within the limited operative space [13].

There is ongoing debate about the preference for MPP or mMV approaches in TKA surgery [8]. In previous studies, MPP and SV surgical approaches [8, 14-16] and mMV and SV surgical approaches [17] were compared regarding radiographic appearance and alignment, and the results were found to be acceptably equivalent. In addition, in a prior investigation comparing the radiologic Hip-knee-ankle (HKA) angle across the MPP, mMV, and SV surgical approaches in TKA, the researchers noted that all three approaches yielded comparable radiologic outcomes [6]. There are concerns that minimally invasive surgical approaches may make achieving correct component alignment during TKA challenging due to difficulty accessing the knee joint during the operation [17]. Although the mMV and SV approaches offer clinical advantages over the traditional MPP approach, such as shorter hospitalization and lower pain levels [6, 9], it is unclear whether they create an advantage or disadvantage regarding component placement and alignment due to the difficulty of arthrotomy [9]. Therefore, this study aimed to compare short-term radiographic X-ray outcomes in patients who underwent fast-track TKA with MPP, mMV, and SV surgical approaches.

Materials and methods

This retrospective study was performed with patients who underwent fast-track TKA surgery with MPP, mMV, and SV surgical approaches for KOA in the Orthopedics and Traumatology Department of Pamukkale University Hospital between January 2018 and January 2020. A written informed consent was obtained from

all patients. Ethics Committee approval was obtained from the author's affiliated ethics committee. The study was conducted under the principles of the Declaration of Helsinki.

Study design

Preoperative and postoperative sixth-week radiographic X-ray outcomes of the patients operated with MPP, mMV, or SV surgical approaches for KOA were retrospectively analyzed. In addition, the duration of fast-track TKA implementation completed with MPP, mMV, or SV surgical approaches was recorded.

Participants

Patients who were admitted to the orthopedics and traumatology clinic of Pamukkale University Hospital for KOA and underwent fast-track TKA with MPP, mMV, or SV surgical approaches and met the inclusion and exclusion criteria were included in the study. A G*power (Version 3.1) analysis program determined the study's sample size. According to the priori power analysis of the F-tests of one-way analysis of variance (ANOVA) test based on a tibial posterior slope (SLOP) angle of the reference study [14], the priori calculated sample size was at least 87 patients (29 per group) with a power of 90% ($d=0.39$), a level of .05. A total of 93 patients with complete demographic and preoperative and sixth-week postoperative radiographic data were divided into three groups: MPP ($n=31$), mMV ($n=31$), and SV groups ($n=31$). Inclusion criteria were as follows: being between 50-75 years of age, undergoing fast-track TKA surgery with MPP, mMV, or SV surgical approaches due to KOA, having radiologic images before fast-track TKA surgery, and at six weeks after surgery, and understanding the verbal and written information given. Exclusion criteria were as follows: revision TKA surgery, American Society of Anesthesiologists (ASA) classification score >3 , rheumatoid arthritis, history of previous surgery on the affected extremity, neurologic disease which causes functional disability, psychiatric disorder, uncorrectable hearing or visual impairment, use of hearing aids, and morbid obesity (body mass index >40 kg/m²).

Surgical approaches

The same institutional fast-track surgical protocol was utilized on all patients as previously described [18]. All patients underwent using

MPP, mMV or SV surgical approaches by the same surgical team using the same brand of ligament-cutting fixated TKA (NexGen Legacy® Posterior Stabilized (LPS-Flex) Knee-Fixed Bearing, Zimmer-Biomet Inc., Warsaw, Indiana 46580, USA), the same brand of polymethyl methacrylic acid (PMMA) and bone cement (Oliga- G21 srl-Vias. Pertini,8-41039 San Possodonio (MO)-Italy) and surgical approaches were performed by the same surgical team. All operations were performed without the use of a tourniquet.

During the fast-track TKA surgery, the silicone supports were placed in all patients to give the knee a 90-degree flexion position. In the MPP surgical approach, the vastus medialis muscle was separated proximally with an incision in the quadriceps tendon. Then, the incision was continued along the medial retinaculum and patellar tendon, and the incision was terminated approximately 0.5-1 cm medial to the tibial tuberosity [19, 20]. In the mMV surgical approach, the incision in the arthrotomy stage following the skin incision was applied parallel to the muscle fibers of the vastus medialis. After the attachment site of the vastus medialis muscle to the patella was exposed, it was separated as a split parallel to the muscle fibers. In the arthrotomy stage, the incision was made at the superomedial corner of the patella, then medial to the patellar tendon, and terminated medial to the tibial tuberosity [20]. In the SV surgical approach, after the skin incision, the vastus medialis muscle was advanced along the inferior border of the muscle with blunt dissection proximally without touching the patella and quadriceps tendon attachment sites. Distally, it was terminated medial to the patellar tendon and medial to the tibial tuberosity [21].

Outcome evaluations

The demographic (age, body mass index, and gender) and clinical (dominant extremity, affected extremity, and infection) characteristics of the patients were recorded. Radiographic X-ray outcomes of the knee were measured on the radiographic images of all patients preoperative and six weeks after fast-track TKA surgery. For the alignment analysis, preoperative and postoperative orthorhontgenograms of all patients were obtained using the Materialise OrthoView (OrthoView 7th version, Materialise HQ, Technologelaan 15 3001 Leuven, Belgium)

program. HKA angle, femorotibial (FT) angle, lateral distal femoral (LDF) angle, lateral proximal femoral (LPF) angle, proximal medial tibial (PMT) angle, lateral distal tibial (LDT)

angle, and SLOP angles were measured and recorded by a single-blinded physician using appropriate measurement techniques on the radiographic X-ray images (Figure 1).

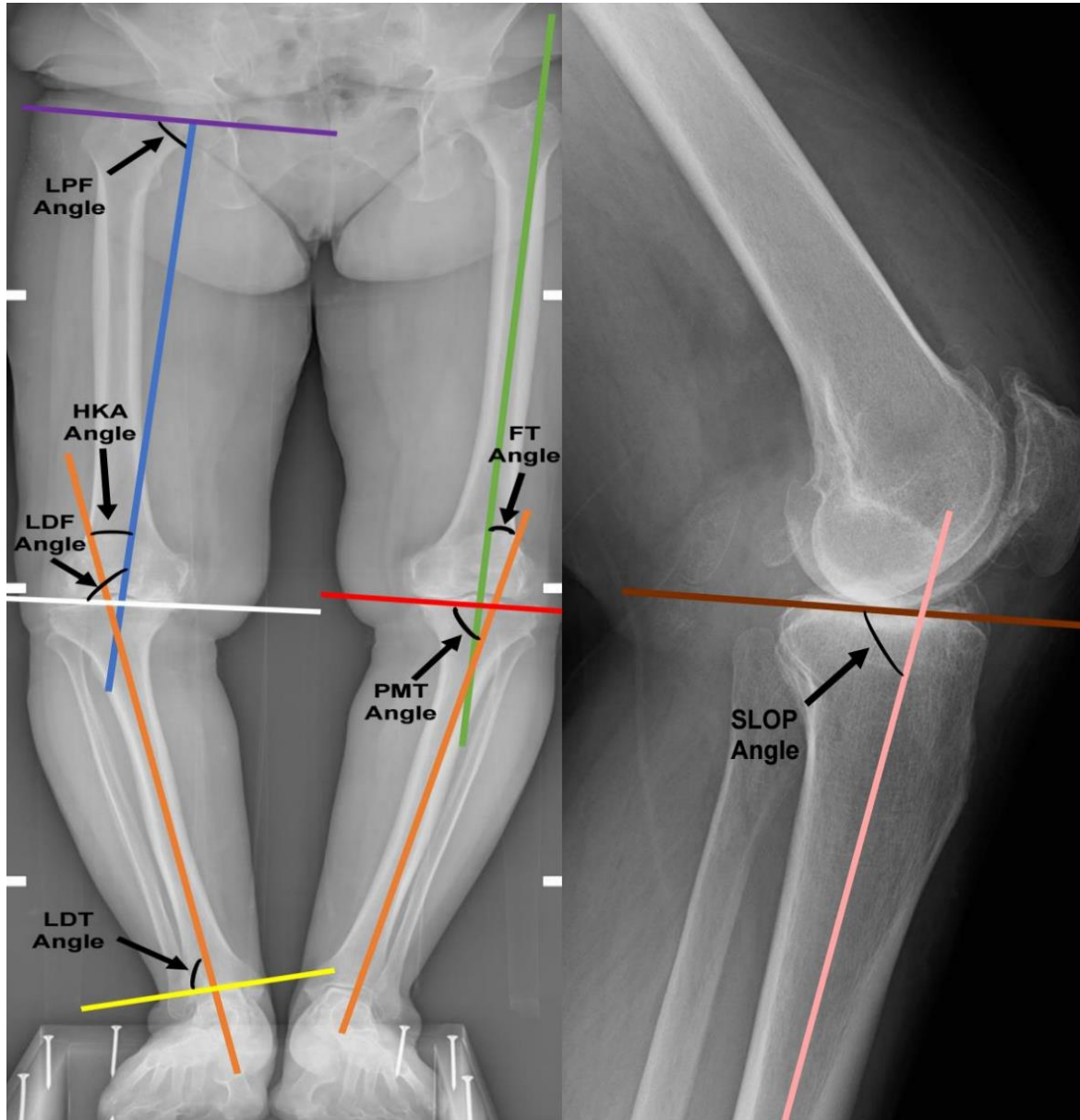


Figure 1. Radiological angles utilized in the study

Orange Line: Mechanical and anatomical axis of the tibia
 Blue Line: Mechanical axis of the femur
 Green Line: Anatomical axis of the femur
 White Line: The distal transcondylar line of the femur
 Red Line: Proximal transtibial line of the tibia
 Yellow Line: Tibia distal joint line
 HKA: Hip-knee-ankle, LDF: Lateral distal femoral, LPF: Lateral proximal femoral
 PMT: Proximal medial tibial, LDT: Lateral distal tibial, SLOP: Tibial posterior slope, FT: Femorotibial

Hip-knee-ankle angle: To measure the HKA angle, the femur and the tibia's mechanical axis are drawn as two lines. The angle between these two lines is the HKA angle, defined as a deviation from 180 degrees [22].

Femorotibial angle: FT angle is formed by the intersection of the femur's anatomical axis and the tibia's anatomical axis [23, 24].

Lateral distal femoral angle: The LDF angle is the lateral angle between the distal transcondylar line and the mechanical axis of the femur [23].

Lateral proximal femoral angle: The LPF angle represents the angle formed laterally by the line from the midpoint of the femoral head to the apex of the greater trochanter and the mechanical axis of the femur [25-27].

Proximal medial tibial angle: The PMT angle is the medial angle between the transtibial axis and the mechanical axis of the tibia. The PMT angle was determined by assessing the angle formed between a line drawn from the most proximal medial to proximal lateral points of the tibial component and another line connecting the center of the tibial medullary canal [28, 29].

Lateral distal tibial angle: The LDT angle is the lateral angle between the tibia's anatomical axis and the tibia's distal articular surface line [27, 30].

Tibial posterior slope angle: The SLOP is defined as the angle formed on lateral axis radiographs between a line perpendicular to the long axis of the tibia and a line parallel to the medial tibial plateau [14, 31].

Statistical analysis

The SPSS (Version 25; IBM, Armonk, NY, USA) program was used to evaluate the data obtained statistically. Data were presented as mean and standard deviation. The ANOVA test was used to compare the angular variables of the groups when normal distribution data were provided; Kruskal Wallis tests were used when non-normal distribution data were provided. In intragroup comparisons, the paired samples *t*-test was used when normal distribution data

were provided, and the Wilcoxon test was used when non-normal distribution data were provided. The statistical significance level was accepted as $p < 0.05$.

Results

The comparisons of the groups, including demographic characteristics and operative time of the surgery, are shown in Table 1. The groups showed similar results in age and body mass index ($p > 0.05$). Regarding surgical time, the MPP surgical approach (65.48 minutes) was significantly shorter than the mMV (77.12 minutes) and SV (77.67 minutes) surgical approaches ($p < 0.05$). In the MPP group, 90.3% of patients were female, and 9.7% were male; in the mMV group, 96.8% of patients were female, and 3.2% were male; and in the SV group, 87.1% of patients were female, and 12.9% were male. The right extremity was dominant in 93.5% of patients in the MPP group, 96.8% in the mMV group, and 96.8% in the SV group. In the MPP group, 51.6% of patients were operated on the right and 48.4% on the left extremity; in the mMV group, 48.4% of patients were operated on the right and 51.6% on the left extremity; and in the SV group, 41.9% of patients were operated on the right and 58.1% on the left extremity. No infection was observed in any patients (Table 1).

The MPP group had a significantly higher preoperative LDF angle than the mMV group and a significantly higher preoperative LPF angle than the SV group ($p = 0.018$ and $p = 0.027$, respectively). The mMV group had a significantly higher postoperative PMT angle than the SV group ($p = 0.011$). The MPP and mMV groups had significantly lower postoperative SLOP angles than the SV group ($p = 0.001$) (Table 2).

The MPP group significantly improved the HKA, FT, LDF, LPF, PMT, and SLOP angles between the preoperative and the sixth week after surgery ($p < 0.05$). The mMV group significantly improved the HKA, FT, LDF, LPF, PMT, and SLOP angles between the preoperative and the sixth week after surgery ($p = 0.001$). In the SV group, significant improvement was detected in the HKA, FT, LPF, PMT, and SLOP angles between the preoperative and the sixth week after surgery ($p = 0.001$) (Table 2).

Table 1. The demographic and clinical characteristics of the groups and the comparison of the operative time of the surgical approaches

Variables	¹ MPP (n=31) Mean (SD)		² mMV (n=31) Mean (SD)		³ SV (n=31) Mean (SD)		p
	n	%	n	%	n	%	
Age (year)	63.51 (6.90)		64.80 (7.45)		64.25 (6.86)		0.772
Body mass index (kg/m ²)	30.01 (2.82)		28.57 (3.22)		29.69 (4.27)		0.243
The operative time (minutes)	65.48 (2.61)		77.12 (3.31)		77.67 (3.86)		0.001 * ^{1-2, 1-3}
Gender							
Female	28	90.3	30	96.8	27	87.1	0.384
Male	3	9.7	1	3.2	4	12.9	
Dominant extremity							
Right	29	93.5	30	96.8	30	96.8	0.770
Left	2	6.5	1	3.2	1	3.2	
Operated extremity							
Right	16	51.6	15	48.4	13	41.9	0.739
Left	15	48.4	16	51.1	18	58.1	
Infection							
Yes	0	0	0	0	0	0	-
No	31	100	31	100	31	100	

¹MPP: Medial parapatellar approach, ²mMV: mini-midvastus approach, ³SV: Subvastus approach, SD: Standard deviation
kg: kilogram, m: meter
p: Value of the independent group comparison analysis

Table 2. Comparison of the alignments of preoperative and sixth-week postoperative X-ray images of the surgical approaches

Variables (angle)	¹ MPP (n=31) Mean (SD)	² mMV (n=31) Mean (SD)	³ SV (n=31) Mean (SD)	<i>p</i> ¹
HKA				
Preoperative	-13.9 (5.25)	-12.66 (4.38)	-12.21 (5.25)	0.387
Sixth-week after TKA	-1.34 (3.53)	-1.23 (2.94)	-1.10 (3.04)	0.956
<i>p</i> ²	0.001*	0.001*	0.001*	
FT				
Preoperative	-7.45 (4.07)	-6.23 (3.79)	-6.83 (4.96)	0.541
Sixth-week after TKA	3.75 (2.57)	4.37 (2.50)	3.62 (3.08)	0.107
<i>p</i> ²	0.001*	0.001*	0.001*	
LDF				
Preoperative	91.61 (2.60)	89.81 (2.97)	90.18 (2.12)	0.018*¹⁻²
Sixth-week after TKA	90.58 (1.74)	90.32 (2.36)	90.60 (1.82)	0.834
<i>p</i> ²	0.019*	0.234	0.335	
LPF				
Preoperative	88.66 (2.70)	90.47 (3.17)	91.10 (4.73)	0.027*¹⁻³
Sixth-week after TKA	90.36 (3.33)	90.59 (3.24)	90.90 (3.90)	0.836
<i>p</i> ²	0.001*	0.001*	0.001*	
PMT				
Preoperative	85.46 (3.62)	84.74 (3.85)	83.99 (3.47)	0.290
Sixth-week after TKA	89.36 (1.51)	90.38 (2.01)	89.03 (1.83)	0.011*²⁻³
<i>p</i> ²	0.001*	0.001*	0.001*	
LDT				
Preoperative	88.11 (3.98)	87.81 (3.68)	88.23 (5.02)	0.923
Sixth-week after TKA	87.85 (4.27)	88.45 (3.24)	87.34 (4.02)	0.527
<i>p</i> ²	0.684	0.373	0.203	
SLOP				
Preoperative	7.99 (3.57)	9.21 (2.64)	8.49 (1.60)	0.216
Sixth-week after TKA	6.11 (1.39)	5.54 (1.27)	7.35 (0.27)	0.001*^{1-3, 2-3}
<i>p</i> ²	0.006*	0.001*	0.001*	

¹MPP: Medial parapatellar approach, ²mMV: mini-midvastus approach, ³SV: Subvastus approach, SD: Standard Deviation, FT: Femorotibial HKA: Hip-knee-ankle, LDF: Lateral distal femoral, LPF: Lateral proximal femoral, PMT: Proximal medial tibial, LDTA: Lateral distal tibial

SLOP: Tibial posterior slope

*p*¹: Value of the independent group comparison analysis

*p*²: Value of the dependent group comparison analysis

Discussion

This study aimed to compare the radiographic results related to the knee joint in patients who underwent fast-track TKA with MPP, mMV, and SV surgical approaches. The study's results determined that fast-track TKA performed with medial parapatellar and mini-midvastus surgical approaches provided a better prosthesis alignment in the posterior tibial inclination angle after surgery. The mMV group displayed

a remarkably higher postoperative PMT angle than the SV group. Moreover, the observed improvements in the normative values in the HKA, FT, LDF, LFTA, PMT, and LDT angular measurements postoperatively across all groups highlight the efficacy of the MPP, mMV, and SV surgical interventions in prosthesis alignment. Regarding operative time, fast-track TKA surgery performed with the MPP surgical approach was completed in a shorter surgery time than mMV and SV surgical approaches.

In recent years, many studies have examined the results of minimally invasive surgical approaches, mMV and SV, compared with the traditional MPP surgical approach [9]. However, the results of these surgical approaches regarding prosthesis alignment after TKA are limited [15, 32]. An earlier investigation reported that the normative values of the HKA angle ranged between 1 and 1.5 degrees [33]. Another study focusing on TKA utilizing the MPP or lateral approaches revealed a mean postoperative HKA angle of 0.976 [5]. Our study observed that all three surgical approaches provided prosthesis alignment in the normative value range between 1-1.5 degrees in patients who underwent fast-track TKA.

TKA aims to provide a normal prosthesis alignment, and the accepted normative range for the FT angle generally falls within approximately 5-7 degrees [24, 28]. Previous investigations utilizing the MPP surgical approach have reported an FT angle of 0.6 ± 3.3 degrees [34] and a mean FT angle of 4 degrees post-TKA surgery [35]. Comparative studies between the MPP and mMV surgical approaches have demonstrated similar postoperative FT angles of 6.1 and 6.5 degrees [35] and 6.6 and 6.4 degrees, respectively, with no significant intergroup differences observed [36]. Our study confirms these findings, revealing mean postoperative FT angles of 3.75 in the MPP group, 4.37 in the mMV group, and 3.62 in the SV group. These values align closely with established normative values and existing literature.

The normative values of LDF, LPF, and PMT angles were determined to be between 85-95 degrees [25, 29]. It is argued that the deviation of the LDF and PMT angles of approximately 5 degrees from 90 degrees after TKA is seriously discussed in terms of outcomes [37]. Similarly, in a previous study, LPF angle was 91.6 ± 0.1 degrees in patients after TKA [26]. In our study, the LDF, LPF, and PMT angles in the MPP, mMV, and SV groups were found to be in the range of 89.03-90.90 degrees, which is within the ranges recommended in the literature and compatible with other literature findings.

The distal tibial articular surface and the anatomical axis of the tibia form an LDT angle. The normative value of the LDT angle ranges between 86 and 92 degrees [25]. A previous study reported a mean LDT angle of 87.3

degrees in patients who underwent TKA with the MPP surgical approach [38]. In our study, all three surgical approaches had LDT angles in the range of 87.34-88.45 degrees, consistent with the normative values in the literature and previous literature findings.

Increasing the SLOP angle, which refers to the tibial slope, widens the already increased flexion deficit due to the incision of the posterior cruciate ligament and, if increased greatly, can result in a posteriorly displaced knee [31]. The normative SLOP values typically range from 0 to 7 degrees [14]. Previous studies examining the SLOP angle after TKA with the MPP surgical approach found SLOP angle values to vary between 7-8.1 degrees [39, 40]. SLOP angles after TKA with MPP and SV surgical approaches were 5.1 and 4.08 degrees, respectively [14]. Similarly, a previous study found that the SLOP angle was 5.3 ± 0.4 degrees in the ligament cutting group after TKA was performed with the MPP surgical approach [31]. Our study found that MPP and mMV surgical approaches (6.11 and 5.54 degrees, respectively) were significantly lower than the SV approach (7.35 degrees). Our results were found to be consistent with the results of previous studies in the literature.

The duration of surgery is one of the critical points in the TKA process. The existing literature shows that surgical operative time is longer in mMV and SV surgical approaches compared to conventional methods [32]. A prior investigation found that the MPP and SV surgical approaches demonstrated similar surgical durations of 80 and 75 minutes, respectively [16]. Regarding the operative time, it is reported that mMV and SV surgical approaches take an average of 18 minutes longer than the MPP surgical approach [32]. Patients who underwent TKA with the SV or MPP surgical approach discovered that the SV surgical approach had a longer surgical time of meanly 13 minutes [7] and more [41]. A previous meta-analysis showed that the mMV surgical approach had a significantly longer duration of surgery than the MPP surgical approach [11]. In our study, the duration of the MPP surgical approach was shorter (65.48 minutes) than the mMV (77.12 minutes) and SV (77.67 minutes) surgical approaches in accordance with the findings in the literature.

Prior investigations highlighted the complications associated with the MPP and

minimally invasive surgical approaches. The MPP surgical approach may bear potential complications such as patellar fracture and patellofemoral instability [8]. The quadriceps-sparing technique exhibited superficial and deep infections, peroneal nerve palsy, and supracondylar fractures attributable to the constrained visual field inherent to this approach [42]. Likewise, a previous study documented that minimally invasive surgical methodologies, such as the mMV and SV approaches, prolonged surgical duration and may be linked with potentially significant complications, including challenges related to the learning curve and mastering difficulties [6]. In the present study, none of these potential complications were encountered among fast-track TKA patients who underwent procedures utilizing the MPP, mMV, and SV surgical approaches, as stated in previous reports [20, 36]. In this study, we think that the routine preference of MPP, mMV, or SV surgical approach utilization in the clinical setting, the minimal learning effect of the experienced surgeon regarding surgical approaches, and the involvement of the same surgical team during surgical operations may be effective in preventing these potential complications.

Our study has several limitations. The first limitation is that we did not evaluate the knee range of motion at preoperative and postoperative week 6. The second limitation is that we should have made long-term radiologic X-ray outcome follow-ups. Lastly, the substantial predominance of female participants in our study (87.1-96.8%) may not accurately reflect the demographic composition of the normal patient distribution in TKA surgery, thereby constituting a limitation of our study.

In conclusion, in this study, which aimed to compare the radiographic results related to the knee joint in patients who underwent fast-track TKA with MPP, mMV, and SV surgical approaches, it was observed that all three approaches were within the radiographic angle ranges recommended by the literature and were compatible with the literature findings. The results obtained from our study indicate that MPP, mMV, and SV surgical approaches are feasible in fast-track TKA and help to obtain a satisfactory prosthesis alignment. The MPP surgical approach might

be deemed more suitable and preferable for achieving a shorter operative time, potentially conferring an advantage over the mMV and SV surgical approaches in minimizing surgical complications. In future surgical procedures, patients' postoperative clinical and functional status following MPP, mMV, and SV surgical approaches and their satisfaction with the chosen surgical technique will need to be specifically considered. In addition, further analyses with extended patient populations and long-term radiologic X-ray outcomes are needed.

Conflict of interest: No conflict of interest was declared by the authors.

References

1. Aljehani MS, Christensen JC, Snyder Mackler L, Crenshaw J, Brown A, Zeni JA Jr. Knee biomechanics and contralateral knee osteoarthritis progression after total knee arthroplasty. *Gait Posture* 2022;91:266-275. <https://doi.org/10.1016/j.gaitpost.2021.10.020>
2. Melnyk M, Casey RG, Black P, Koupparis AJ. Enhanced recovery after surgery (ERAS) protocols: time to change practice? *Can Urol Assoc J* 2011;5:342-348. <https://doi.org/10.5489/cuaj.11002>
3. Chen KK, Chan JJ, Zubizarreta NJ, Poeran J, Chen DD, Moucha CS. Enhanced recovery after surgery protocols in lower extremity joint arthroplasty: using observational data to identify the optimal combination of components. *J Arthroplasty* 2021;36:2722-2728. <https://doi.org/10.1016/j.arth.2021.03.003>
4. Shichman I, Ben Ari E, Sissman E, Oakley C, Schwarzkopf R. Effect of total knee arthroplasty on coronal alignment of the ankle joint. *J Arthroplasty* 2022;37:869-873. <https://doi.org/10.1016/j.arth.2022.01.059>
5. Hiranaka T, Miyazawa S, Furumatsu T, et al. Large flexion contracture angle predicts tight extension gap during navigational posterior stabilized-type total knee arthroplasty with the pre-cut technique: a retrospective study. *BMC Musculoskelet Disord* 2022;23:78(e1-8). <https://doi.org/10.1186/s12891-022-05035-z>
6. Bouché PA, Corsia S, Nizard R, Resche Rigon M. Comparative efficacy of the different surgical approaches in total knee arthroplasty: a systematic-review and Network Meta-Analysis. *J Arthroplasty* 2021;36:1187-1194.e1. <https://doi.org/10.1016/j.arth.2020.09.052>
7. Sukeik M, Sohail MZ, Hossain FS, AlShryda S, Powell J. Comparing the sub-vastus and medial parapatellar approaches in total knee arthroplasty: a meta-analysis of short-term outcomes. *Dr Sulaiman Al Habib Medical Journal* 2021;3:66-73. <https://doi.org/10.2991/dsahmj.k.210203.001>

8. Güler O, Gümüşsuyu G, Sofu H, Gökçen HB. Clinical and radiological outcomes of total knee arthroplasty performed with midvastus and medial parapatellar approaches in obese patients. *Adv Orthop* 2021;2021:5512930(e1-7). <https://doi.org/10.1155/2021/5512930>
9. Bonutti PM, Zywiell MG, Ulrich SD, Stroh DA, Seyler TM, Mont MA. A comparison of subvastus and midvastus approaches in minimally invasive total knee arthroplasty. *J Bone Joint Surg Am* 2010;92:575-582. <https://doi.org/10.2106/JBJS.I.00268>
10. Chin PL, Foo LSS, Yang KY, Yeo SJ, Lo NN. Randomized controlled trial comparing the radiologic outcomes of conventional and minimally invasive techniques for total knee arthroplasty. *J Arthroplasty* 2007;22:800-806. <https://doi.org/10.1016/j.arth.2006.10.009>
11. Liu HW, Gu WD, Xu NW, Sun JY. Surgical approaches in total knee arthroplasty: a meta-analysis comparing the midvastus and subvastus to the medial peripatellar approach. *J Arthroplasty* 2014;29:2298-2304. <https://doi.org/10.1016/j.arth.2013.10.023>
12. Liu HC, Kuo FC, Huang CC, Wang JW. Mini-midvastus total knee arthroplasty in patients with severe varus deformity. *Orthopedics* 2015;38:112-117. <https://doi.org/10.3928/01477447-20150204-58>
13. Wu Y, Zeng Y, Bao X, et al. Comparison of mini-subvastus approach versus medial parapatellar approach in primary total knee arthroplasty. *Int J Surg* 2018;57:15-21. <https://doi.org/10.1016/j.ijso.2018.07.007>
14. Biçer EK, Sözbilen MC, Aydoğdu S, Hakkı S. Influence of total knee arthroplasty approaches on component positioning. *Cukurova Med J* 2018;43:343-349. <https://doi.org/10.17826/cumj.341797>
15. Li Z, Cheng W, Sun L, et al. Mini-subvastus versus medial parapatellar approach for total knee arthroplasty: a prospective randomized controlled study. *Int Orthop* 2018;42:543-549. <https://doi.org/10.1007/s00264-017-3703-z>
16. Weinhardt C, Barisic M, Bergmann EG, Heller KD. Early results of subvastus versus medial parapatellar approach in primary total knee arthroplasty. *Arch Orthop Trauma Surg* 2004;124:401-403. <https://doi.org/10.1007/s00402-004-0692-3>
17. Masjudin T, Kamari Zh. A comparison between subvastus and midvastus approaches for staged bilateral total knee arthroplasty: a prospective, randomised study. *Malays Orthop J* 2012;6:31-36. <https://doi.org/10.5704/MOJ.1207.018>
18. Şavkın R, Büker N, Güngör HR. The effects of preoperative neuromuscular electrical stimulation on the postoperative quadriceps muscle strength and functional status in patients with fast-track total knee arthroplasty. *Acta Orthop Belg* 2021;87:735-744. <https://doi.org/10.52628/87.4.19>
19. Jeong SH, Schneider B, Pyne AS, Tishelman JC, Strickland SM. Patellofemoral arthroplasty surgical technique: lateral or medial parapatellar approach. *J Arthroplasty* 2020;35:2429-2434. <https://doi.org/10.1016/j.jy>
20. Katragadda BC, Kumar S, Suresh A, Kumar Vk. Midvastus versus medial parapatellar approach in simultaneous bilateral total knee arthroplasty. *J Arthroplasty* 2023;38:2301-2306. <https://doi.org/10.1016/j.arth.2023.05.043>
21. Scuderi GR, Tenholder M, Capeci C. Surgical approaches in mini-incision total knee arthroplasty. *Clin Orthop Relat Res* 2004;428:61-67. <https://doi.org/10.1097/01.blo.0000148574.79874.d0>
22. Ji HM, Han J, Jin DS, Seo H, Won YY. Kinetically aligned TKA can align knee joint line to horizontal. *Knee Surg Sports Traumatol Arthrosc* 2016;24:2436-2441. <https://doi.org/10.1007/s00167-016-3995-3>
23. Pornrattanamaneewong C, Ruangsombon P, Wingprawat K, Chareancholvanich K, Narkbunnam R. Accuracy of empirical distal femoral valgus cut angle of 4° to 6° in total knee arthroplasty: a randomized controlled trial. *Eur J Orthop Surg Traumatol* 2022;32:175-181. <https://doi.org/10.1007/s00590-021-02890-9>
24. Yang NH, Nayeb Hashemi H, Canavan PK, Vaziri A. Effect of frontal plane tibiofemoral angle on the stress and strain at the knee cartilage during the stance phase of gait. *J Orthop Res* 2010;28:1539-1547. <https://doi.org/10.1002/jor.21174>
25. Çakmak M, Özkan K. Alt ekstremitte deformite analizi (I). *TOTBID Dergisi* 2005;4:50-62.
26. Maderbacher G, Keshmiri A, Schaumburger J, et al. What is the optimal valgus pre-set for intramedullary femoral alignment rods in total knee arthroplasty? *Knee Surg Sports Traumatol Arthrosc* 2017;25:3480-3487. <https://doi.org/10.1007/s00167-016-4141-y>
27. Colyn W, Bruckers L, Scheys L, Truijen J, Smeets K, Bellemans J. Changes in coronal knee-alignment parameters during the osteoarthritis process in the varus knee. *J ISAKOS* 2023;8:68-73. <https://doi.org/10.1016/j.jisako.2022.12.002>
28. Sgroi M, Faschingbauer M, Reichel H, Kappe T. Can the frontal tibiofemoral alignment be assessed on anteroposterior knee radiographs? *J Orthop Traumatol* 2016;17:339-343. <https://doi.org/10.1007/s10195-016-0404-0>
29. Weber P, Gollwitzer H. Kinematic alignment in total knee arthroplasty. *Kinematisches Alignment in der Knieendoprothetik. Oper Orthop Traumatol* 2021;33:525-537. <https://doi.org/10.1007/s00064-021-00729-4>

30. Suardi C, Stimolo D, Zanna L, et al. Varus morphology and its surgical implication in osteoarthritic knee and total knee arthroplasty. *J Orthop Surg Res* 2022;17:299. <https://doi.org/10.1186/s13018-022-03184-4>
31. Oka S, Matsumoto T, Muratsu H, et al. The influence of the tibial slope on intra-operative soft tissue balance in cruciate-retaining and posterior-stabilized total knee arthroplasty. *Knee Surg Sports Traumatol Arthrosc* 2014;22:1812-1818. <https://doi.org/10.1007/s00167-013-2535-7>
32. Mora JP, Scuderi GR. Minimally invasive total knee arthroplasty: does surgical technique actually impact the outcome? *Orthop Clin North Am* 2020;51:303-315. <https://doi.org/10.1016/j.ocl.2020.02.009>
33. Sheehy L, Felson D, Zhang Y, et al. Does measurement of the anatomic axis consistently predict hip-knee-ankle angle (HKA) for knee alignment studies in osteoarthritis? analysis of long limb radiographs from the multicenter osteoarthritis (MOST) study. *Osteoarthritis Cartilage* 2011;19:58-64. <https://doi.org/10.1016/j.joca.2010.09.011>
34. Chun KC, Kweon SH, Nam DJ, Kang HT, Chun CH. Tibial tubercle osteotomy vs the extensile medial parapatellar approach in revision total knee arthroplasty: is tibial tubercle osteotomy a harmful approach? *J Arthroplasty* 2019;34:2999-3003. <https://doi.org/10.1016/j.arth.2019.07.015>
35. Liu H, Mei X, Zhang Z, Sun J. Mini-midvastus versus mini-medial parapatellar approach in simultaneous bilateral total knee arthroplasty with 24-month follow-up. *Acta Orthop Traumatol Turc* 2015;49:586-592. <https://doi.org/10.3944/AOTT.2015.15.0078>
36. Haas SB, Cook S, Beksac B. Minimally invasive total knee replacement through a mini midvastus approach: a comparative study. *Clin Orthop Relat Res* 2004;428:68-73. <https://doi.org/10.1097/01.blo.0000147649.82883.ca>
37. Almaawi AM, Hutt JRB, Masse V, Lavigne M, Vendittoli PA. The impact of mechanical and restricted kinematic alignment on knee anatomy in total knee arthroplasty. *J Arthroplasty* 2017;32:2133-2140. <https://doi.org/10.1016/j.arth.2017.02.028>
38. Gürsu S, Sofu H, Verdonk P, Şahin V. Effects of total knee arthroplasty on ankle alignment in patients with varus gonarthrosis: do we sacrifice ankle to the knee? *Knee Surg Sports Traumatol Arthrosc* 2016;24:2470-2475. <https://doi.org/10.1007/s00167-015-3883-2>
39. Kim YH, Choi Y, Kwon OR, Kim JS. Functional outcome and range of motion of high-flexion posterior cruciate-retaining and high-flexion posterior cruciate-substituting total knee prostheses. a prospective, randomized study. *J Bone Joint Surg Am* 2009;91:753-760. <https://doi.org/10.2106/JBJS.H.00805>
40. Catani F, Leardini A, Ensini A, et al. The stability of the cemented tibial component of total knee arthroplasty: posterior cruciate-retaining versus posterior-stabilized design. *J Arthroplasty* 2004;19:775-782. <https://doi.org/10.1016/j.arth.2004.01.013>
41. Yao Y, Kang P, Xue C, Jing J. A prospective randomized controlled study of total knee arthroplasty via mini-subvastus and conventional approach. *Chinese Journal of Reparative and Reconstructive Surgery* 2018;32:162-168. <https://doi.org/10.7507/1002-1892.201710075>
42. Kim YH, Kim JS, Kim DY. Clinical outcome and rate of complications after primary total knee replacement performed with quadriceps-sparing or standard arthrotomy. *J Bone Joint Surg Br* 2007;89:467-470. <https://doi.org/10.1302/0301-620X.89B4.18663>

Ethics committee approval: This study was approved by the Pamukkale University Faculty of Medicine Non-Interventional Clinical Research Ethics Committee (date: 08.03.2021, number: E-60116787-020-28632).

Authors' contributions to the article

H.R.G. constructed the main idea and hypothesis of the study. G.B. and H.Z. developed the theory and arranged/edited the material and method section. H.Z. made the measurements and drafted the data. G.B. has done the statistical analysis and evaluation of the data in the results section. The discussion section of the article was written by G.B., H.Z., and H.R.G. and G.B., H.Z., and H.R.G. reviewed, corrected, and approved. In addition, all authors discussed the entire study and approved the final version.