

Evaluation of infraorbital canal types and their relation with adjacent structures: A cone beam computed tomography study

 Aykağan Çukurluoğlu¹,  Zeynep Firdevs Sönmez¹

¹ Department of Oral and Maxillofacial Radiology, Erciyes University Faculty of Dentistry, Kayseri, Türkiye

Abstract

Aim: This study aims to analyze infraorbital canal (IOC) types in patients with cone beam computed tomography (CBCT) scans and to investigate the potential relationship between the IOC types and mucosal thickening, as well as adjacent structure variations such as Haller cells, sinus septa, middle turbinate pneumatization (MTP) and IOC types.

Methods: Bilateral evaluation of 197 CBCT records was conducted to assess mucosal thickening, Haller cells, sinus septa, middle turbinate pneumatization (MTP), and IOC types. IOC types were categorized into three classes based on their extent of protrusion into the maxillary sinus: type 1, entirely within the sinus roof; type 2, located below and adjacent to the sinus roof; and type 3, suspended from the sinus roof and descending into the sinus cavity.

Results: The distribution of IOC types was as follows: 67.5% for type 1, 22.6% for type 2, and 9.9% for type 3. No significant correlation was observed between IOC types and MTP, mucosal thickening, or the presence of Haller cells. However, a significant relationship was noted between Type 3 IOC and the presence of septa. The occurrence of septa in the maxillary sinus was 8.3% for type 1 IOCs, 13.5% for type 2 IOCs, and 43.6% for type 3 IOCs. ($p < 0.001$)

Conclusions: The protrusion of the IOC into the maxillary sinus is relatively uncommon but should not be overlooked. A significant relationship was detected between the presence of septa and the type 3 IOC. Examination of existing CBCT scans may offer valuable insights about IOC.

Keywords: *Infraorbital canal, maxillary sinus, cone beam computed tomography*

1. Introduction


The infraorbital canal (IOC) is located in the maxillary bone, anterior to the orbital floor. The IOC begins posteriorly as a continuation of the infraorbital groove and terminates at the infraorbital foramen. It includes the infraorbital branch of the maxillary nerve, the trigeminal nerve's second branch. Additionally, it includes the infraorbital artery and vein. The infraorbital nerve (ION) provides sensory innervation to the skin of the malar area between the lower eyelid and the upper lip, as well as to the upper incisor, canine, and associated gingiva via its superior alveolar branch^{1,2}.

Anesthesia of the ION may be required in various fields of study, including dentistry, otorhinolaryngology, and ophthalmology³. Additionally, during procedures such as rhinoplasty, endoscopic

sinus surgery, Caldwell-Luc surgery, and tumor removal surgeries involving the nasal cavity and maxillary sinus, the position of the IOC could be quite crucial. It could also be significant due to traumatic events such as orbital floor fractures and zygomaticomaxillary complex (ZMC) fractures. Iatrogenic ION damage could occur during the procedures or fractures mentioned above, regarding the anatomical position of the IOC^{1,4,5}.

Cone beam computed tomography (CBCT) gained popularity in dentistry since the early 2000s. While CBCT scans offer a lower radiation dose compared to traditional computed tomography scans, they also provide superior spatial resolution⁶. Common applications include dental implant procedures, orthognathic surgeries, and pathological lesions affecting the maxilla and mandible. CBCT scans taken for these purposes provide clear visualization of the paranasal sinus region and neighboring structures and are considered adequate for their evaluation^{7,8}. There are studies in the literature in which mucosal thickening and variations such as the presence of septa, the presence of Haller cells, and middle turbinate pneumatization (MTP) were successfully detected by CBCT^{9,10}.

It is crucial for clinicians performing ION anesthesia or surgical interventions in the area containing the IOC to possess knowledge about its anatomy, particularly its protrusion degree into the

Corresponding Author: Aykağan Çukurluoğlu, aykagann@gmail.com, Received: 10.05.2023, Accepted: 25.06.2024, Available Online Date: 30.06.2024 Cite this article as: Çukurluoğlu A, Sönmez ZF. Evaluation of infraorbital canal types and their relation with adjacent structures: A cone beam computed tomography study. *J Cukurova Anesth Surg.* 2024; 7(2): 119-23. <https://doi.org/10.36516/jocass.1481329> Copyright © 2024 This is an open access article distributed under the terms of the Creative Commons Attribution-Non-Commercial-No Derivatives License 4.0 (CC-BY-NC-ND), where it is permissible to download and share the work provided it is properly cited. The work cannot be changed in any way or used commercially without permission from the journal. 

maxillary sinus. This knowledge plays a pivotal role in preventing nerve damage, as nerves protruding into the maxillary sinus are more prone to injury.

The classifications suggested to determine the degree of protrusion of the IOC divide the IOC morphology into three categories; completely within the orbital floor, inferior to the orbital floor, or completely within the maxillary sinus¹. Studies in the literature have shown that the frequency of the IOC protruding into the maxillary sinus is not negligible and should not be overlooked^{1,4,5,11-14}. Some studies found significant relationships between maxillary sinus variations, such as the presence of Haller cells or septa, and IOC protrusion, but the relationship between sinus variations and protrusion has not been sufficiently elucidated^{4,11-13}.

The aim of this study is to analyze IOC protrusion types in patients with CBCT scans for dental reasons and to investigate the possible relationship between IOC protrusion and mucosal thickening of the maxillary sinus as well as sinonasal variations including Haller cells, sinus septa, and MTP.

2. Materials and methods

This retrospective study was conducted by analyzing the medical and radiological records from the oral and maxillofacial radiology department of the faculty of dentistry. Ethics committee approval was obtained (number:2023/573) from the local ethics committee and the study was conducted in compliance with the Declaration of Helsinki.

The records have been scanned backward, thus 197 patients with

CBCT scans encompassing the bilateral areas of the maxillary sinus, nasal cavity, and IOC in their field of view (FOV), and taken for various dental reasons between the years 2021 and 2022, were included in the study. The exclusion criteria are as follows: CBCT scans of insufficient diagnostic quality, lack of inclusion of the region of interest, patient age less than 20, having a history of maxillofacial trauma or surgery and presence of an odontologic or sinus-related pathological lesion in the region of interest.

All the included CBCT scans were obtained with the NewTom 5G CBCT machine (QR, Verona, Italy). All the scans were recorded at 110 kV and 3–5 mA, with a 0.16-mm voxel size, 18×16 field of view, and a typical exposure time of 5.4 s. The slice thickness of all the scans was 0.25 mm. Assessments were conducted using the built-in software (NNT) on a Dell Precision T5400 workstation (Dell, TX, USA), with a 32-inch Dell LCD screen having a resolution of 1280×1024 pixels, situated in a darkroom. Two researchers independently conducted the examinations, and in case of disagreement, a consensus was reached through discussion.

Classification of the IOC protrusion degree was made according to the study conducted by Ference et al¹. According to their study, IOCs were categorized into three types based on the ION's course.

Type 1: The ION is situated entirely within the confines of the sinus roof, without extending beyond its boundaries.

Type 2: The ION is positioned below the sinus roof, yet maintains proximity to it, without penetrating the sinus cavity.

Type 3: The ION descends into the sinus cavity, suspended from the sinus roof within a septation or the lamella of the Haller cell. (Figure 1-2)

Figure 1

The coronal CBCT scans displaying the IOC protrusion types. A. Type 1. B. Type 2. C. Type 3,

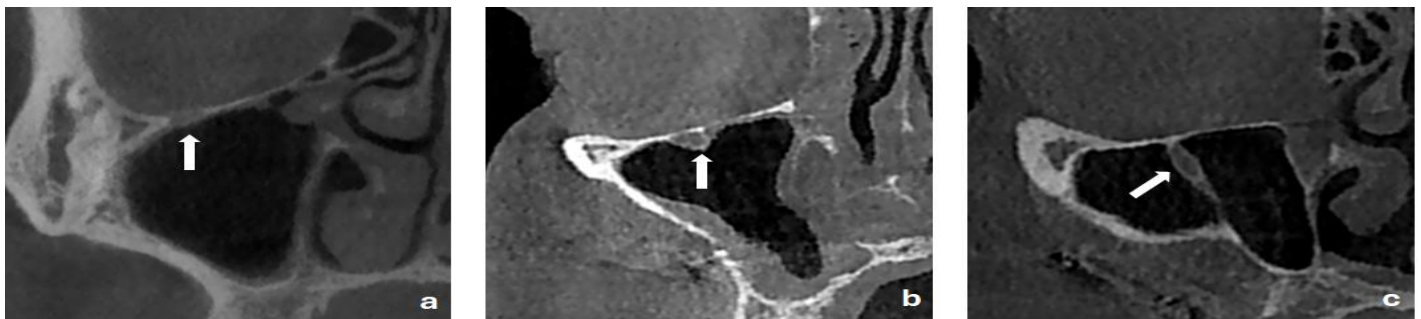
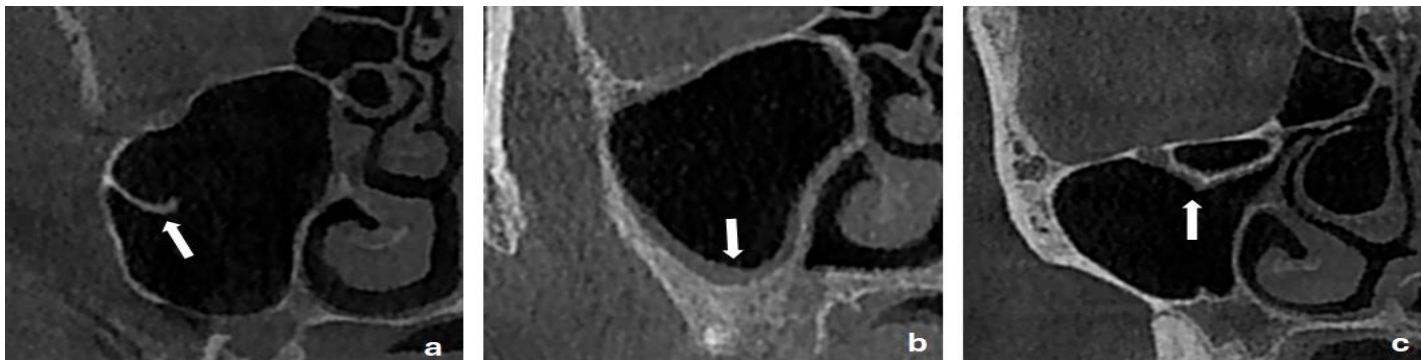


Figure 2

The coronal CBCT scans displaying the variations. A. Presence of septa in the maxillary sinus. B. Mucosal thickening. C. Presence of MTP and Haller cell



Additionally, CBCT scans were examined by two researchers for the presence of Haller cells, MTP, maxillary sinus septa, and mucosal thickening. The investigated variations were determined based on comparison features in the literature, taking into account the studies conducted¹¹⁻¹³. Considering the studies in the literature, mucosal thickening was noted as present when the size of mucosal thickening was 3 mm or more^{11,12}.

Data analysis was performed using SPSS 24.0 software (IBM Corp., New York, NY; formerly SPSS Inc., Chicago, IL). The number and percentage distributions of categorical variables were calculated. The chi-square test was used to evaluate categorical variables, such as the distribution of variations in terms of infraorbital canal protrusion types and the distribution of infraorbital canal protrusion types and variations in terms of gender. The significance level was taken as $p < 0.05$.

3. Results

394 IOCs and maxillary sinuses of 197 individuals (101 women (51.3%), 96 men (48.7%)) included in the study were examined. The mean age of the participants was 44.23 ± 14.3 (20-68). The distribution of all examined IOC according to protrusion types was as follows: Type 1 (n=266) 67.5%, Type 2 (n=89) 22.6%, Type 3 (n=39) 9.9%. Mucosal thickening was observed in 48.2% of all individuals (n=190), MTP in 25.6% (n=101), sinus septa in 12.9% (n=51), and Haller cells in 6% (n=24). (Table 1)

	n	percent
Gender		
· Male	192	48.7%
· Female	202	51.3%
IOC Protrusion Type		
· 1	266	67.5%
· 2	89	22.6%
· 3	39	9.9%
Mucosal thickening		
· Present	190	48.2%
· Absent	204	51.8%
Middle turbinate pneumatization		
· Present	101	25.6%
· Absent	293	74.4%
Sinus Septa		
· Present	51	12.9%
· Absent	343	87.1%
Haller Cell		
· Present	24	6%
· Absent	370	94%

For the relationship between IOC protrusion types and variations, no significant correlation was found regarding mucosal thickening, MTP, or the presence of Haller cells. However, a significant correlation was observed between type 3 IOCs and the presence of septa. Specifically, the presence of septa in the maxillary sinus was 8.3% with type 1 IOCs, 13.5% with type 2 IOCs, and 43.6% with type 3 IOCs. ($p < 0.001$) (Table 2)

No significant relationship was found between gender and the IOC types. (Table 3)

The presence of mucosal thickening was significantly more common

in men than in women, whereas MTP was significantly more common in women than in men. ($p < 0.001$ and $p < 0.001$, respectively) (Table 4)

n (%)	IOC Protrusion Type			p-value
	1 (n=266)	2 (n=89)	3 (n=39)	
Mucosal thickening	132 (49.6%)	41 (46.1%)	17 (43.5%)	0.701
Middle turbinate pneumatization	62 (23.3%)	26 (29.2%)	13 (33.3%)	0.277
Sinus Septa	22 (8.3%)	12 (13.5%)	17 (43.6%)	<0.001
Haller Cell	17 (6.4%)	6 (6.7%)	1 (2.6%)	0.62

Gender n (%)	IOC Protrusion Type			p-value
	1	2	3	
Male (n=192)	134 (69.8%)	40 (20.8%)	18 (9.4%)	0.637
Female (n=202)	132 (65.3%)	49 (24.3%)	21 (10.4%)	

n (%)	Gender		p-value
	Male (n=192)	Female (n=202)	
Mucosal thickening	112 (58.3%)	78 (38.6%)	<0.001
Middle turbinate pneumatization	34 (17.7%)	67 (33.2%)	<0.001
Sinus Septa	32 (16.6%)	19 (9.4%)	0.032
Haller Cell	16 (8.3%)	8 (4%)	0.07

4. Discussion

The infraorbital region is of paramount importance for anesthesia procedures, pain management, and surgical interventions, encompassing fields such as dentistry, otorhinolaryngology, neurology, and ophthalmology.

ZMC fractures are the second most frequently occurring facial fractures, following nasal fractures¹⁵. These fractures have the

potential to cause trauma to the ION through nerve compression, resulting in complications such as permanent paresthesia, sensory neuropathy, and hypoesthesia¹⁶⁻¹⁸. According to a study by Sakavicius et al.¹⁹, sensory disorders of ION were detected in approximately 64% of patients with ZMC fractures, and authors reported that this rate increased up to 79.9% in displaced ZMC fractures. Apart from traumatic causes, iatrogenic damage to the ION can occur during tumor surgeries in the infraorbital area, orbital decompression surgeries, endoscopic interventions, Caldwell-Luc procedures, and Le Fort-type osteotomies. During these interventions, the ION can be stretched and exposed due to displacement of the orbital floor, thus facing the risk of injury^{16,20,21}. In the literature, it has also been noted that the clinician who will perform an ION nerve block must have a comprehensive understanding of the position and anatomy of the IOC to avoid damaging the orbital structures and to administer anesthesia safely³.

According to our findings, type 1 was the most common, while type 3 was the least common, with a rate of 9.9%. It can be inferred that although type 3, which protrudes completely into the maxillary sinus, is less common, its occurrence rate is notable. Similar rates have been reported in the literature. Among studies using CT scans, Ference et al.¹ emphasized that type 1 was the most prevalent, with a type 3 rate of 12.5%. Yenigün et al.¹³ classified the type protruding completely into the maxillary sinus as type 1, reporting a rate of 12.3%. Açar et al.⁵ identified a type 3 rate of 9.5%, although they utilized a different methodology by examining IOCs in four groups, including Type 4, located at the outer limit of the zygomatic recess. Only Haghnegahdar et al.⁴ reported a relatively higher type 3 rate of 23.2%. Studies conducted with CBCT reported type 3 rates of 8.8%, 8%, and 7.9%, consistent with our findings^{11,12,14}.

According to our findings, there was no difference in IOC-type distribution between genders. Similarly, in the literature, the majority of studies did not find any difference in terms of IOC types between genders^{11,12,14}, but Haghnegahdar et al.⁴ stated that the prevalence of type 1 was higher in females while the prevalence of type 2 was higher in males.

It was found that 43.6% of type 3 IOC types had septa in the maxillary sinus, and this relationship was statistically significant. Serindere et al.¹² also reported significant relationships between the presence of septa and IOC type for both the right and left sides; however, contrary to our findings, they noted an increase in the presence of septa in cases of type 1 IOC. Nevertheless, in agreement with our results, Yenigün et al.¹³ identified a significant relationship between type 1, which completely protrudes into the maxillary sinus, and the presence of sinus septa. Their findings indicated that while the rate of type 1 was 9.8% in cases without maxillary sinus septa, this rate increased to 25% when maxillary sinus septa were present. One of the variations frequently associated with IOC types in the literature is the presence of Haller cells. Serindere et al.¹² reported a higher prevalence of Haller cell variation in individuals with type 1 IOC, while Haghnegahdar et al.⁴ and Kalabalık et al.¹¹ found it to be more common in type 2 and type 3 IOC. Ference et al.¹ noted a significant increase in the rate of IOC passing through the sinus in the presence of Haller cells. In contrast, Yenigün et al.¹³ did not find a significant relationship between the presence of Haller cells and IOC types, consistent with our findings.

Only a few studies have assessed the relationship between IOC types and mucosal thickening. One study found a significant association between mucosal thickening and type 1 IOC on the left side only, while another study did not find any relationship, consistent with the findings of the present study^{11,12}. The presence of numerous local and environmental factors that can cause mucosal thickening distinguishes it from other anatomical variations and makes its evaluation more challenging.

Similarly to mucosal thickening, MTP has also been addressed by a small number of studies, and consistent with our findings, the abovementioned studies have not detected a significant relationship between MTP and IOC types^{12,13}. Inconsistencies in findings may be due to age and ethnic factors of the studied groups or due to differences in methodology.

In the individuals included in the study, mucosal thickening was observed in 48.2%, MTP in 25.6%, the presence of septa in 12.5%, and the presence of Haller cells in 6%. Mucosal thickness rates reported in the literature vary between 27.1% and 57.1%^{11,12,22,23}. It is important to consider that mucosal thickening can be influenced by various environmental factors. MTP rates range from 18.2% to 76.4% according to a review²³, with the rate most similar to our study being 21.5%, as reported by Yenigün et al.¹³ Similarly, the rate of septa presence varies between 5.3% and 36.9%, while the presence of Haller cells has been reported in ranges from 3.5% to 61.5%.^{12,23,24} Yenigün et al.¹³ also detected Haller cells at a rate of 4.9%, similar to our study's findings.

The limitations of our study include small sample size, the absence of separate evaluations for the right and left sides, and the lack of assessment of other sinonasal variations. As another limitation, there are certainly numerous factors that can contribute to mucosal thickening. Therefore, to accurately determine whether there is a true relationship between different types of IOC and mucosal thickening, it would be more appropriate to establish an isolated study group by excluding various conditions. Future studies should aim to include larger sample sizes, perform bilateral evaluations, and investigate a wider range of sinonasal variations to provide a more comprehensive understanding.

CBCT is becoming increasingly common in dentistry, particularly for cases involving maxillary pathology, missing teeth, or orthodontic concerns. As CBCT scans typically encompass the contents of the maxillary sinus and the IOC, oral radiologists must identify and report any variations in the maxillary sinus. This responsibility falls within their scope of practice⁷. When planning surgical interventions or ION anesthesia in the IOC area, it is advisable to review the patient's radiological records. If available, CBCT scans should be utilized as they are considered sufficient for evaluating the IOC.

5. Conclusion

Although the protrusion of the IOC into the maxillary sinus is relatively uncommon, it should not be overlooked. Additionally, a significant relationship was observed between sinus septa and the type of IOC protruding into the maxillary sinus. It is advisable to have a thorough understanding of its anatomy and degree of protrusion before undertaking procedures in the relevant area. CBCT scans offer valuable information in this regard.

Statement of ethics

This study was conducted in accordance with the ethical principles of the Declaration of Helsinki and was approved *Erciyes University* Scientific Research and Publication protocol number:2023/573

Conflict of interest statement

The authors declare that they have no financial conflict of interest with regard to the content of this report.

Funding source

The authors received no financial support for the research, authorship, and/or publication of this article.

Author Contributions

The authors confirm contribution to the paper as follows: study conception and design: Aykağan Çukurluoğlu; data collection: Zeynep Firdevs Sönmez; analysis and interpretation of results: Aykağan Çukurluoğlu, Zeynep Firdevs Sönmez; draft manuscript: Aykağan Çukurluoğlu, Zeynep Firdevs Sönmez. All authors reviewed the results and approved the final version of the manuscript.

Availability of data and materials

The datasets used and/or analyzed during the current study are available from the corresponding author on reasonable request.

References

1. Ference EH, Smith SS, Conley D, et al. Surgical anatomy and variations of the infraorbital nerve. *The Laryngoscope*. 2015;125:1296-300. <https://doi.org/10.1002/lary.25089>
2. Leo JT, Cassell MD, Bergman RA Variation in human infraorbital nerve, canal and foramen. *Ann Anat*. 1995;177:93-5. [https://doi.org/10.1016/S0940-9602\(11\)80139-1](https://doi.org/10.1016/S0940-9602(11)80139-1)
3. Lee UY, Nam SH, Han SH, et al. Morphological characteristics of the infraorbital foramen and infraorbital canal using three-dimensional models. *Surg Radiol Anat*. 2006;28:115-20. <https://doi.org/10.1007/s00276-005-0071-y>
4. Haghnegahdar A, Khojastepour L, Naderi A Evaluation of infraorbital canal in cone beam computed tomography of maxillary sinus. *J Dent*. 2018;19:41.
5. Açar G, Özen KE, Güler İ, et al. Computed tomography evaluation of the morphometry and variations of the infraorbital canal relating to endoscopic surgery. *Braz J Otorhinolaryngol*. 2018;84:713-21. <https://doi.org/10.1016/j.bjorl.2017.08.009>
6. Lechuga L, Weidlic GA Cone Beam CT vs. Fan Beam CT: A Comparison of Image Quality and Dose Delivered Between Two Differing CT Imaging Modalities. *Cureus*. 2016;8:e778. <https://doi.org/10.7759/cureus.778>
7. Yeung AWK, Hung KF, Li DTS, et al. The use of CBCT in evaluating the health and pathology of the maxillary sinus. *Diagnostics*. 2022;12:2819. <https://doi.org/10.3390/diagnostics12112819>
8. Ludlow JB, Ivanovic M Comparative dosimetry of dental CBCT devices and 64-slice CT for oral and maxillofacial radiology. *Oral Surg Oral Med Oral Pathol Oral Radiol Endod*. 2008;106:106-14. <https://doi.org/10.1016/j.tripleo.2008.03.018>
9. Aşantoğrul F, Coşgunarslan A The effect of anatomical variations of the sinonasal region on maxillary sinus volume and dimensions: a three-dimensional study. *Braz J Otorhinolaryngol*. 2023;88:118-27. <https://doi.org/10.1016/j.bjorl.2021.05.001>
10. Özcan İ, Göksel S, Çakır-Karabaş H, et al. G CBCT analysis of haller cells: relationship with accessory maxillary ostium and maxillary sinus pathologies. *Oral Radiol*. 2021;37:502-6. <https://doi.org/10.1007/s11282-020-00487-2>
11. Kalabalık F, Aktaş T, Akan E, et al. Radiographic evaluation of infraorbital canal protrusion into maxillary sinus using cone-beam computed tomography. *J Oral Maxillofac Res*. 2020;11. <https://doi.org/10.5037/jomr.2020.11405>
12. Serindere G, Serindere M Cone beam computed tomographic evaluation of infraorbital canal protrusion into the maxillary sinus and its importance for endoscopic surgery. *Braz J Otorhinolaryngol*. 2023;88:140-7. <https://doi.org/10.1016/j.bjorl.2022.07.002>
13. Yenigün A, Gün C, Uysal II, et al. Radiological classification of the infraorbital canal and correlation with variants of neighboring structures. *Eur Arch Otorhinolaryngol*. 2016;273:139-44. <https://doi.org/10.1007/s00405-015-3550-8>
14. Fontollet M, Bornstein MM, von Arx T Characteristics and dimensions of the infraorbital canal: a radiographic analysis using cone beam computed tomography (CBCT). *Surg Radiol Anat*. 2019;41:169-79. <https://doi.org/10.1007/s00276-018-2108-z>
15. English GM Otolaryngology: a textbook. (No Title) 1976).
16. Kazkayasi M, et al. Certain anatomical relations and the precise morphometry of the infraorbital foramen-canal and groove: an anatomical and cephalometric study. *The Laryngoscope*. 2001;111:609-14. <https://doi.org/10.1097/00005537-200104000-00010>
17. Olenczak JB, et al. Posttraumatic midface pain: clinical significance of the anterior superior alveolar nerve and canal sinusoid. *Ann Plast Surg*. 2015;75:543-7. <https://doi.org/10.1097/SAP.0000000000000335>
18. Jungell P, Lindqvist C Paraesthesia of the infraorbital nerve following fracture of the zygomatic complex. *Int J Oral Maxillofac Surg*. 1987;16:363-7. [https://doi.org/10.1016/S0901-5027\(87\)80160-1](https://doi.org/10.1016/S0901-5027(87)80160-1)
19. Sakavicius D, Juodzbaly G, Kubilius R, et al. Investigation of infraorbital nerve injury following zygomaticomaxillary complex fractures. *J Oral Rehabil*. 2008;35:903-16. <https://doi.org/10.1111/j.1365-2842.2008.01888.x>
20. Sakavicius D, Kubilius R, Sabaly G Post-traumatic infraorbital nerve neuropathy. *Medicina (Kaunas, Lithuania)*. 2002;38:47-51.
21. Lawrence J, Poole M Mid-facial sensation following craniofacial surgery. *Br J Plast Surg*. 1992;45:519-22. [https://doi.org/10.1016/0007-1226\(92\)90146-0](https://doi.org/10.1016/0007-1226(92)90146-0)
22. Ritter L, et al. Prevalence of pathologic findings in the maxillary sinus in cone-beam computerized tomography. *Oral Surg Oral Med Oral Pathol Oral Radiol Endod*. 2011;111:634-640. <https://doi.org/10.1016/j.tripleo.2010.12.007>
23. Papadopoulou AM, Chrysikos D, Samolis A, et al. Anatomical variations of the nasal cavities and paranasal sinuses: a systematic review. *Cureus*. 2021;13. <https://doi.org/10.7759/cureus.12727>
24. Papadopoulou AM, Bakogiannis N, Skrapari I, et al. Anatomical variations of the Sinonasal Area and their clinical impact on Sinus Pathology: a systematic review. *Int Arch Otorhinolaryngol*. 2022;26:491-8. <https://doi.org/10.1055/s-0042-1742327>