

## The role of oxidative stress, apoptosis and altered TRPM2 channel activation in doxorubicin-induced liver injury; the protective effect of selenium

Doksorubisin kaynaklı karaciğer hasarında oksidatif stres, apoptoz ve değişen TRPM2 kanalı aktivasyonunun rolü; selenyumun koruyucu etkisi

Kenan Yıldızhan<sup>1\*</sup>, Zübeyir Huyut<sup>2</sup>, Fikret Altındağ<sup>3</sup>, Mehmet Hafit Bayır<sup>3</sup>

1.Department of Biophysics, Faculty of Medicine, Van Yuzuncu Yil University, Van, Türkiye

2.Department of Biochemistry, Faculty of Medicine, Van Yuzuncu Yil University, Van, Türkiye

3.Department of Histology and Embryology, Faculty of Medicine, Van Yuzuncu Yil University, Van, Türkiye

### ABSTRACT

**Aim:** Doxorubicin (DOXR) is frequently used alone or as combination therapy in the treatment of various types of cancer. Although dose-dependent side effects are known, its effects on liver health are not fully known. This study aimed to investigate the role of the transient receptor potential melastatin-2 (TRPM2) channel in DOXR-treated rats using the TRPM-2 channel blocker N-(p-amylicinamoyl) anthranilic acid (ACA) and to investigate the protective effects of selenium (Se).

**Methods:** Rats were allocated into six groups, each containing ten rats: control, DMSO, DOXR, DOXR + Se, DOXR + ACA, and DOXR + ACA + Se. Serum levels of AST, ALT, LDH, triglycerides, and total cholesterol were measured. Additionally, liver tissues were subjected to immunohistochemical tests for TRPM2 channel, 8-OHdG, and caspase-3 (Casp-3) expressions and also histopathological evaluation.

**Results:** Serum AST, ALT, LDH, triglyceride and total cholesterol levels, as well as liver 8-OHdG, TRPM2 channel and Casp-3 expressions in the DOXR group were significantly higher than in the DOXR + Se, DOXR + ACA and DOXR + ACA + Se groups ( $p < 0.05$ ). However, these parameters were significantly reduced in the Se and ACA-treated groups compared to the DOXR group ( $p < 0.05$ ).

**Conclusions:** The results suggest that simultaneous administration of Se or ACA with DOXR may provide an effective therapeutic approach to combat DOXR-induced hepatotoxicity.

Keywords: Apoptosis, Doxorubicin, Hepatotoxicity, Lipid Profile, TRPM2 Channel

### ÖZ

**Amaç:** Doksorubisin (DOXR) çeşitli kanser türlerinin tedavisinde sıklıkla tek başına veya kombinasyon terapisi olarak kullanılmaktadır. Doza bağlı olarak değişen yan etkiler bilinmesine rağmen, karaciğer sağlığı üzerindeki etkileri tam olarak bilinmemektedir. Bu araştırma, DOXR ile tedavi edilen sıçanlarda geçici reseptör potansiyeli melastatin-2 (TRPM2) kanalının rolünü, TRPM-2 kanal blokörü N-(p-amilsinamoyl) antranilik asit (ACA) kullanarak araştırmayı ve selenyum (Se)'un koruyucu etkilerini araştırmayı amaçladı.

**Yöntemler:** Sıçanlar altı gruba ayrıldı (n=10): kontrol, DMSO, DOXR, DOXR + Se, DOXR + ACA ve DOXR + ACA + Se. Serum AST, ALT, LDH, trigliserit ve total kolesterol seviyeleri ölçüldü. Ayrıca, karaciğer dokusunda TRPM2 kanalı, 8-OHdG ve kaspaz-3 (Casp-3) ekspresyonları için immünohistokimyasal testler ve ayrıca histopatolojik değerlendirme yapıldı.

**Bulgular:** Serum AST, ALT, LDH, trigliserid ve total kolesterol seviyeleri ve ayrıca karaciğer 8-OHdG, TRPM2 kanalı ve Casp-3 ekspresyonları DOXR grubunda DOXR + Se, DOXR + ACA ve DOXR + ACA + Se gruplarına göre anlamlı derecede yüksekti ( $p < 0.05$ ). Ancak, bu parametreler Se ve ACA ile tedavi edilen gruplarda DOXR grubuna kıyasla önemli ölçüde düşmüştü ( $p < 0.05$ ).

**Sonuç:** Sonuçlar, Se veya ACA'nın DOXR ile eşzamanlı uygulanmasının, DOXR kaynaklı hepatotoksisiteyle mücadelede etkili bir terapötik yaklaşım sağlayabileceğini göstermektedir.

Anahtar Kelimeler: Apoptoz, Doksorubisin, Hepatotoksisite, Lipid Profili, TRPM2 Kanalı

RECEIVED: 14.05.2024 ACCEPTED: 30.07.2024 PUBLISHED (ONLINE): 30.08.2024

\*Corresponding Author: Kenan Yıldızhan, Department of Biophysics, Faculty of Medicine, Van Yuzuncu Yil University, Van, Türkiye. Phone:+905356069814 / mail: kenanyldzhan@gmail.com

ORCID: 0000-0002-6585-4010

**To cited:** Yıldızhan K, Huyut Z, Altındağ F, Bayır MH. The role of oxidative stress, apoptosis and altered TRPM2 channel activation in doxorubicin-induced liver injury; the protective effect of selenium. Acta Med. Alanya 2024;8(2): 127-134 doi: 10.30565/medalanya.1483307

## Introduction

**D**oxorubicin (DOXR) is derived from the anthracycline class of chemotherapeutic agents [1]. Despite their higher toxicity compared to other medical treatments, the effectiveness of antineoplastic drugs against cancer, a leading and persistent cause of death, justifies their use [2]. DOXR mainly causes dose-dependent adverse effects on the heart, kidneys, and liver. Numerous studies have confirmed that DOXR primarily induces liver toxicity via the production of free radicals in non-target tissues. This process results in oxidative stress (OS), inflammation, the production of reactive oxygen species (ROS), and ultimately apoptosis [2].

Selenium (Se) plays a critical role in the body's antioxidant defence mechanisms and is vital for numerous biological functions as a component of the GSH-Px enzyme [3]. Malyar et al. showed that selenium supplementation can mitigate OS, inflammation, apoptosis, and fibrosis in thermally damaged liver tissues in mice [4]. Further studies have linked the roles of selenium and selenoproteins in various physiological processes, including neurotransmission, inflammation modulation, ion channel regulation (including TRP channels), protein phosphorylation, calcium balance, and cholesterol metabolism in the brain to their antioxidant properties [5].

The transient receptor potential melastatin-2 (TRPM2) channel, a member of the TRP channel family, is a voltage-independent, non-selective cation channel activated by oxidative molecules. Expressed in the liver, TRPM2 contributes to inflammation and apoptosis by increasing cellular calcium, thus functioning as an OS sensor [6]. This activation underscores TRPM2's critical role in cellular damage mechanisms [7, 8]. Recent studies have suggested TRPM2 as a potential therapeutic target for liver-related oxidative stress diseases. N-(p-aminocinnamoyl) anthranilic acid (ACA), initially used to inhibit leukotriene-mediated bronchoconstriction, has been found to inhibit phospholipase-A2 effectively [9, 10]. Thus, this research has chosen to investigate the blockade of the TRPM2 channel using ACA. To date, the role of the TRPM2 channel and the protective effects of selenium against DOXR-induced liver

toxicity have not been simultaneously examined. This study explores the functionality of TRPM2 and the protective effect of Se against DOXR-induced hepatotoxicity.

## Materials and Methods

### Chemicals

Doxorubicin (DOXR) (T1020) and N-(p-aminocinnamoyl) anthranilic acid (ACA) (T5454) were supplied by TargetMol (Target Molecule Corp., USA), while sodium selenite (214485) was provided by Sigma Aldrich (St. Louis, MO, USA).

### Animals and Experimental Design

The study utilized 60 Albino Wistar rats, aged 2-3 months. The rats were housed in plastic cages under a 12-hour light/dark photoperiod at 24°C. Total weight averages of the groups were optimized by measuring the weights of the rats at the beginning of the study. DMSO was used as a solvent for DOXR and ACA. Sodium selenite was dissolved in saline. DOXR, Se, and ACA dosages and duration were administered according to previously documented protocols [11-13]. The rats were divided into the following six groups:

- 1-Control: received daily intraperitoneal (i.p.) injections of isotonic solution (100 µL) for 14 days.
- 2- DMSO: received alternate day i.p. injections of DMSO (100 µL) for 14 days.
- 3- DOXR: received alternate day i.p. injections of DOXR (2.5 mg/kg) for 14 days [11].
- 4- DOXR+ACA: received alternate day i.p. injections of DOXR (2.5 mg/kg) and daily i.p. injections of ACA (25 mg/kg) for 14 days [12].
- 5- DOXR+Se: received alternate day i.p. injections of DOXR (2.5 mg/kg) and daily i.p. injections of Se (0.5 mg/kg) for 14 days [13].
- 6- DOXR+Se+ACA: received alternate day i.p. injections of DOXR (2.5 mg/kg) along with daily i.p. injections of Se (0.5 mg/kg) and ACA (25 mg/kg) for 14 days.

After the study, the rats were anesthetized with ketamine (50 mg/kg) + xylazine (20 mg/kg), and their abdominal cavities were surgically opened. Intracardiac blood samples were collected

and transferred to biochemistry tubes. After, centrifuged at 3500 xg for 10 min [14]. The liver was extracted and stored in the freezer for biochemical analysis, while liver tissues were preserved for histopathological and immunohistochemical evaluations.

### Biochemical Evaluation

Serum AST and LDH levels were measured using spectroscopic methods with an Abbott Architect c16000 biochemical autoanalyzer (USA). Additionally, total cholesterol, HDL, LDL, and triglyceride levels were assessed through colorimetric analysis.

### Histopathological Evaluation

Liver samples were preserved in 10% buffered formalin and subjected to dehydration with graded alcohols. After dehydration, samples were cleared in xylene and embedded in paraffin. Liver tissue sections, five micrometers thick, were sliced with a microtome and stained with Hematoxylin and Eosin, then examined under an Olympus BX53 microscope (Japan). Photographic records were created using Cellsens Imaging Software (Olympus, Japan). A semi-quantitative assessment was also performed, categorised as normal (-), mild (+), moderate (++), and severe (+++).

### Immunohistochemical Evaluation

Paraffin blocks of 5 µm thick sections were deparaffinised and dehydrated. To reduce non-specific staining, sections were treated with 3% H<sub>2</sub>O<sub>2</sub> for 10 min. Antigen retrieval was enhanced through microwave heating in citrate buffer (pH 6.1) for 5 min in two sessions. Non-specific staining was blocked at room temperature for 10 min using Ultra V Block. Primary antibodies against 8-OHdG (Santa Cruz Biotechnology, sc-20067, dilution: 1/50), TRPM2 (Bioss Inc., bs-2888R, dilution: 1/200), and Caspase-3 (Santa Cruz Biotechnology, sc-7272, dilution: 1/50) were applied and incubated overnight at 4°C in a humid chamber. Subsequently, the image sections were evaluated with an H-score using an Olympus BX53 microscope (Japan).

**Statistical Methods:** Statistical analysis was performed using SPSS version 21. The

normal distribution of biochemical data was confirmed with the Kolmogorov-Smirnov test. Biochemical data with a normal distribution were analyzed using One-way ANOVA followed by Tukey's HSD test, with a significance level set at  $p \leq 0.05$ . Immunohistochemical and immunohistopathological data were analyzed using the Kruskal-Wallis test and the Bonferroni Adjusted Mann-Whitney U test to determine differences between groups. The intensity of positive staining was assessed over five randomly selected fields using ZEISS Zen Imaging Software. Data were considered significant at  $p$  values  $\leq 0.05$ .

## Results

### Analysis of Research Findings

In the DOXR-induced liver injury scenario, liver function tests showed that serum AST, ALT, LDL, total cholesterol and triglyceride levels were increased, while HDL levels were lower in the DOXR group compared with the other groups ( $p < 0.05$ ). No significant differences in these parameter levels were observed between the control and DMSO groups in these levels. Notably, the DOXR+ACA and DOXR+Se groups showed reductions in AST, ALT, LDL, total cholesterol, and triglyceride levels and increased HDL levels compared to the DOXR group ( $p < 0.05$ ). The ACA+Se combination therapy displayed the lowest levels of AST, ALT, LDL, and total cholesterol and lower triglyceride levels compared to other treatments ( $p < 0.05$ , and Figure 1).

### Histopathological and Immunohistochemical Observations

Normal liver histology was observed in the control and DMSO groups, as indicated in Table 1. DOXR treatment caused karyolysis, sinusoidal dilation, and disorganization of hepatic cords. Treatments with Se and ACA significantly ameliorated the hepatotoxic effects of DOXR (Figure 2).

### Immunohistochemical examinations

Expressions of 8-OHdG (Figure 3A), TRPM2 channel (Figure 3B) and Casp-3 (Figure 3C) in liver tissue were evaluated by immunohistochemical method ( $p < 0.05$ ). DOXR administration significantly increased the expression of 8-OHdG,

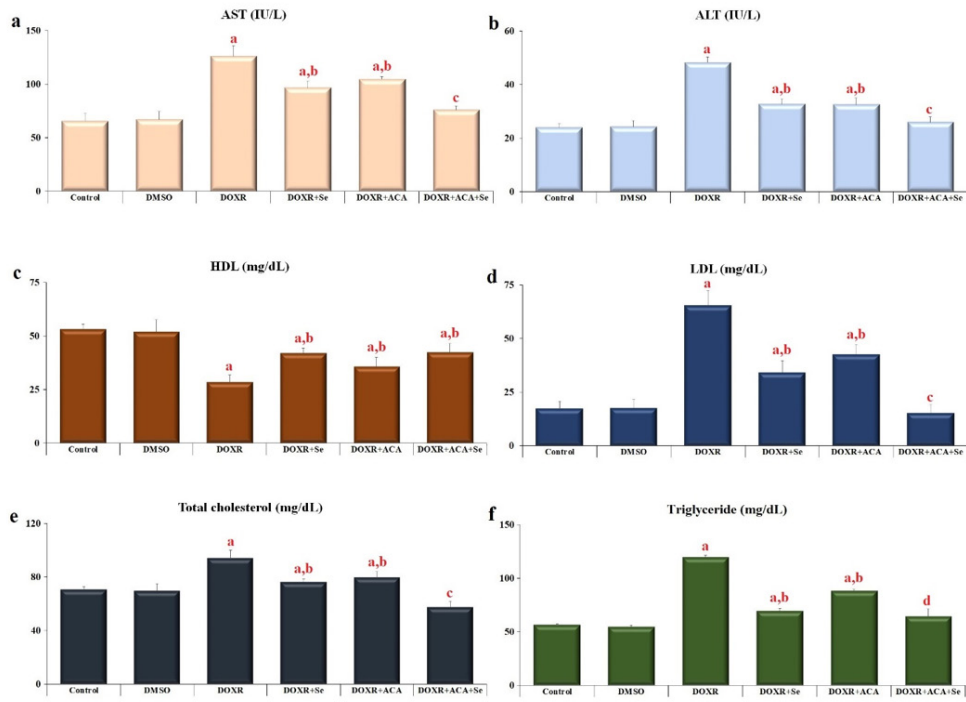


Figure 1. Effect of Se and ACA on serum parameters in DOXR-induced hepatotoxicity. a: AST (IU/L); b: ALT (IU/L); c: HDL (mg/dL); d: LDL (mg/dL); e: Total cholesterol (mg/dL); f: Triglyceride (mg/dL). (Values were given as mean  $\pm$  SD; n=10). (ap < 0.05 compared with the control and DMSO groups; bp < 0.05 compared with DOXR group; cp < 0.05 compared with DOXR, DOXR+ACA and DOXR+Se groups; dp < 0.05 compared with DOXR and DOXR+ACA groups).

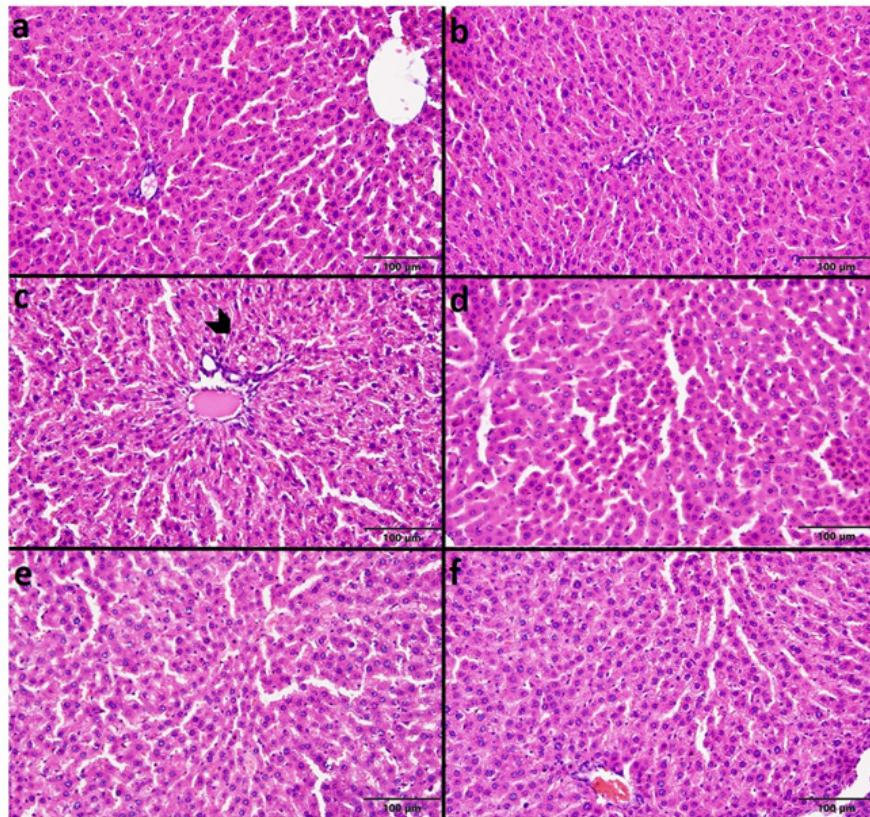


Figure 2. Histopathological Photomicrographs (H&E staining) rassociated with the effect of Se and ACA on DOXR-induced hepatotoxicity. Arrowhead: karyolytic nucleus. control group (a); DMSO group (b); DOXR group (c); DOXR+Se group (d); DOXR+ACA group (e); DOXR+ACA+Se group (f). (Bar; 100  $\mu$ m).

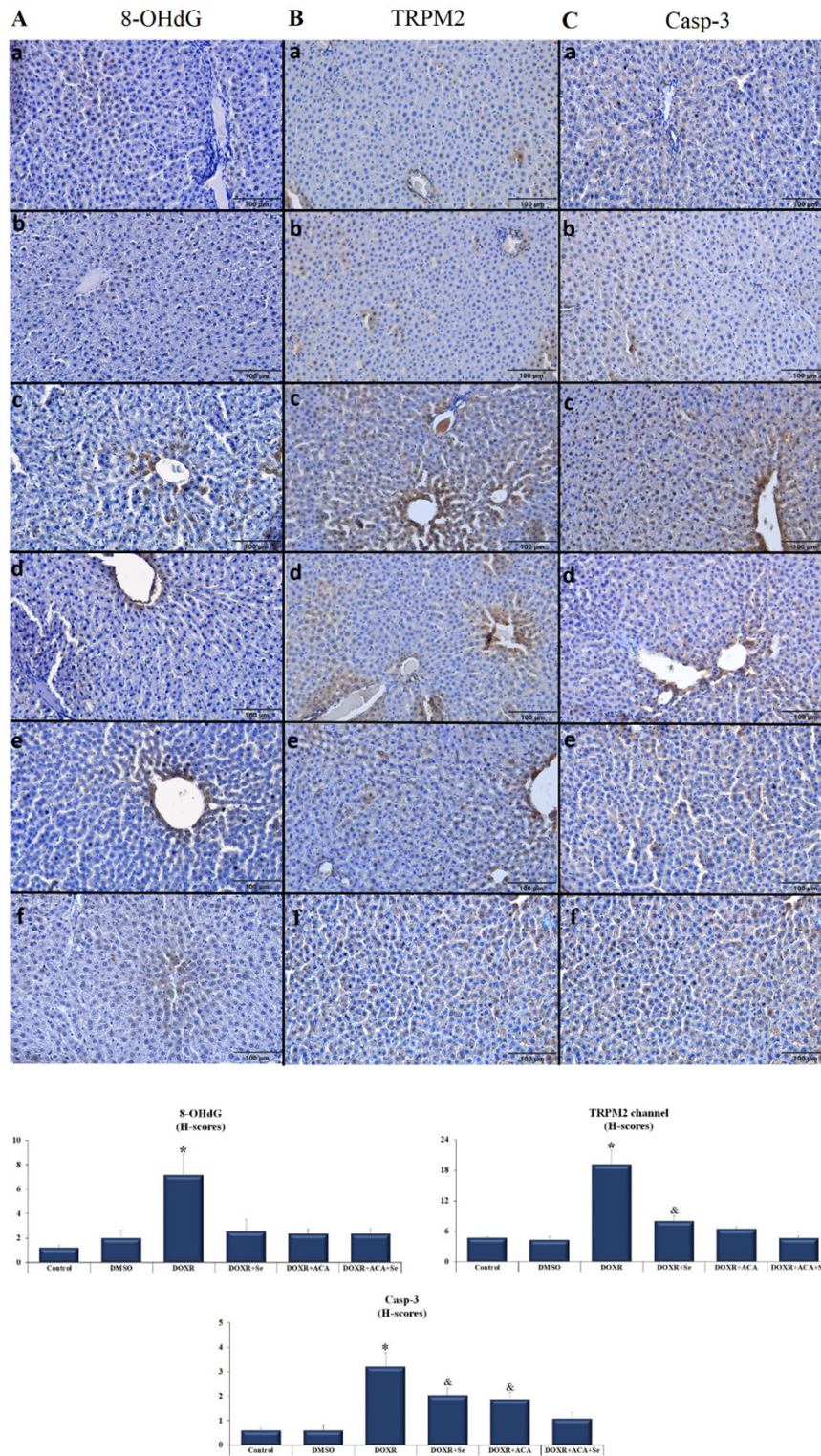


Figure 3. Immunohistochemical Photomicrographs and bar graphs associated with the effect of Se and ACA on 8-OHdG (A), TRPM2 channel (B), and Casp-3 (C) expression in DOXR-induced hepatotoxicity. The expressions were detected by immunohistochemical staining. Control group (a); DMSO group (b); DOXR group (c); DOXR+Se group (d); DOXR+ACA group (e); DOXR+ACA+Se group (f). (Bar; 100  $\mu$ m). (\* $p < 0.05$  versus DOXR groups; & $p < 0.05$  versus DOXR+Se and DOXR+ACA groups).

TRPM2 channel, and Casp-3 in the liver ( $p < 0.05$ ). However, 8-OHdG, TRPM2 channel, and Casp-3 expression significantly decreased in DOXR+ACA and DOXR+Se+ACA groups compared to the

DOXR group ( $p < 0.05$ ). There was no significant difference in Casp-3 expression between the application of Se and ACA for combined or individual therapy ( $p > 0.05$ ).

Table 1. Effect of Se and ACA on liver histology following DOXR-induced liver damage.

		Histological change		
		Karyolysis	Sinusoidal dilatation	Disarrangement of the hepatic cord structure
Groups	Control	-	-	-
	DMSO	-	-	-
	DOXR	++	++	+
	DOXR+Se	+	+	-
	DOXR+ACA	+	+	+
	DOXR+ACA+ Se	+	-	-

normal (-); mild (+); moderate (++); and severe (+++), DMSO: Dimethyl sulfoxide, DOXR: Doxorubicin, ACA: N-(p-aminocinnamoyl) anthranilic acid, Se: Selenium.

## Discussion

Doxorubicin (DOXR) is widely recognised as an effective anticancer agent for treating various cancer types [15]. The literature highlights significant concerns regarding DOXR's cardiotoxic and hepatotoxic effects. The liver, due to its numerous vital functions, is particularly susceptible to the adverse effects of drugs, and this feature underscores the necessity of strategies to mitigate these side effects. Selenium (Se), a critical trace element with robust antioxidant properties, plays a role in various biological functions [3]. Its antioxidant features are fundamental to various physiological processes such as fertility, endocrine and immune functions, carcinogenesis, cardiovascular health, and gender-specific muscle development [16]. Studies by Cengiz et al. have emphasised that specific doses of Se could mitigate DOXR-induced liver damage by reducing pro-inflammatory cytokine levels [12].

The TRPM subfamily, especially TRPM2, has drawn significant interest due to its role in physiological and pathological processes such as cellular proliferation, temperature regulation, vascular development, neurological disorders, cancer progression, and endothelial dysfunction. The presence of TRPM2 in various cell types, including nerve, liver, endothelial, and kidney cells, further underscores its biological significance [7, 8]. Kheradpezhou et al. have shown that acetaminophen-induced liver toxicity is associated with the activation of the TRPM2 channel in hepatocytes, and blocking the channel with ACA

and clotrimazole could reduce the severity of the damage [17]. Therefore, we used ACA to block the TRPM2 channel in this study.

The mechanisms of hepatotoxicity induced by doxorubicin (DOXR) are multifaceted. Recent studies have identified oxidative stress as one of the primary mechanisms driving oxidation-induced hepatotoxicity. Singla et al. have reported significant alterations in oxidative damage and hepatotoxicity parameters in the livers of rats subjected to DOXR-induced liver toxicity [18]. Wali et al. observed substantial increases in ALT, AST, ALP, and LDH serum levels in association with DOXR. Kuzu et al. found a significant rise in AST and ALT levels in liver function tests of rats administered DOXR [19]. Our study observed higher levels of serum AST, ALT, LDL, total cholesterol, and triglycerides in the DOXR group compared to other groups, aligning with previous findings. In addition, HDL levels were notably lower in the DOXR group compared to other groups. Additionally, we observed significant decreases in AST, ALT, LDL, total cholesterol levels, and triglycerides in the DOXR+ACA and DOXR+Se groups compared to the DOXR group. The lowest AST, ALT, LDL, and total cholesterol levels were seen in DOXR groups treated with a combination of ACA and Se. We also noted that triglyceride levels were significantly lower in the group treated with DOXR compared to the DOXR and DOXR+ACA groups (Figure 1).

Wali et al. reported that DOXR administration led to infiltration in liver cells, sinusoidal dilatation, hepatocyte degeneration, periportal fibrosis, focal necrosis, and steatosis, thus resulting in tissue damage/atrophy [20]. Kuzu et al. observed that the liver tissues of the group not receiving DOXR maintained a normal histological appearance. Furthermore, severe coagulation necrosis, hydropic degeneration, serosal thickening, mononuclear cell infiltration in necrotic areas, severe hyperemia, and bleeding in interstitial vessels in liver tissues were seen in the group treated with DOXR [19]. Bilgiç et al. observed granular and vacuolar degeneration, hemorrhagic areas, macro and parenchymal mononuclear cell infiltration, picnotic nuclei in hepatocytes, sinusoidal dilatation, and vascular congestion and dilation in the histopathological examination of liver

damage induced by DOXR [21]. We determined that the control and DMSO groups possessed normal liver histology in the histopathological examination of liver samples. However, DOXR administration caused karyolysis (apoptosis), sinusoidal dilation, and disorganization in the hepatic cord structure of hepatocytes. Furthermore, we found that treatments with Se and ACA significantly inhibited DOXR-induced hepatotoxicity (Table 1 and Figure 2). In a study investigating the function of the TRPM2 channel in liver ischemia/reperfusion (I/R) injury, TRPM2 expression was significantly up-regulated in liver tissue after I/R in the mouse liver I/R model. In contrast, histological damage, ALT, and AST levels in TRPM2 knockout mice were significantly lower compared to wild-type mice [22]. An *in vitro* study targeting the TRPM2 ion channel in non-alcoholic fatty liver injury-induced hepatocytes was showed that a new therapeutic strategy could be developed for oxidative stress-induced liver injury in non-alcoholic fatty liver injury. A study in hepatocytes isolated from rats showed that TRPM2 was mainly localized in intracellular organelles in rat hepatocytes, and oxidative stress-mediated damage to the cell results in increased expression of TRPM2 channels on the cell surface, most likely due to lysosomal trafficking. In addition, it has been emphasized that TRPM2 provides positive feedback that promotes further migration and cell death. Furthermore, the literature has reported that an increase in oxidative stress causes the expression of TRPM2 channels in many different cell types. Also, it has been reported that TRPM2 expression and increased channel activation trigger cell apoptosis mechanisms and promote cell death [7, 8, 12]. A different study evaluated the occurrence of DOXR-induced apoptosis/necrosis, genomic damage, oxidative stress and liver pathologies in rat liver tissue. In addition, in the histopathological examination of the liver tissue, it was determined that the use of DOXR caused remarkable histological changes in hepatocytes, including central vein occlusion, parenchymal inflammation around the main vein, periportal inflammation, and sinusoidal dilatation [23].

8-OHdG is an essential fundamental biomarker to measure endogenous oxidative DNA damage. Khan et al. examined the multiple side effects of DOXR in mice. They showed that the DOXR

significantly increased 8-OHdG levels compared with the treatment groups. In addition, they noted that green synthesized selenium nanoparticles used for therapeutic purposes showed a protective effect against DOXR-induced damage [24]. Furthermore, it has been emphasized that oxidative stress, which also increases TRPM2 channel activation, triggers 8-OHdG levels in DOXR-induced liver damage [25]. Bilgic et al. showed that the Casp-3 expression in the DOXR-induced liver damage was increased compared to the control group [21]. In our study, was revealed that DOXR administration significantly increased the expression of 8-OHdG (Figure 3A), TRPM2 channel (Figure 3B) and Casp-3 (Figure 3C) in the liver. However, the expressions of 8-OHdG, TRPM2 channel and Casp-3 in the liver tissues were significantly decreased in the groups using Se and ACA together with DOXR compared to the DOXR group.

#### **Limitations:**

The limitations of the study are that more subjects could not be used in the study due to animal rights stated in the Declaration of Helsinki, which was revised in 2000, and that the studied parameters could not be examined molecularly due to the low project budget.

**Conclusion:** This study demonstrated that DOXR causes elevation of AST, LDH, HDL, LDL, and total cholesterol levels in serum samples and increases the expression of 8-OHdG, TRPM2 channel, and Casp-3 in liver tissue. However, the co-administration of Se and ACA with DOXR mitigated these effects and restored the lipid profile, and reduced the expression of 8-OHdG, TRPM2 channel, and Casp-3. These findings suggest that using Se and ACA as TRPM2 channel antagonists following DOXR administration may confer hepatic protection. Furthermore, further investigations at the molecular level are warranted to elucidate the underlying mechanisms of damage fully.

**Conflict of Interest:** The authors declare no conflict of interest related to this article.

**Funding sources:** The authors declare that this study has received no financial support.

**Ethics Committee Approval:** The Van Yuzuncu

Yil University Animal Experiments Local Ethics Committee approved this study (decision number: 2022/12-03, approval date: 01.12.2022).

**ORCID and Author contribution: K.Y. (0000-0002-6585-4010), Z.H. (0000-0002-7623-1492) F.A. (0000-0002-7085-623X) M.H.B. (0000-0001-5821-4560).** KY and ZH designed the study, performed the experiments, and analyzed the data. FA and MHB performed histology and IHC analyses. KY and ZH performed biochemical analyses and drafted the manuscript. All authors read and approved the final manuscript.

**Peer-review:** Externally peer reviewed.

**Acknowledgement:** This study was presented as an oral presentation at the 14th International Medicine and Health Sciences Researches Congress (UTSAK 2023).

#### REFERENCES

- Jain D. Cardiotoxicity of doxorubicin and other anthracycline derivatives. *J Nucl Cardiol.* 2000;7(1): 53-62. doi: 10.1067/mnc.2000.103324.
- Gabizon AA, Patil Y, and La-Beck NM. New insights and evolving role of pegylated liposomal doxorubicin in cancer therapy. *Drug Resist Updat.* 2016;29:90-106. doi: 10.1016/j.drup.2016.10.003.
- Naziroglu M, Oz A, Yıldızhan K. Selenium and Neurological Diseases: Focus on Peripheral Pain and TRP Channels. *Curr Neuropharmacol.* 2020;18(6):501-17. doi: 10.2174/1570159X18666200106152631.
- Reich HJ and Hondal RJ. Why nature chose selenium. *ACS Chem Biol.* 2016;11(4):821-41. doi: 10.1021/acscchembio.6b00031.
- Solovyev ND. Importance of selenium and selenoprotein for brain function: From antioxidant protection to neuronal signalling. *J Inorg Biochem.* 2015;153:1-12. doi: 10.1016/j.jinorgbio.2015.09.003.
- Ali ES, Rychkov GY, Barritt GJ. TRPM2 non-selective cation channels in liver injury mediated by reactive oxygen species. *Antioxidants (Basel).* 2021;10(8):1243. doi: 10.3390/antiox10081243.
- Malko P, Jiang LH. TRPM2 channel-mediated cell death: An important mechanism linking oxidative stress-inducing pathological factors to associated pathological conditions. *Redox Biol.* 2020;37:101755. doi: 10.1016/j.redox.2020.101755.
- Çınar R, Nazıroğlu M. TRPM2 Channel Inhibition Attenuates Amyloid 42-Induced Apoptosis and Oxidative Stress in the Hippocampus of Mice. *Cell Mol Neurobiol.* 2023;43(3):1335-53. doi: 10.1007/s10571-022-01253-0.
- Nakai H, Konno M, Kosuge S, et al. New potent antagonists of leukotrienes C4 and D4. 1. Synthesis and structure-activity relationships. *J Med Chem.* 1988;31(1):84-91. doi: 10.1021/jm00396a013.
- Yazgan B, Yazgan Y. Regulatory role of phospholipase A2 inhibitor in oxidative stress and inflammation induced by an experimental mouse migraine model. *J Cell Neurosci Oxid Stress.* 2023;15(2):1147-56. doi: 10.37212/jcnos.1365512.
- Hassan MQ, Akhtar MS, Afzal O, et al. Edaravone and benidipine protect myocardial damage by regulating mitochondrial stress, apoptosis signalling and cardiac biomarkers against doxorubicin-induced cardiotoxicity. *Clin Exp Hypertens.* 2020;42(5):381-92. doi: 10.1080/10641963.2019.1676770.
- Cengiz O, Baran M, Balcioglu E, et al. Use of selenium to ameliorate doxorubicin induced hepatotoxicity by targeting pro-inflammatory cytokines. *Biotech Histochem.* 2021;96(1):67-75. doi: 10.1080/10520295.2020.1760353.
- Cakir M, Duzova H, Tekin S, et al. ACA, an inhibitor phospholipases A2 and transient receptor potential melastatin-2 channels, attenuates okadaic acid induced neurodegeneration in rats. *Life Sci.* 2017;176:10-20. doi: 10.1016/j.lfs.2017.03.022.
- Uçar B, Huyut Z, Altında F, et al. Relationship with nephrotoxicity of Abemaciclib in rats: Protective effect of Curcumin. *Indian J Biochem Biophys.* 2022;59:963-76. doi: 10.56042/ijbb.v59i10.64336.
- Gyulkhasyan T, Hakobyan T, Parikh A, et al. Doxorubicin-induced cardiomyopathy: Prevention and treatment by a coronary specific vasodilator. *The FASEB Journal.* 2019;33(S1):685.14-685.14. doi: 10.1096/fasebj.2019.33.1\_supplement.685.14.
- Ahsan U, Kamran Z, Raza I, et al. Role of selenium in male reproduction—A review. *Anim Reprod Sci.* 2014;146(1-2):55-62. doi: 10.1016/j.anireprosci.2014.01.009.
- Kheradpezhoh E, Ma L, Morphet A, et al. TRPM2 channels mediate acetaminophen-induced liver damage. *Proc Natl Acad Sci U S A.* 2014;111(8):3176-81. doi: 10.1073/pnas.1322657111.
- Singla S, Kumar NR, Kaur J. In vivo Studies on the Protective Effect of Propolis on Doxorubicin-Induced Toxicity in Liver of Male Rats. *Toxicol Int.* 2014;21(2):191-5. doi: 10.4103/0971-6580.139808.
- Kuzu M, Yıldırım S, Kandemir FM, et al. Protective effect of morin on doxorubicin-induced hepatorenal toxicity in rats. *Chem Biol Interact.* 2019;308:89-100. doi: 10.1016/j.cbi.2019.05.017.
- Wali AF, Rashid S, Rashid SM, et al. Naringenin regulates doxorubicin-induced liver dysfunction: impact on oxidative stress and inflammation. *Plants (Basel).* 2020;9(4):550. doi: 10.3390/plants9040550.
- Bilgic S, Ozgocmen M. The protective effect of misoprostol against doxorubicin induced liver injury. *Biotech Histochem.* 2019;94(8):583-91. doi: 10.1080/10520295.2019.1605457.
- Zhang T, Huang W, Ma Y. Down-regulation of TRPM2 attenuates hepatic ischemia/reperfusion injury through activation of autophagy and inhibition of NLRP3 inflammasome pathway. *Int Immunopharmacol.* 2022;104:108443. doi: 10.1016/j.intimp.2021.108443.
- Shokrzadeh M, Bagheri A, Ghassemi-Barghi N, et al. Doxorubicin and doxorubicin-loaded nanoliposome induce senescence by enhancing oxidative stress, hepatotoxicity, and in vivo genotoxicity in male Wistar rats. *Naunyn Schmiedeberg's Arch Pharmacol.* 2021;394(8):1803-13. doi: 10.1007/s00210-021-02119-w.
- Khan MA, Singh D, Arif A, et al. Protective effect of green synthesized Selenium Nanoparticles against Doxorubicin induced multiple adverse effects in Swiss albino mice. *Life Sci.* 2022;305:120792. doi: 10.1016/j.lfs.2022.120792.
- Belhan S, Özkaraca M, Özdek U, et al. Protective role of chrysin on doxorubicin-induced oxidative stress and DNA damage in rat testes. *Andrologia.* 2020;52(9):e13747. doi: 10.1111/and.13747.