

# Assessment of the Relationship Between Maxillary Sinus Membrane Thickness and Various Anatomical Factors Before Implant Treatment

Nebiha Gozde Ispir<sup>1</sup>, Zeynep Fatma Zor<sup>2</sup>, Meryem Toraman<sup>1</sup>

<sup>1</sup>Gazi University, Faculty of Dentistry Department of Dentomaxillofacial Radiology, Ankara, Türkiye.

<sup>2</sup>Gazi University, Faculty of Dentistry, Department of Oral and Maxillofacial Surgery, Ankara, Türkiye.

**Correspondence Author:** Nebiha Gözde Ispir

**E-mail:** ngozdeispir@gazi.edu.tr

**Received:** 07.06.2024

**Accepted:** 27.11.2024

## ABSTRACT

**Objective:** This study aimed to evaluate the maxillary sinus mucosal thickness (MSMT) and factors that may affect this thickness in individuals with a posterior edentulous region.

**Methods:** Cone beam computed tomography (CBCT) images of 130 patients with edentulous posterior maxilla were retrospectively examined. MSMT was measured. The relationship between MSMT and age, gender, residual alveolar bone length/width, nasal septum deviation angle, ostium obstruction, and pneumatization were examined. Descriptive statistics, nonparametric tests, Spearman correlation, and chi-square analyses were used. The significance level was set at .05.

**Results:** The study included 130 maxillary sinuses. Pathological mucosal thickening was present in 67 (51.5%) of maxillary sinuses. Mucosal thickness was significantly thicker in the presence of maxillary sinus ostium obstruction, in the presence of pneumatization and in males. No statistically significant differences were found between nasal septum deviation angle groups.

**Conclusion:** MSMT is affected by gender, the alveolar bone length, maxillary sinus ostium obstruction, and pneumatization as results of this study. When planning implant treatment, these factors that will affect the MSMT should be considered for the success of the treatment, and the planning should be done together by the oral and maxillofacial surgeon and the dentomaxillofacial radiologist.

**Keywords:** Cone beam computed tomography, implant, maxillary sinus mucosal thickness

## 1. INTRODUCTION

Implant treatment is a preferred method to replace the missing tooth. In the posterior maxilla, resorption is observed after tooth loss, leading to progressive sinus pneumatization and a decrease in the alveolar ridge in the cranial direction (1). After this resorption, maxillary sinus floor augmentation (MSFA) is performed in cases where the existing bone is insufficient for implant treatment. However, some complications related to MSFA may occur. One of the most common complications during the MSFA is sinus membrane perforation, with 0–60% incidence (2,3). The main risk factors causing sinus membrane perforation are the presence of septa in the sinus, differences in sinus morphology (angle of sinus walls), sinus membrane thickness, and application errors during osteotomy or membrane elevation (4). In a previous study, it was reported that one of these risk factors, sinus membrane thickness less than 0.8 mm or more than 3 mm, significantly increased the risk of perforation and caused an increase in postoperative inflammation (5). Another previous study

stated that sinus membrane thickness outside the range of 1–2 mm significantly increased the risk of perforation (6). In this context, measuring the MSMT and the size of the existing bone before the surgical procedure for implant placement and detailed evaluation of the pathologies and anatomical structures that will affect the membrane thickness is essential for the success of the treatment.

Situations where the sinus membrane is greater than the physiological thickness limit are referred to as increased mucosal thickening. Different physiological mucosal thicknesses have been mentioned in many previous studies (6–9). However, a mucosal thickness of 2 mm is considered a reliable threshold, and when it is more than 2 mm, it is classified as pathological/increase in thickening in recent studies (2,8,10). Increase in sinus membrane thickness; it may be associated with various pathological conditions such as rhinosinusitis, pseudocyst, retention cyst, mucocele, allergy, and odontogenic infections (11). In addition, some

studies show that there may be a correlation between sinus membrane thickness, obstructed sinus ostium (12), and the height of the residual alveolar crest (13). Another study stated that it could not find a relationship between residual bone and MSMT (6). The relationship between nasal septum deviation and maxillary sinus mucosa thickening has been a matter of debate in the literature. While a study by Bayrak et al. (14) emphasizes that there is no relationship, another study by Munakata et al. (2) argues that there is a relationship.

Cone beam computed tomography (CBCT) is the most reliable 3D imaging method used for treatment planning before implant treatment. In CBCT images, the alveolar bone, as well as the maxillary sinus, can be visualized, and the anatomy and pathologies of the maxillary sinus can be evaluated (15). To reduce the risk of infection and obtain good clinical results during sinus lifting, the maxillary sinus membrane should be evaluated in detail on CBCT.

In this study, MSMT was examined in patients who were planned to receive implant treatment in the maxillary posterior edentulous area in order to evaluate the correct patient selection, accurate surgical-prosthetic planning, and possible complications before the operation.

In addition, the relationship between membrane thickness and bone height in the relevant region, bone width, maxillary sinus ostium obstruction, maxillary sinus pneumatization, maxillary sinus septum, and nasal septum deviation angle were evaluated.

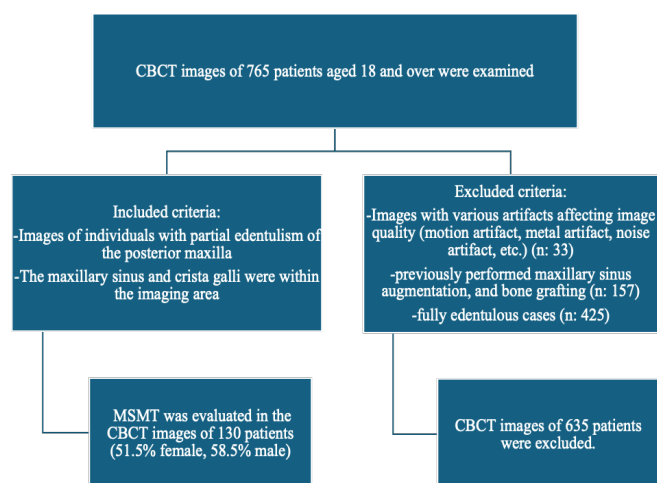
## 2. METHODS

Ethics committee approval was obtained before starting the study (Research No: 2022-1069).

G\* Power package program (G\* Power ver. 3.0.10, Franz Faul, Universität Kiel, Germany, <http://www.psych.unidusseldorf.de/aap/projects/gpower>) was used to determine the minimum number of individuals to be included in the study. The calculation of our sample size is based on the assumption that certain anatomical factors, which form the basis of the present study, may influence maxillary sinus mucosal thickness. Given the descriptive nature of the present study, our focus is specifically on estimating the relationship between the maxillary sinus mucosal thickness of individuals and these identified anatomical factors. To increase the accuracy of our estimates and ensure the reliability of the results, we used a margin of error ( $\alpha$ ) = .05, effect size  $f$  = .30, and test power ( $1-\beta$ ) = .80. As a result of the calculations, the sample size that would provide the power of the test ( $1-\beta$ )=.80 was determined as 128. The width of the confidence interval was determined in accordance with the objectives of the present study and the chosen analytical methods and will contribute to the assessment of the significance of the data obtained.

The CBCT images of 765 patients aged 18 and over who applied to our Faculty of Dentistry, Department of Oral and Dentomaxillofacial Surgery for implants between 2017 and

2018 examined in this retrospective study. All the CBCT images obtained from the maxillofacial region (Field of View (FOV) 16.0 cm × 9.2 cm) or maxilla (FOV: 16.0 × 5.2 cm) were examined using the Planmeca Promax 3D-Mid (Planmeca, Helsinki, Finland) device with the parameters 90 kVp, eight mA, 13.5 seconds exposure time and 400  $\mu$ m voxel size. Among the CBCT images examined, images of partially edentulous individuals, in whom at least one of the premolar and molar teeth in the posterior maxilla was missing, were included in the study. Care was taken to ensure the maxillary sinus and crista galli were within the imaging area. Images with various artifacts affecting image quality (motion artifact, metal artifact, noise artifact, etc.) (n: 53), previously maxillary sinus augmentation (n:157), bone grafting, and fully edentulous cases (n: 425) were excluded from the study. In line with these criteria, MSMT was evaluated unilaterally in the CBCT images of 130 patients (51.5% female, 58.5% male) with an average age of 55.3 ± 10.7 years.



All the CBCT images were examined in sagittal, coronal, and axial sections. The radiographic evaluations were performed by a radiologist with at least seven years of experience in the Department of Dentomaxillofacial Radiology. All images were analyzed in a light-reduced environment, on a medical monitor with a 24-inch screen with ideal resolution, from a distance of approximately 50 cm, using the measurement function in Planmeca Romexis 4.6.2.R, the original program of the device.

The presence/absence of maxillary sinus mucosal thickening was assessed unilaterally on images of the posterior edentulous region of the maxilla where the implant was planned, and its extent was measured from the widest area in the sagittal section (16). Pathological mucosal thickening was considered to be present when the MSMT was more than 2 mm (2).

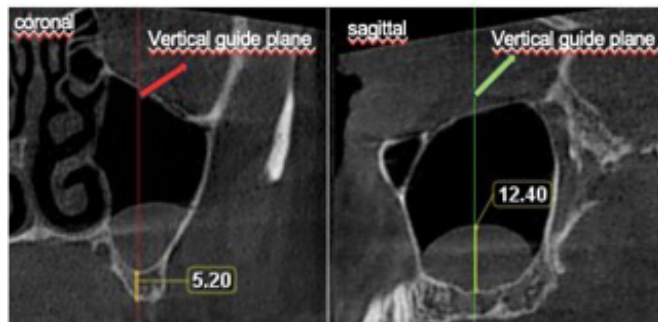
The alveolar bone size was measured from the coronal section. The measurement in the coronal section was made from the part corresponding to the region with the highest mucosal thickening in the sagittal section. A vertical guide plane was used to determine this region in the coronal section

**Table 1.** Maxillary sinus mucosa thickness according to gender

		Gender						Mann Whitney U Test		
		n	Mean	Median	Minimum	Maximum	sd	Mean rank	U	p
Maxillary sinus mucosal thickness (mm)	Female	67	4	2	0	16	4	58.74	1657.5	.03*
	Male	63	7	2	0	31	9	72.69		
	Total	130	5	2	0	31	7			

\*p< .05

(Figure 1). The bone width was measured at the widest point closest to the ridge top in the determined coronal section.

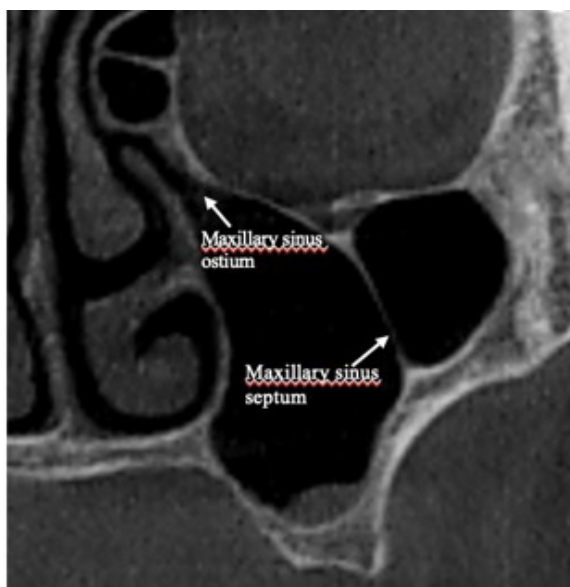


**Figure 1.** CBCT sagittal section showing the region with the highest mucosal thickening, and mucosal thickness measurement. Measurement of alveolar bone length in CBCT coronal section. The vertical guide plane used to determine the area to be measured in the coronal section is visible in both sections.

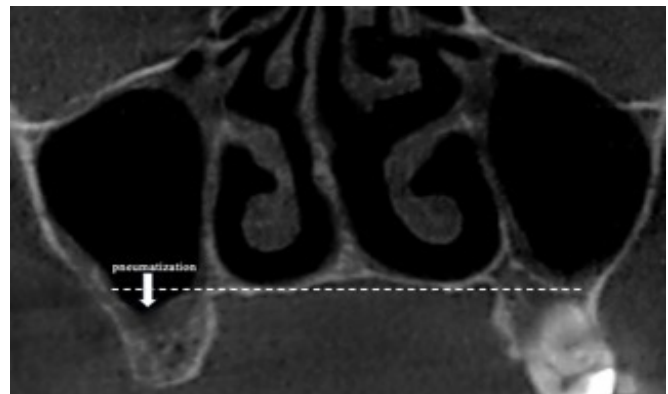
**Table 2.** Correlation between alveolar bone length/width and maxillary sinus mucosal thickness

		Alveolar bone length (mm)	Alveolar bone width (mm)
Maxillary sinus mucosal thickness (mm)	r	-0.17*	-0.13
	p	.04*	.12
	n	130	130

\*p< .05



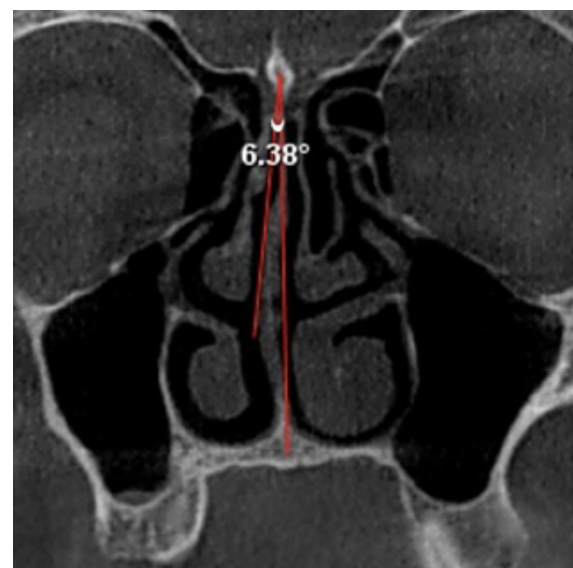
**Figure 2.** CBCT coronal section showing ostium of the maxillary sinus and septa of the maxillary sinus



**Figure 3.** CBCT coronal section showing maxillary sinus pneumatization

The presence/absence of ostium obstruction of the relevant maxillary sinus, the presence/absence of septa of the maxillary sinus, and maxillary sinus pneumatization were evaluated (Figure 2-3).

The nasal septum deviation angle is the angle made by the line between crista galli and spina nasalis anterior (point projection on the horizontal plate of the maxillary or palatine bone) on the coronal section with the line between crista galli and the most lateral part of the nasal septum (2). The angle was determined by measuring in the coronal section (Figure 4). According to the measured angle, individuals were classified as mild < 9°, 9° ≤ moderate < 15°, and severe ≥ 15° (17).



**Figure 4.** Measurement of nasal septum deviation angle in CBCT coronal section.

The data obtained from the study were analyzed through the SPSS v.22 package program (IBM, Chicago, IL, USA). Since the data were not normally distributed, the Mann-Whitney U test was used for comparisons between two groups, and the Kruskal Wallis H test was used for comparisons between three or more groups. Spearman correlation analysis was used for relationships between variables. The relationship between categorical data was examined with Chi-Square analysis.

A descriptive statistical method (Mean, Median, Standard Deviation, Minimum-Maximum) was used when evaluating the study data.

In the study, .05 was used as the significance level, and if  $p < .05$ , it was stated that there was a significant difference/relationship, and if  $p > .05$ , it was stated that there was no significant difference/relationship.

### 3. RESULTS

The study included 130 patients (51.5% female, 58.5% male, with an average age of  $55.3 \pm 10.7$  years) and 130 maxillary sinuses. It was observed that 61 (46.9%) of the maxillary sinuses were on the right, and 69 (33.1%) were on the left. Pathological mucosal thickening was present in 67 (51.5%) of 130 maxillary sinuses. There was pathological mucosal thickening in 35 (57.4%) of the right maxillary sinus and 31 (44.9%) of the left maxillary sinus.

The average MSMT was  $5 \pm 7$  mm, and the median was 2 mm. Mucosal thickness was maximum 31 mm and minimum zero. There was a statistically significant difference in MSMT between genders ( $p < .05$ ). MSMT was significantly higher in males than in females (Table 1). There was no statistically significant relationship between age and MSMT values ( $p > .05$ ).

There was a negative and significant relationship between the amount of MSMT and bone length ( $r = -.174$ ;  $p < .05$ ). Accordingly, as MSMT increases, alveolar bone length decreases. There was no statistically significant relationship between MSMT and alveolar bone widths ( $p > .05$ ) (Figure 5) (Table 2). However, as the amount of mucosal thickness increased, bone width decreased.

A significant difference was found between the presence of pneumatization in terms of the amount of MSMT. The maxillary sinus mucosa thickness in the maxillary sinus with pneumatization was statistically significantly thicker than in those without ( $p < .05$ ) (Table 3).

A significant difference was observed between the ostium obstruction conditions regarding mucosal thickness amount (mm) ( $p < .05$ ). MSMT was significantly greater in maxillary sinuses with ostium obstruction than those without (Table 4).

There was no statistically significant difference between the presence/absence of maxillary sinus septum in terms of maxillary sinus mucosa thickness ( $p > .05$ ).

**Table 3.** Maxillary sinus mucosa thickness according to pneumatization

		Pneumatization						Mann Whitney U Test		
		n	Mean	Median	Minimum	Maximum	sd	Mean rank	U	p
Maxillary sinus mucosal thickness (mm)	Absence	54	3	2	0	16	4	53.74	1417	.003*
	Presence	76	7	4	0	31	8	73.86		
	Total	130	5	2	0	31	7			

\* $p < .05$

**Table 4.** Maxillary sinus mucosa thickness according to ostium obstruction

		Ostium obstruction						Mann Whitney U Test		
		n	Mean	Median	Minimum	Maximum	sd	Mean rank	U	p
Maxillary sinus mucosal thickness (mm)	Absence	113	4	2	0	24	5	59.31	261	.0001*
	Presence	17	16	14	0	31	11	106.65		
	Total	130	5	2	0	31	7			

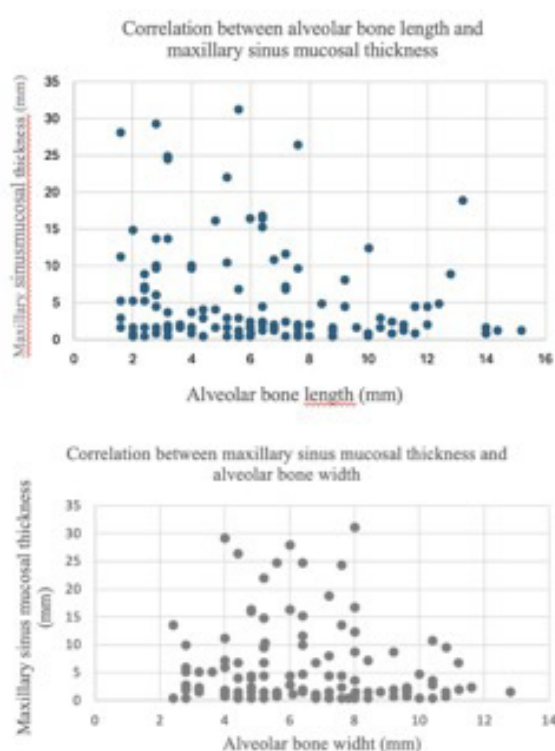
\* $p < .05$

**Table 5.** Maxillary sinus mucosa thickness according to nasal septum deviation angle

		Nasal Septum Deviation Angle						Kruskal Wallis H Test		
		n	Mean	Median	Minimum	Maximum	sd	Mean rank	H	p
Maxillary sinus mucosal thickness (mm)	Group 1	82	5	2	0	29	6	61.31	4.748	.093
	Group 2	43	6	3	0	31	7	70.06		
	Group 3	5	16	22	0	28	13	95.00		
	Total	130	5	2	0	31	7			

\* $p < .05$

The number of patients in the groups according to the severity of nasal septum deviation was as follows: mild 82, moderate 43, and severe 5. There was no statistically significant difference in maxillary sinus mucosa thickness between groups classified according to nasal deviation severity ( $p > .05$ ). Although not statistically significant, it was found in our study that the maxillary sinus mucosa thickness was higher in the severe (Table 5).



**Figure 5.** Correlation between alveolar bone length/width and maxillary sinus mucosal thickness

#### 4. DISCUSSION

Perforation in the maxillary sinus membrane may reduce the chance of success in implant treatment and cause various symptoms in the patient. Therefore, it is important to evaluate MSMT when planning implant treatment in the posterior maxilla region. is essential when planning implant treatment in the posterior maxilla region.

Computed tomography and magnetic resonance imaging are essential for the evaluation of the maxillary sinus because they provide multiple sections through the sinuses in different planes (18). However, it has recently been shown that CBCT can also be used in the evaluation of the maxillary sinus (19). While CBCT has advantages such as lower radiation dose and faster speed compared to computed tomography, it has advantages compared to magnetic resonance imaging, such as lower cost. Additionally, CBCT is the preferred 3D imaging method in implant treatment planning. (18). Therefore, the CBCT images were preferred to evaluate MSMT for our study.

Previous studies have no consensus on how much physiological thickness of the sinus membrane should be. Eggesbo et al. (20), Cakur et al. (21), and Kalyvas et al. (7) accepted that the sinus membrane thickens when its physiological thickness is 4 mm or more. Lozano-Carrascal et al. (9) stated this limit of physiological membrane thickness as 3 mm. In their study, Cagici et al. (22), Shanbhag et al. (23) and Janner et al. (8) reported that the sinus anatomy was affected when the maxillary sinus mucosa thickness was more than 2 mm, and they accepted this value as pathological mucosal thickness. In recent similar studies, a maxillary sinus mucosal thickness of more than 2 mm was evaluated as pathological/the increase of mucosal thickness (2,10). Differences in opinion regarding physiological mucosal thickness may arise from differences in race and ethnicity. In addition, when clinical and radiographic findings are evaluated together, it has been stated that some of the causes of pathological thickening may also present an asymptomatic (10). Ignoring this situation may have caused the physiological mucosal thickness to be determined as thicker in some studies. Therefore, in the present study, pathological MSMT was evaluated as more than 2 mm. With this, the increase of mucosal thickness was present in 51,5% of the maxillary sinuses. In previous studies, this rate varies between 25% and 53.6% (2,7,12,24). The reason for this difference between studies may be due to different populations. Additionally, in some studies, dentulous regions were evaluated, while in others, edentulous regions were considered. In the study conducted by Dursun et al. (25), it was emphasized that the increase of mucosal thickness was higher in edentulous regions than in the dentulous regions. However, we think more studies need to be done on this subject.

Guo et al. (26) reported the MSMT value as  $1.93 \pm 2$  mm. Lin et al. (6) and Lozano-Carrascal et al. (9) were found this value as  $1.32 \pm 0.87$  and  $1.82 \pm 1.59$  mm in their CBCT study, respectively. In other studies conducted for this purpose, Yildirim et al. (27) declared it as  $4.19 \pm 5.84$ , Kalyvas et al. (7) found this value to be  $1.60 \pm 1.20$  mm and Munakata et al. (2) reported it as  $1.09 \pm 1.30$  mm. MSMT was measured as  $5 \pm 7$  mm in the present study. The reason why the sinus mucosa thickness was relatively higher in this study compared to other studies may be due to the examination of areas where there were no teeth and the inclusion of maxillary sinus diseases that cause mucosal thickening in the maxillary sinus (except for those that cause bone destruction).

Although the amount of MSMT that causes perforation during implant treatment was known in studies, there are few studies on the factors that may affect this thickness in edentulous areas (2). Therefore, in the present study, in addition to age and gender, the relationship between alveolar bone length and width, presence of pneumatization, maxillary sinus ostium obstruction, maxillary sinus septum, and nasal septum deviation were examined.

There are many studies in the literature examining the relationship of MSMT with gender and age (2,7,8,21,28). In these studies, when the maxillary sinus mucosa thickness

was evaluated in terms of gender, it was found to be thicker in males than in females (2,7,8,21). Kalyvas et al. argued that the age factor did not affect the anatomical features of the sinus (7). In a meta-analysis study by Monje et al., it was stated that age did not affect MSMT (28). Munakata and colleagues found that there was an increase in sinus mucosa thickness with age, but there was no statistical correlation between the two data in another meta-analysis study (2). Findings regarding age and gender in the present study are consistent with these previous studies.

Although there were several studies on residual alveolar crest length with MSMT, to our knowledge, no previous study has examined the relationship between alveolar bone width and sinus mucosa thickness. In addition, it has been reported in many studies that there is no relationship between alveolar bone length in edentulous areas and maxillary sinus mucosa thickness (2,29). It was also stated that MSMT showed a positive correlation with alveolar ridge size in those with a residual ridge height of less than 3.5 mm in another study (30). The present study revealed that as the maxillary sinus mucosa thickness increased, the alveolar bone length decreased statistically significantly, and the maxillary sinus mucosa thickness increased as the bone width decreased, this was not statistically significant. The reason for these differences between the studies may be related to different populations, reasons for tooth extraction and the process after extraction and the presence of prosthesis used in this process. It may also be related to the determination of alveolar crest length using a vertical reference plane in our study. We believe that the use of the vertical reference plane prevented random measurements and introduced an innovative approach for the measurement method. In addition, since this was a retrospective study based on the imaging archive, the reasons for tooth extraction, the process after extraction and the presence of prosthesis used in this process were not known.

There were very few studies in the literature examining the relationship between MSMT and the presence of pneumatization. A previous study showed that there was no relationship between pneumatization and mucosal membrane thickness (31). The reason for the inconsistency with our study may be related to the evaluation of the maxillary sinus in the edentulous region in our study. Remodeling of the alveolar crest after tooth extraction in the posterior maxilla may trigger growth in the maxillary sinus and cause pneumatization (32). Another previous study has shown that there was a risk of sinus membrane perforation in cases where the membrane thickness was above the pathological limit (5). Considering the results of this study (5) and the finding in the present study that the membrane thickness was statistically significantly thicker in the presence of pneumatization in the maxillary sinus, the presence of pneumatization may cause thickening of the sinus membrane and, therefore, perforation during implant treatment. However, more studies are needed on this topic.

Previous studies have reported that mucosal thickness was thicker in with ostium obstruction presence than without, which is consistent with the present study (12,33). The maxillary sinus ostium provides the passageway for the mucosa released from the mucociliary cells lining the maxillary sinus into the nasal cavity (33). Maxillary sinus ostium obstruction occurring for various reasons may cause mucus retention, maxillary sinus mucosal thickening, and rhinosinusitis (33,34). Rhinosinusitis negatively affects the chances of success of implant surgery (35). Generally, after implant surgery and sinus augmentation, facial pain or pressure on the treated side, nasal congestion, thick purulent discharge and foul odor, and oroantral fistula may occur (33). For this reason, ostium obstruction should also be evaluated in the presence of mucosal thickening on CBCT taken during implant treatment planning. In the presence of ostium obstruction, the patient should be consulted to the otolaryngology department before implant surgery.

There are few studies examining the relationship between MSMT and the presence of septa in the sinus. Munakata et al. (2) showed that they could not find a relationship between the presence and absence of septa in individuals with MSMT more than 2 mm. Our study is consistent with the previous study. In their computed tomography (CT) study, Iizuka et al. (36) found that the presence of maxillary sinus septa was associated with the presence of mucosal thickening. On the other hand, there were also CBCT studies reporting a negative correlation between MSMT and the presence of septa (21,37). Discrepancies between studies and the present study may result from differences in study methodology and differences in the population.

Bayrak et al. (14) reported that there was no correlation between nasal septum deviation and maxillary sinus mucosa thickness. Taghiloo and Halimi (38) evaluated the MSMT in their CBCT study by classifying nasal septum deviation according to its type. The study stated that there was no difference between the type of nasal septum deviation and maxillary sinus mucosa thickness (38). In the present study, nasal septum deviation angle was divided into three groups to examine the relationship between maxillary sinus mucosa thickness and the severity of nasal septum deviation angle. There was no statistically significant difference in maxillary sinus mucosa thickness between groups classified according to nasal deviation severity. However, the maxillary sinus mucosa thickness was greater in the group with severe nasal septum deviation angle than in the other groups. Contrary to these studies, one study concluded that there was a relationship between nasal deviation angle and maxillary sinus mucosa thickness (2). Considering that the deviation seen in the nasal septum, a part of the osteomeatal complex, is a pathological condition, more studies are needed to evaluate the relationship between maxillary sinus mucosa thickness and nasal septum deviation.

## 5. CONCLUSION

The amount of maxillary sinus mucosa thickness is important in terms of the risk of perforation that may occur in the membrane during implant treatment and sinus augmentation. According to the results of this study, maxillary sinus mucosa thickness is affected by gender, the alveolar bone length, maxillary sinus ostium obstruction, and the presence of maxillary sinus pneumatization. When planning implant treatment, these factors that will affect the maxillary sinus mucosa thickness should be taken into consideration, and planning should be made together by the oral and maxillofacial surgeon and the dentomaxillofacial radiologist. However, clinical studies that can compare before and after implant treatment should be conducted to evaluate the implications of the findings on implant treatment success.

**Acknowledgements:** We would like to thank Gazi University Academic Writing, Research and Application Center for grammar editing.

**Funding:** The author(s) received no financial support for the research.

**Conflicts of interest:** The authors declare that they have no conflict of interest.

**Ethics Committee Approval:** This study was approved by Ethics Committee of Gazi University University, Noninvasive Clinic Ethics Committee (Approval date: 2022; Number:1069)

**Peer-review:** Externally peer-reviewed.

### Author Contributions:

Research idea: NGI, ZFZ, MT

Design of the study: NGI, ZFZ, MT

Acquisition of data for the study: NGI

Analysis of data for the study: NGI, ZFZ, MT

Interpretation of data for the study: NGI, ZFZ, MT

Drafting the manuscript: NGI, ZFZ, MT

Revising it critically for important intellectual content: NGI, ZFZ, MT

Final approval of the version to be published: NGI, ZFZ, MT

## REFERENCES

- [1] Chan HL, Wang HL. Sinus pathology and anatomy in relation to complications in lateral window sinus augmentation. *Implant Dentistry* 2011;20(6):406-412.
- [2] Munakata M, Yamaguchi K, Sato D, Yajima N, Tachikawa N. Factors influencing the sinus membrane thickness in edentulous regions: A cone-beam computed tomography study. *Int J Implant Dent*. 2021;7(1):16. DOI: 10.1186/s40729.021.00298-y
- [3] Díaz Olivares LA, Cortés Bretón Brinkmann J, Martínez Rodríguez N, Martínez González JM, López Quiles J, Leco Berrocal I, Meniz García C. Management of Schneiderian membrane perforations during maxillary sinus floor augmentation with lateral approach in relation to subsequent implant survival rates: A systematic review and meta-analysis. *Int J Implant Dent*. 2021;7(1):91. DOI: 10.1186/s40729.021.00346-7.
- [4] Karaca EÖ, Gürsoy H, Tunar OL. Sinus ogmentasyon komplikasyonları ve tedavi önerileri. *7tepeklilik* 2016; 12: 53-62. DOI: 10.5505/yeditepe.2016.03511 (Turkish)
- [5] Testori T, Yu SH, Tavelli L, Wang HL. Perforation Risk Assessment in maxillary sinus augmentation with lateral wall technique. *International Journal of Periodontics & Restorative Dentistry* 2020;40(3): 373-380.
- [6] Lin YH, Yang YC, Wen SC, Wang HL. The influence of sinus membrane thickness upon membrane perforation during lateral window sinus augmentation. *Clinical oral implants research* 2016;27(5):612-617.
- [7] Kalyvas D, Kapsalas A, Paikou S, Tsiklakis K. Thickness of the Schneiderian membrane and its correlation with anatomical structures and demographic parameters using CBCT tomography: A retrospective study. *International Journal of Implant Dentistry* 2018;4(1):1-8.
- [8] Janner SF, Caversaccio MD, Dubach P, Sendi P, Buser D, Bornstein MM. Characteristics and dimensions of the Schneiderian membrane: A radiographic analysis using cone beam computed tomography in patients referred for dental implant surgery in the posterior maxilla. *Clin Oral Implants Res*. 2011;22(12):1446-1453. DOI: 10.1111/j.1600-0501.2010.02140.x
- [9] Lozano Carrascal N, Salomó Coll O, Gehrke SA, Calvo Guirado JL, Hernández Alfaro F, Gargallo Albiol J. Radiological evaluation of maxillary sinus anatomy: A cross-sectional study of 300 patients. *Ann Anat*. 2017;214:1-8. DOI: 10.1016/j.aanat.2017.06.002
- [10] Aboelmaaty W, Alfadley A, Awawdeh M, Sapri AS, Awawdeh L, Mira ES. Utilizing a novel AI tool to detect the posterior superior alveolar artery's location's impact on maxillary sinus mucosal thickening in the presence of periapical lesions. *Medicina (Kaunas)* 2024;60(1):140. DOI: 10.3390/medicina60010140
- [11] Peñarrocha Oltra S, Soto Peñaloza D, Bagán Debón L, Bagan JV, Peñarrocha Oltra D. Association between maxillary sinus pathology and odontogenic lesions in patients evaluated by cone beam computed tomography. A systematic review and meta-analysis. *Med Oral Patol Oral Cir Bucal*. 2020;25(1):e34-e48. DOI: 10.4317/medoral.23172
- [12] Shanbhag S, Karnik P, Shirke P, Shanbhag V. Cone-beam computed tomographic analysis of sinus membrane thickness, ostium patency, and residual ridge heights in the posterior maxilla: Implications for sinus floor elevation. *Clinical Oral Implants Research* 2014;25(6):755-760.
- [13] Akbari S, Taheri M, Aslroosta H, Ordoukhani A, Paknejad M, Hashemi F, Farimani Z. Relationship of maxillary sinus mucosal thickening and residual alveolar ridge height: A CBCT analysis. *Front Dent*. 2022;19:19. DOI: 10.18502/ffd.v19i19.9965
- [14] Bayrak S, Ustaoglu G, Demiralp KÖ, Çakmak ESK. Evaluation of the characteristics and association between schneiderian membrane thickness and nasal septum deviation. *Journal of Craniofacial Surgery* 2018;29(3):683-687.
- [15] Cakli H, Cingi C, Ay Y, Oghan F, Ozer T, Kaya E. Use of cone beam computed tomography in otolaryngologic treatments. *European Archives of Oto-Rhino-Laryngology* 2012;269:711-720.
- [16] Maska B, Lin GH, Othman A, Behdin S, Travan S, Benavides E, Kapila Y. Dental implants and grafting success remain high despite large variations in maxillary sinus mucosal thickening. *International Journal of Implant Dentistry* 2017;3(1):1-8.
- [17] Elahi MM, Frenkiel S, Fageeh N. Paraseptal structural changes and chronic sinus disease in relation to the deviated septum. *The Journal of Otolaryngology* 1997;26(4):236-240.
- [18] Mallya S, Lam E. White and Pharoah's Oral radiology E-book: Principles and interpretation. Second South Asia Edition E-Book: Elsevier India; 2019.

- [19] Yeung AWK, Hung KF, Li DTS, Leung YY. The use of cbct in evaluating the health and pathology of the maxillary sinus. *Diagnostics* 2022;12(11):2819.
- [20] Eggesbø H. Radiological imaging of inflammatory lesions in the nasal cavity and paranasal sinuses. *European Radiology* 2006;16(4):872-888.
- [21] Çakur B, Sümbüllü MA, Durna D. Relationship among schneiderian membrane, underwood's septa, and the maxillary sinus inferior border. *Clinical Implant Dentistry and Related Research* 2013;15(1):83-87.
- [22] Cagici CA, Yilmazer C, Hurcan C, Ozer C, Ozer F. Appropriate interslice gap for screening coronal paranasal sinus tomography for mucosal thickening. *Eur Arch Otorhinolaryngol.* 2009;266(4):519-525. DOI: 10.1007/s00405.008.0786-6
- [23] Shanbhag S, Shanbhag V, Stavropoulos A. Volume changes of maxillary sinus augmentations over time: A systematic review. *International Journal of Oral & Maxillofacial Implants* 2014;29(4):881-892.
- [24] Zhang B, Wei Y, Cao J, Xu T, Zhen M, Yang G, Chung KH, Hu.W. Association between the dimensions of the maxillary sinus membrane and molar periodontal status: A retrospective CBCT study. *J Periodontol.* 2020;91(11):1429-1435. DOI: 10.1002/jper.19-0391.
- [25] Dursun E, Keceli HG, Dolgun A, Velasco-Torres M, Olculer M, Ghoreishi R, Sinjab K, Sinacola R A, Kubilius M, Tözüm MD, Galindo MP, Yilmaz HG, Wang HL, Juodzbalys G, Tözüm TF. Maxillary sinus and surrounding bone anatomy with cone beam computed tomography after multiple teeth loss: A retrospective multicenter clinical study. *Implant Dent.* 2019;28(3):226-236. DOI: 10.1097/id.000.000.0000000862
- [26] Guo ZZ, Liu Y, Qin L, Song YL, Xie C, Li DH. Longitudinal response of membrane thickness and ostium patency following sinus floor elevation: A prospective cohort study. *Clinical Oral Implants Research* 2016;27(6):724-729.
- [27] Yildirim TT, Güncü GN, Göksülük D, Tözüm MD, Colak M, Tözüm TF. The effect of demographic and disease variables on Schneiderian membrane thickness and appearance. *Oral Surgery, Oral Medicine, Oral Pathology and Oral Radiology* 2017;124(6):568-576.
- [28] Monje A, Diaz KT, Aranda L, Insua A, Garcia-Nogales A, Wang HL. Schneiderian membrane thickness and clinical implications for sinus augmentation: A systematic review and meta-regression analyses. *J Periodontol.* 2016;87(8):888-899. DOI: 10.1902/jop.2016.160041
- [29] Ramanauskaite A, Ataman Duruel ET, Duruel O, Tözüm MD, Yildirim TT, Tözüm TF. Effects of clinical local factors on thickness and morphology of Schneiderian membrane: A retrospective clinical study. *Clinical Implant Dentistry and Related Research* 2019;21(4):715-722.
- [30] Yilmaz HG, Tözüm TF. Are gingival phenotype, residual ridge height, and membrane thickness critical for the perforation of maxillary sinus? *Journal of Periodontology* 2012;83(4):420-425.
- [31] Kıpçak ÖA. Maksiller Sinüs patolojilerinin ve schneider membran değişikliklerinin odontojenik faktörlerle ilişkisinin konik ışıklı bilgisayarlı tomografi kullanılarak değerlendirilmesi. *Kocaeli Üniversitesi Sağlık Bilimleri Dergisi*7(3):296-303. (Turkish)
- [32] Lim HC, Kim S, Kim DH, Herr Y, Chung JH, Shin SI. Factors affecting maxillary sinus pneumatization following posterior maxillary tooth extraction. *J Periodontal Implant Sci.* 2021;51(4):285-295. DOI: 10.5051/jpis.200.722.0361
- [33] Carmeli G, Artzi Z, Kozlovsky A, Segev Y, Landsberg R. Antral computerized tomography pre-operative evaluation: Relationship between mucosal thickening and maxillary sinus function. *Clinical Oral Implants Research* 2011;22(1):78-82.
- [34] Alho OP. Nasal airflow, mucociliary clearance, and sinus functioning during viral colds: effects of allergic rhinitis and susceptibility to recurrent sinusitis. *Am J Rhinol.* 2004;18(6):349-355.
- [35] Barone A, Santini S, Sbordone L, Crespi R, Covani U. A clinical study of the outcomes and complications associated with maxillary sinus augmentation. *Int J Oral Maxillofac Implants* 2006;21(1):81-85.
- [36] Norihito I, Yusuke K, Satoshi T, Kotaro I, Yoshinobu H, Naohisa H, Eri S, Keiko S, Takashi K. Forms of maxillary sinus with septa can cause by mucosal thickening of maxillary sinus: Computed tomographic study. *International Journal of Oral-Medical Sciences* 2019;18(1):57-61.
- [37] Sánchez Pérez A, Boracchia AC, López Jornet P, Boix García P. Characterization of the maxillary sinus using cone beam computed tomography. A retrospective radiographic study. *Implant Dentistry* 2016;25(6):762-769.
- [38] Taghiloo H, Halimi Z. The frequencies of different types of nasal septum deviation and their effect on increasing the thickness of maxillary sinus mucosa. *Journal of Dental Research, Dental Clinics, Dental Prospects* 2019;13(3):208.

**How to cite this article:** Ispir NG, Zor ZF, Toroman M. Assessment of the relationship between maxillary sinus membrane thickness and various anatomical factors before implant treatment. *Clin Exp Health Sci* 2024; 14: 1076-1083. DOI: 10.33808/clinexphealthsci.1498706