

Evaluating the efficacy of percutaneous nephrostomy in managing hematuria following antegrade double J ureteral stent placement

Perkütan antegrad çift J üreteral stent yerleştirilmesinin ardından gelişen hematürinin yönetiminde perkütan nefrostominin etkinliğinin değerlendirilmesi

Muhammet Arslan, Halil Serdar Aslan, Burak Kurnaz, Kadir Han Alver, Mahmut Demirci, Mehmet Alpua, Sinan Çelen

Posted date:26.06.2024

Acceptance date:01.07.2024

Abstract

Purpose: This study aims to evaluate the clinical outcomes of percutaneous nephrostomy in patients who develop hematuria during percutaneous antegrade double j stent placement.

Materials and methods: We conducted a multicenter retrospective cross-sectional study, reviewing medical records from January 2016 to June 2024, to identify patients who underwent percutaneous antegrade double j stent placement and developed hematuria. Percutaneous antegrade double j stent and nephrostomy procedures were performed under ultrasound and fluoroscopic guidance.

Results: The study included 151 patients with a mean age of 65.9±15.3 years; 46 (30.5%) were female, and 105 (69.5%) were male. Hematuria was observed in 20 (8.9%) of the 225 antegrade double j stent procedures. Hematuria was significantly more common in patients with benign conditions (35%) compared patients with malignant tumors (9.2%) ($p=0.003$). Postoperative nephrostomy was performed in 118 (52.4%) of the procedures. Among patients who developed hematuria, 11 (55%) received a nephrostomy, compared to 9 (45%) without hematuria, though this difference was not statistically significant ($p=0.811$).

Conclusion: Percutaneous nephrostomy appears to be an effective intervention for managing hematuria in patients undergoing antegrade double j stent placement. However, the study did not find a statistically significant difference in hematuria incidence with nephrostomy placement, indicating the need for further research with larger sample sizes to confirm these findings and optimize postoperative management strategies.

Keywords: Percutaneous, nephrostomy, stents, hematuria.

Arslan M, Aslan HS, Kurnaz B, Han Alver K, Demirci M, Alpua M, Celen S. Evaluating the efficacy of percutaneous nephrostomy in managing hematuria following antegrade double J ureteral stent placement. Pam Med J 2024;17:682-688.

Öz

Amaç: Bu çalışmada perkütan antegrad double j stent yerleştirilmesi sırasında hematüri gelişen hastalarda perkütan nefrostominin klinik sonuçlarının değerlendirilmesi amaçlandı.

Gereç ve yöntem: Perkütanöz antegrad double j stent yerleştirilen ve hematüri gelişen hastaları belirlemek için Ocak 2016'dan Haziran 2024'e kadar tıbbi kayıtları gözden geçiren, çok merkezli, retrospektif, kesitsel bir çalışma gerçekleştirdik. Perkütan antegrad double j stent ve nefrostomi işlemleri ultrason ve floroskopi rehberliğinde gerçekleştirildi.

Bulgular: Çalışmaya yaş ortalaması 65,9±15,3 yıl olan 151 hasta dahil edildi; 46'sı (%30,5) kadın, 105'i (%69,5) erkekti. Yapılan 225 antegrad double j stent işleminin 20'sinde (%8,9) hematüri görüldü. Hematüri malignitesi olmayan hastalarda (%35) malign tümörlü olanlara (%9,2) göre anlamlı olarak daha fazla görüldü ($p=0,003$). İşlemlerin 118'ine (%52,4) postoperatif nefrostomi uygulandı. Hematüri gelişen hastaların 11'ine (%55) nefrostomi uygulanırken, hematürisi olmayan 9 hastaya (%45) rağmen bu fark istatistiksel olarak anlamlı değildi ($p=0,811$).

Muhammet Arslan, Assoc. Prof. Pamukkale University, Medicine Faculty, Radiology Department, Denizli, Türkiye, e-mail: dr.marslan@hotmail.com (<https://orcid.org/0000-0001-5565-0770>) (Corresponding Author)

Halil Serdar Aslan, Asst. Prof. Pamukkale University, Medicine Faculty, Radiology Department, Denizli, Türkiye, e-mail: draslan@outlook.com (<https://orcid.org/0000-0002-5255-8618>)

Burak Kurnaz, M.D. Pamukkale University, Medicine Faculty, Radiology Department, Denizli, Türkiye, e-mail: burakkurnaz94@gmail.com (<https://orcid.org/0000-0002-7670-4501>)

Kadir Han Alver, M.D. Denizli State Hospital, Radiology Clinic, Denizli, Türkiye, e-mail: kadirhanalver@gmail.com (<https://orcid.org/0000-0002-4692-2401>)

Mahmut Demirci, M.D. Denizli State Hospital, Radiology Clinic, Denizli, Türkiye, e-mail: dr.mahmutdemirci@gmail.com (<https://orcid.org/0000-0001-8201-9618>)

Mehmet Alpua, Asst. Prof. Pamukkale University, Medicine Faculty, Internal Medicine Department, Denizli, Türkiye, e-mail: malpua@pau.edu.tr (<https://orcid.org/0000-0002-2359-007X>)

Sinan Çelen, Assoc. Prof. Pamukkale University, Medicine Faculty, Urology Department, Denizli, Türkiye, e-mail: sinanc@pau.edu.tr (<https://orcid.org/0000-0003-4309-2323>)

Sonuç: Perkütan nefrostomi, antegrad double j stent yerleştirilen hastalarda hematürinin tedavisinde etkili bir girişim gibi görülmektedir. Ancak bu çalışma, nefrostomi yerleştirilmesiyle hematüri insidansında istatistiksel olarak anlamlı bir fark bulamadı. Bu da, bulguları doğrulamak ve perioperatif yönetim stratejilerini optimize etmek için daha büyük örneklem boyutlarıyla daha fazla araştırmaya ihtiyaç olduğunu gösteriyor.

Anahtar kelimeler: Perkütan, nefrostomi, stent, hematüri.

Arslan M, Arslan HS, Kurnaz B, Han Alver K, Demirci M, Alpua M, Çelen S. Perkütan antegrad çift J üreteral stent yerleştirilmesinin ardından gelişen hematürinin yönetiminde perkütan nefrostominin etkinliğinin değerlendirilmesi. Pam Tıp Derg 2024;17:682-688.

Introduction

Percutaneous antegrade double J ureteral stent (ADJS) placement is a medical procedure performed to ensure the flow of urine from the kidney to the bladder. This procedure is typically used to treat obstructions or strictures in the ureter and involves placing a stent within the ureter to facilitate urine flow from the kidney to the bladder [1]. However, hematuria (the presence of blood in the urine) can occur in some patients during percutaneous ADJS placement [2].

In this context, percutaneous nephrostomy is considered a potential treatment option for managing hematuria. Percutaneous nephrostomy provides direct drainage of urine from the kidney, allowing the ureter and bladder to rest and aiding in the control of hematuria [3]. Additionally, nephrostomy offers a route for further intervention if complications such as ADJS migration or occlusion arise. However, further research is needed to determine the effectiveness and benefits of percutaneous nephrostomy in patients who develop hematuria.

The aim of this study is to evaluate the clinical outcomes of percutaneous nephrostomy in patients who develop hematuria during

percutaneous ADJS placement. By examining hematuria and its impact on the overall health status of patients, we seek to determine whether percutaneous nephrostomy is a suitable treatment option for these patients. The findings are expected to contribute to clinical decision-making processes regarding the management of hematuria in ADJS practices.

Materials and methods

Study design and patient selection

This article presents a multicenter retrospective cross-sectional study aimed at investigating the clinical outcomes of percutaneous nephrostomy in patients who develop hematuria during percutaneous ADJS placement. Ethical approval was obtained from Pamukkale University Non-Interventional Clinical Research Ethics Committee prior to the commencement of the study.

Medical records from January 2016 to June 2024 were reviewed to identify patients who underwent percutaneous ADJS placement and subsequently developed hematuria. The inclusion and exclusion criteria are demonstrated in Table 1.

Table 1. Inclusion and exclusion criteria

Inclusion criteria	Exclusion criteria
Age 18 years or older Underwent ADJS placement	Patients with pre-existing coagulopathies
	Patients who underwent ureteral balloon angioplasty
	Patients who had undergone prior interventions affecting the urinary tract
	Incomplete medical records

ADJS: Antegrade double J ureteral stent

Percutaneous nephrostomy procedure

Percutaneous ADJS and nephrostomy were performed under ultrasound and fluoroscopic guidance. The procedures involve the insertion of a percutaneous ADJS to ensure direct urine drainage from the kidney, with or without a nephrostomy tube (Figure 1, 2). The indication for nephrostomy placement was persistent or worsening hematuria despite conservative management.

Statistical analysis

Descriptive statistics were used to summarize the baseline characteristics of the study population. Continuous variables were expressed as mean \pm standard deviation (SD) or median, while categorical variables were

presented as frequencies and percentages. The normality of continuous variables was assessed using the Shapiro-Wilk test. The effectiveness of percutaneous nephrostomy was assessed using chi-square tests for categorical variables. A p -value of <0.05 was considered statistically significant. Statistical analyses were performed using SPSS software version 25.0 (IBM Corp., Armonk, NY, USA).

Results

In this study, we evaluated the relationship between postoperative nephrostomy and the presence of hematuria in patients who underwent antegrade double J stent (ADJS) placement. The descriptive statistics and comparisons based on the presence of hematuria are presented in Table 2.

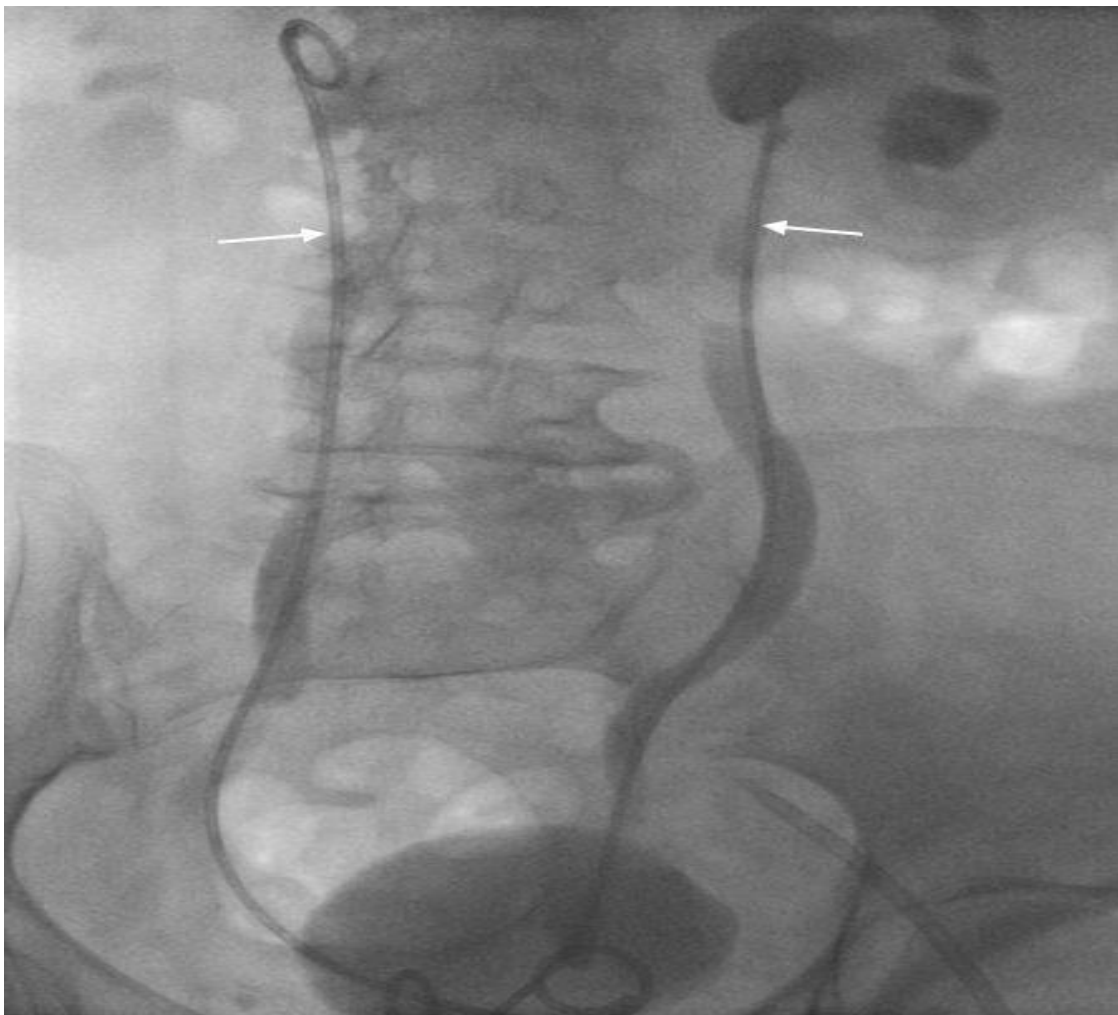

Figure 1. Antegrade double J stent placement (white arrow) into the ureter without a nephrostomy catheter

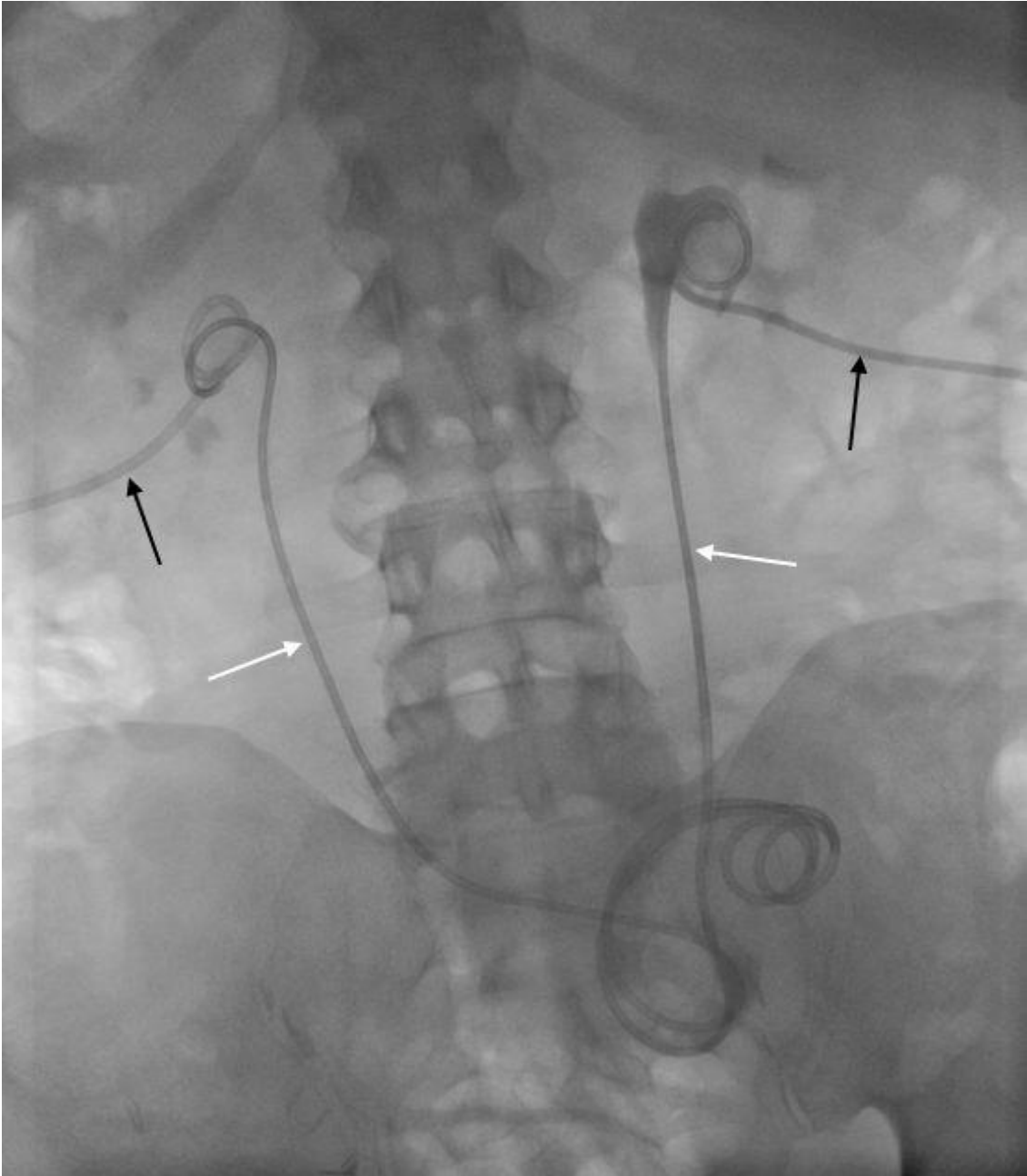


Figure 2. Antegrade double J stent placement (white arrow) into the ureter with a nephrostomy catheter (black arrow)

Table 2. Descriptive statistics of patients with a Double J catheter and comparisons based on the presence of hematuria

	Overall (n=151) a	Hematuria		p	Chi-square Test
		(+) (n=20)	(-) (n=205)		
Age †	65.9±15.3				
Gender ‡					
Female	46 (30.5)				
Male	105 (69.5)				
	Overall (n=225) b	Hematuria		p	Chi-square Test
		(+) (n=20)	(-) (n=205)		
Tumor Type ‡					
Benign	25 (11.1)	7 (35)	18 (9.2)	0.003*	$\chi^2=12.684$
Malignant	200 (88.9)	13 (65)	187 (90.8)		
Side ‡					
Right	114 (46.6)	11 (55)	103 (50.2)	0.884*	$\chi^2=0.247$
Left	110 (52.6)	9 (45)	101 (49.3)		
Transplant	1 (0.9)	0 (0.0)	1 (0.5)		
Post-procedure Nephrostomy, yes ‡	118 (52.4)	13 (65)	7 (35)	0.273*	$\chi^2=1.200$
Entry from Which Calyx ‡					
Lower	152 (67.5)	11 (55)	141 (75.0)	0.103*	$\chi^2=4.547$
Middle	60 (26.6)	9 (45)	51 (22.7)		
Upper	13 (5.7)	0 (0.0)	13 (2.3)		
Method ‡					
First hand approach	114 (50.7)	11 (55)	103 (50.2)	0.434*	$\chi^2=0.612$
Nephrostomy route approach	111 (49.3)	9 (45)	102 (49.8)		

†: Mean ± Standard Deviation, ‡: n (%), a: Patient number, b: Antegrade double J procedure number, *: Pearson Chi-Square Fisher's Exact or Fisher Freeman Halton test

Patient demographics

The study included 151 patients with a mean age of 65.9±15.3 years. Among them, 46 (30.5%) were female, and 105 (69.5%) were male.

Hematuria and tumor type

Of the 225 ADJS procedures performed, hematuria was observed in 20 cases (8.9%), while 205 cases (91.1%) did not exhibit hematuria. Hematuria was significantly more common in patients with benign tumors (35%) compared to those with malignant tumors (9.2%) ($p=0.003$).

Laterality and transplant status

The distribution of hematuria did not significantly differ based on the side of the procedure, with 55% occurring on the right side and 45% on the left ($p=0.884$). Only one patient in the study had undergone a kidney transplant, and this patient did not develop hematuria.

Post-procedure nephrostomy

Postoperative nephrostomy was performed in 118 (52.4%) of the procedures. Among the patients who developed hematuria, 11 (55%) received a nephrostomy, compared to 9 (45%) of those who did not develop hematuria. However, this difference was not statistically significant ($p=0.811$).

Entry calyx and procedural method

The entry calyx for the nephrostomy was predominantly the lower calyx (67.5%), followed by the middle (26.6%) and upper calyx (5.7%). There was no significant difference in the incidence of hematuria based on the entry calyx ($p=0.103$). Additionally, the method of approach (first hand versus nephrostomy route) did not show a significant association with hematuria ($p=0.434$).

Discussion

This study aimed to evaluate the efficacy of percutaneous nephrostomy in managing hematuria following ADJS placement. Hematuria following ADJS placement is a relatively common complication, often resulting from microtraumas that occur during the procedure [4]. The decision to place a nephrostomy catheter post-ADJS remains controversial [5]. While nephrostomy can be inserted as a safety measure for managing hematuria following ADJS placement, there is currently insufficient data to support its necessity unequivocally.

The most common complication is bleeding, though it typically manifests as mild hematuria [3, 5]. In our study, hematuria developed in 20 out of 225 procedures (8.9%), and the majority of these cases (65%) required nephrostomy catheters. van der Meer et al. [4] reported mild hematuria in only 6 out of 130 patients following JJ stent insertion. In the presence of hematuria, it is recommended to monitor bleeding from the nephrostomy catheter for 2-3 days [6]. If the urine color does not change within this period, further investigation into the source of the bleeding may be necessary. Causes of persistent bleeding may include pseudoaneurysm, arteriovenous fistula, or arterio-calyceal fistula [6]. In this study, the only patient who required hospitalization due to hematuria was the one who had a pseudoaneurysm and was treated endovascularly. Consistent with the current study, Tlili et al. [7] observed that two patients were hospitalized for hematuria out of 188 stent insertion attempts.

Most practitioners leave a 'covering nephrostomy' in place for 24-48 hours after stent insertion [3, 7, 8]. This practice allows for the nephrostomy to be clamped to ensure adequate urine output through the stent (via the bladder)

before the nephrostomy is removed and access is lost [9]. This approach provides a safeguard, ensuring the functionality of the stent and allowing for immediate intervention if complications arise. The results of our study indicate that postoperative nephrostomy was performed in approximately half of the procedures (52.4%). When examining the association between nephrostomy placement and the development of hematuria post-ADJS, our findings revealed that among patients who experienced hematuria, a slightly higher proportion received a nephrostomy (55%) compared to those who did not develop hematuria (45%). However, it's crucial to note that this observed difference was not statistically significant ($p=0.811$). While the absence of statistical significance suggests that nephrostomy placement may not significantly affect the incidence of hematuria post-ADJS, further investigation with larger sample sizes is warranted to confirm these findings conclusively. Additionally, exploring other potential contributing factors to hematuria development and considering individual patient characteristics may provide further insights into optimal postoperative management strategies for ADJS procedures.

Interestingly, our results demonstrate a significant difference in the incidence of hematuria between patients with benign conditions and malignant tumors. Hematuria was significantly more common among patients with benign conditions, occurring in 35% of these cases, compared to only 9.2% in patients with malignant tumors ($p=0.003$). This suggests that the nature of the benign condition, such as stones or cystitis, may play a role in the likelihood of experiencing hematuria post-procedure.

One of the strengths of our study is the multicenter design, which enhances the generalizability of the findings. Additionally, the comprehensive review of medical records ensured a thorough assessment of patient outcomes. However, the retrospective nature of the study presents inherent limitations, such as potential selection bias and reliance on accurate record-keeping. Future prospective studies with larger sample sizes are needed to validate our findings and provide more robust evidence. Additionally, randomized controlled trials comparing nephrostomy with other interventions, such as conservative

management or alternative surgical techniques, would provide more definitive evidence on the optimal management strategies for this complication.

In conclusion, our study provides valuable insights into the management of hematuria following percutaneous ADJS placement. While percutaneous nephrostomy appears to be a feasible option for managing hematuria in these patients, our findings did not show a statistically significant difference in the incidence of hematuria between those who received nephrostomy and those who did not. This suggests that while nephrostomy may help in certain cases, its routine use solely for the prevention of hematuria may not be justified without further evidence. The significant difference in hematuria incidence between patients with benign and malignant conditions highlights the need for tailored management strategies based on individual patient characteristics. The multicenter design of our study enhances the generalizability of the results, yet the retrospective nature imposes limitations such as potential selection bias. Future research should focus on prospective studies with larger sample sizes and randomized controlled trials to validate these findings and optimize postoperative management strategies for ADJS procedures. These studies should also explore additional factors contributing to hematuria development to provide a more comprehensive understanding and improve patient outcomes.

Conflict of interest: No conflict of interest was declared by the authors.

References

1. Okeke Z, Okhunov Z, Smith A. Smith's textbook of endourology. 3rd ed. West Sussex: John Wiley&Sons, 2012;725-734.
2. Kim HJ, Yoon CJ, Lee S, Lee JH, Choi WS, Lee CH. Comparison between antegrade versus retrograde ureteral stent placement for malignant ureteral obstruction. *J Vasc Interv Radiol* 2022;33:1199-1206. <https://doi.org/10.1016/j.jvir.2022.06.024>
3. Yoo MJ, Bridwell RE, Inman BL, Henderson JD, Long B. Approach to nephrostomy tubes in the emergency department. *Am J Emerg Med* 2021;50:592-596. <https://doi.org/10.1016/j.ajem.2021.09.034>
4. van der Meer RW, Weltings S, van Erkel AR, et al. Antegrade ureteral stenting is a good alternative for the retrograde approach. *Curr Urol* 2017;10:87-91. <https://doi.org/10.1159/000447157>
5. Tibana TK, Grubert RM, Santos RFT, et al. Percutaneous nephrostomy versus antegrade double-J stent placement in the treatment of malignant obstructive uropathy: a cost-effectiveness analysis from the perspective of the Brazilian public health care system. *Radiol Bras* 2019;52:305-311. <https://doi.org/10.1590/0100-3984.2018.0127>
6. Hausegger KA, Portugaller HR. Percutaneous nephrostomy and antegrade ureteral stenting: technique-indications-complications. *Eur Radiol* 2006;16:2016-2030. <https://doi.org/10.1007/s00330-005-0136-7>
7. Tlili G, Ammar H, Dziri S, et al. Antegrade double-J stent placement for the treatment of malignant obstructive uropathy: a retrospective cohort study. *Ann Med Surg* 2021;69:102726. <https://doi.org/10.1016/j.amsu.2021.102726>
8. Chitale S, Raja V, Hussain N, et al. One-stage tubeless antegrade ureteric stenting: a safe and cost-effective option? *Ann R Coll Surg Engl* 2010;92:218-224. <https://doi.org/10.1308/003588410X12518836439128>
9. Dagli M, Ramchandani P. Percutaneous nephrostomy: technical aspects and indications. *Semin Intervent Radiol*. 2011;28:424-437. <https://doi.org/10.1055/s-0031-1296085>

Ethics committee approval: Permission was obtained from Pamukkale University Non-Interventional Clinical Research Ethics Committee for the study (permission date: June 12, 2024, permission number: E-60116787-020-539785).

Authors' contributions to the article

M.A. constructed the main idea and hypothesis of the study. M.A., B.K. and H.S.A. developed the theory and arranged/edited the material and method section. M.A., B.K. and K.H.A. have done the evaluation of the data in the Results section. Discussion section of the article written by M.A., H.A.S., M.D., M.A. and S.Ç. B.C reviewed, corrected and approved. In addition, all authors discussed the entire study and approved the final version.