


## Long-term Results of Proximal Pole Scaphoid Nonunion Treated with Retrograde Fixation and Non-vascularized Cancellous Bone Autograft

Retrograd Fiksasyon ve Vaskülerize Olmayan Kansellöz Kemik Ototogrefti ile Tedavi Edilen Proksimal Kutup Skafoid Kaynamamasının Uzun Dönem Sonuçları

Mehmet ARICAN

 0000-0002-0649-2339

Department of Orthopedics and  
Traumatology, Düzce University  
Medical Faculty, Düzce, Türkiye

Corresponding Author

Sorumlu Yazar

Mehmet ARICAN

ari\_can\_mehmet@hotmail.com

Received / Geliş Tarihi : 05.09.2024

Accepted / Kabul Tarihi : 05.12.2024

Available Online /

Çevrimiçi Yayın Tarihi : 17.12.2024

### ABSTRACT

**Aim:** To evaluate the long-term clinical and functional results of patients diagnosed with scaphoid bone proximal pole nonunion and who underwent retrograde fixation with non-vascularized cancellous autograft from the distal radius and a cannulated, headless screw via a volar approach.

**Material and Methods:** Twenty-nine patients, 2 female, and 27 male, who underwent surgery with the diagnosis of scaphoid proximal pole nonunion were evaluated in this study. All patients underwent retrograde fixation with a non-vascularized cancellous autograft from the distal radius and a headless cannulated screw using a volar approach and the same rehabilitation program was applied. The clinical and functional scores of the patients were evaluated before surgery and at the last follow-up.

**Results:** The mean age of the patients was  $30.66 \pm 7.34$  (range, 18-40) years. The median symptom duration was 11 (range, 6-18), and the median follow-up period after surgery was 55 (range, 36-67) months. When the maximum isometric strength of the forearm muscles of the healthy and surgical sides was evaluated at the last follow-up, the mean hand-grip strength test values of the healthy side were significantly higher than the pathological side ( $p < 0.001$ ). In addition, the mean flexion and radial deviation values of the healthy side were found to be statistically significantly higher than the surgical side in terms of the wrist joint range of motion at the last follow-up ( $p = 0.006$ , and  $p = 0.022$ , respectively).

**Conclusion:** Non-vascularized cancellous autograft and retrograde fixation with a volar approach is an effective surgical treatment option for proximal pole nonunion of the scaphoid bone.

**Keywords:** Scaphoid nonunion; proximal pole; retrograde fixation; non-vascularized cancellous bone autograft.

### ÖZ

**Amaç:** Skafoid kemik proksimal kutup kaynamama tanısı almış olan ve volar yaklaşımla distal radiusdan nonvaskülerize kanselloz otogreft ve bir adet kanüllü, başsız vida ile retrograd fiksasyon uygulanan hastaların uzun dönem klinik ve fonksiyonel sonuçlarını değerlendirmektir.

**Gereç ve Yöntemler:** Bu çalışmada skafoid proksimal kutup kaynamama tanısı ile cerrahi yapılan, 2 kadın ve 27 erkek olmak üzere yirmi dokuz hasta değerlendirildi. Tüm hastalara volar yaklaşımla distal radiustan nonvaskülerize kanselloz otogreft ve bir adet başsız kanüllü vida ile retrograd fiksasyon yapıldı ve aynı rehabilitasyon programı uygulandı. Hastaların klinik ve fonksiyonel skorları cerrahi öncesi ve son kontrolde değerlendirildi.

**Bulgular:** Hastaların ortalama yaşı  $30,66 \pm 7,34$  (aralık, 18-40) yılı idi. Ortanca semptom süresi 11 (aralık, 6-18) ay ve cerrahi sonrası ortalama takip süresi 55 (aralık, 36-67) ay idi. Son kontrolde sağlam ve cerrahi uygulanan tarafların ön kol kaslarının maksimum izometrik kuvveti değerlendirildiğinde, sağlam tarafın ortalama el kavrama gücü test değerleri patolojik tarafa göre anlamlı derecede daha yüksekti ( $p < 0,001$ ). Buna ek olarak, son kontrolde el bilek eklem hareket açıklığı açısından sağlam tarafın ortalama fleksiyon ve radial deviasyon değerlerinin cerrahi uygulanan tarafa göre istatistiksel olarak anlamlı derecede daha yüksek olduğu bulundu (sırasıyla  $p = 0,006$  ve  $p = 0,022$ ).

**Sonuç:** Skafoid kemik proksimal kutup kaynamama durumunda, volar yaklaşımla nonvaskülerize kanselloz otogreft ve retrograd fiksasyon etkili bir cerrahi tedavi seçeneğidir.

**Anahtar kelimeler:** Skafoid kaynamaması; proksimal kutup; retrograd fiksasyon; nonvaskülerize kanselloz kemik otogrefti.

## INTRODUCTION

Scaphoid fractures are the most common fractures among the carpal bone fractures (1-3). Nonunion is observed in 5-25% of scaphoid fractures after treatment, and nonunion is more common, especially in elderly patients, smokers, and when there is a delay in the initial treatment of the fracture (4,5). In addition, scaphoid nonunion is frequently encountered in untreated cases, in patients with undiagnosed cases, and in patients who do not heal despite conservative treatment (3,6). In addition to standard radiographs, computed tomography is frequently used in diagnosis, especially in surgical patients, but magnetic resonance imaging is also frequently used to evaluate avascular necrosis (4). In standard radiographs used in diagnosis, diagnosis is often made late or overlooked because the scaphoid fracture line cannot be clearly determined (2).

In the literature, the risk of developing nonunion is reported in scaphoid fractures diagnosed six weeks after the fracture and without radiological evidence of union despite eight weeks of conservative treatment (1,4,6). The incidence of nonunion is not fully known because some patients continue to be asymptomatic (2). It has been reported that chronic wrist pain and progressive arthrosis may develop in symptomatic cases with nonunion (5). Scaphoid fractures are classified according to their location in the scaphoid as tuberosity (17%), proximal pole (6%), middle (66%) and distal pole (11%). This classification helps in determining the treatment methods to be applied, the vascularity of the fractured part, the potential for healing, or whether surgical treatment is required (3). The vascularity of the scaphoid bone is provided by the palmar and dorsal branches of the radial artery. The dorsal branch of the radial artery is solely responsible for the vascularity of the proximal pole (7). The necessity of surgery in the treatment of proximal pole nonunion is a common opinion of all hand surgeons, but there is no method accepted as a gold standard in the literature in terms of fixation method, volar/dorsal surgical approach, or grafting technique (8-10). In the cadaver model study by Daly et al. (11), in which they compared the biomechanical strength of retrograde and antegrade fixation in proximal pole scaphoid fractures, it was emphasized that antegrade and retrograde screw fixation were equivalent in terms of biomechanical strength. In the systematic evaluation and meta-analysis study conducted by Duncumb et al. (12) regarding the selection of bone graft in scaphoid nonunion surgery, it was emphasized that vascularized bone graft application did not provide significantly superior results compared to non-vascularized graft in the management of scaphoid nonunion. In addition, the authors stated that the fixation type or source of the graft used did not affect the union rates. Although successful results have been reported in the literature with vascular or non-vascular cancellous bone grafts and dorsal antegrade/volar retrograde fixation methods for proximal pole nonunion surgery, there is no consensus (13,14).

The aim of this study was to compare the clinical and functional long-term results of patients who underwent surgery with the diagnosis of scaphoid proximal pole nonunion and were treated with a cancellous graft from the distal radius and one headless screw with retrograde fixation using a volar approach.

## MATERIAL AND METHODS

Of the 32 patients who underwent surgery due to the diagnosis of scaphoid proximal pole nonunion in our clinic between December 2009 and June 2013, 29 patients who met the inclusion criteria were included in the study. All patients who received nonvascularized cancellous autograft from the distal radius with a volar approach and underwent retrograde fixation surgery with a headless cannulated screw were evaluated clinically and functionally, retrospectively. This study was approved by the Duzce University Faculty of Medicine Non-invasive Health Research Ethics Committee (21.10.2019, 186) and all patients were informed about the study, an informed consent form and approval were obtained.

The inclusion criteria for the study were; between the ages of 18-45, proximal pole nonunion, volar approach, retrograde fixation, non-vascularized cancellous bone graft from the distal volar radius, a headless cannula screw, and magnetic resonance imaging before surgery. Exclusion criteria for the study were; being under 18 or over 45 years of age, dorsal approach, having previously undergone hand surgery for any reason, avascular proximal pole on magnetic resonance imaging (MRI), scaphoid middle or distal 1/3 nonunion, and Kirshner wire. Three patients were excluded from the study because it was observed that regular wrist joint range of motion measurements were not recorded during routine outpatient clinic control.

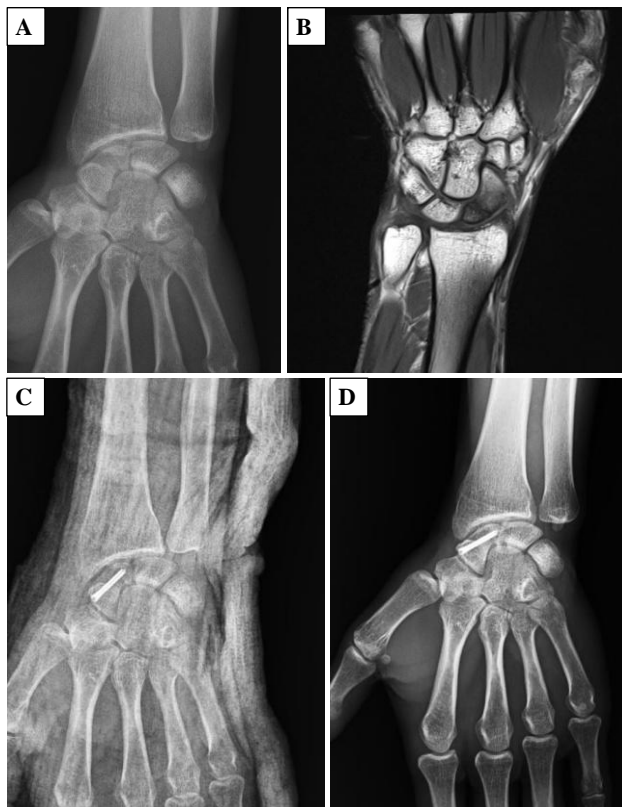Demographic data of the patients were evaluated as follows; age, gender, surgical side, dominant extremity, etiology, smoking, duration of symptoms, follow-up period, grip strength test measurement (Jamar® Hydraulic Hand Dynamometer) before surgery and at the last follow-up, pain level before surgery and at the last follow-up, functional tests for the wrist, surgical satisfaction level, and healthy/pathological wrist range of motion.

The clinical and functional scores of the patients were evaluated with the scales of patient-rated tennis elbow evaluation (PRTEE), quick-disabilities of the arm, shoulder, and hand (Q-DASH), and visual analog scale (VAS) scores measured before surgery and at the last follow-up. The PRTEE score (maximum 100 points) evaluates the pain (50 points) in the affected arm and the function (100/2 points) in the affected arm (specific activities, activities of daily living). Q-DASH is a regional outcome measure developed for upper extremity musculoskeletal disorders and contains 11 questions. In order to calculate the score of the scale, which is reported to be used instead of DASH, at least 10 of the 11 questions must be answered. Each question is scored on a 5-point scale and a final score ranging from 0 (no disability) to 100 (severe disability) is calculated. VAS is used to convert some values that cannot be measured numerically into numerical values. The two extreme definitions of the parameter to be evaluated are written at both ends of a 100 mm line and the patient is asked to indicate where their own condition fits on this line by drawing a line, putting a dot, or marking. For example, for pain, I have no pain at one end and very severe pain is written at the other end and the patient marks their current condition on this line. The length of the distance from the point where there is no pain to the point marked by the patient indicates the patient's pain.

### Surgical Technique and Rehabilitation

All patients underwent surgery under general anesthesia and with a tourniquet. A skin incision was made from the distal part of the flexor carpi radialis tendon to the level of the palmar rim of the distal radius and then to the scaphoid tubercle and scaphotrapezium joint. After retracting the superficial palmar branch of the radial artery, the flexor carpi radialis tendon was retracted to the ulnar side. After the capsule was opened obliquely from the scaphoid tubercle to the palmar rim of the radius, the radioscaphocapitate ligament was retracted. The long radiolunate ligament was incised to the palmar edge of the radius and the nonunion line was revealed. All fibrous tissues and sclerotic bone tissues in both the proximal and distal nonunion lines were removed with the help of a curette, burr, or osteotome. After adequate debridement, the distal radius was reached through the same volar proximal skin incision and sufficient pure cancellous bone autograft was taken by opening a window in the radius. After the grafting process was completed, retrograde fixation was achieved with a suitable size, 1.6 mm cannulated, headless screw (ACUMED), and the reduction was checked with scopy. The incision lines were closed according to the anatomy (Figure 1).

In all patients, the wrist was immobilized with a short arm splint for 6 weeks to allow for the healing of the soft tissues and radioscaphocapitate ligament after surgery, and then all patients underwent wrist rehabilitation with the same physical therapy protocol.



**Figure 1.** Long-term radiographic follow-up of a 29-year-old male patient who underwent scaphoid proximal pole nonunion surgery. **A)** Anteroposterior wrist radiograph, **B)** Coronal magnetic resonance imaging at 11 months after trauma (preoperative), Anteroposterior wrist radiograph **C)** 1 day, and **D)** 50 months after surgery with the complete union of the scaphoid

### Statistical Analysis

Statistical analyses were performed with the Number Cruncher Statistical Systems (NCSS) 2007 statistical software (Utah, USA). In addition to descriptive statistical methods (mean, standard deviation, median, interquartile range, minimum, maximum) in the evaluation of the data, the distribution of the variables was examined with the Shapiro-Wilk normality test. In the comparison of the first and last measurements of the variables showing normal distribution the paired samples t-test was used, while the Wilcoxon test was used for variables not showing normal distribution. The independent samples t-test was used to compare two groups and categorical variables were analyzed with Fisher's exact test. The results were evaluated at the significance level of  $p < 0.05$ .

### RESULTS

Of the 29 patients included in the study, 2 were female and 27 were male, and their mean age was  $30.66 \pm 7.34$  (range, 18-40) years. The median symptom duration until surgery was 11 (range, 6-18) months. The median follow-up period after surgery was 55 (range, 36-67) months. When the functional scores of the patients were compared, the median VAS, Q-DASH, and PRTEE values measured at the last follow-up period were found to be statistically significantly lower than the values measured before surgery ( $p < 0.001$  for all, Table 1). When we evaluated the maximum isometric strength of the forearm muscles of the healthy and surgical sides at the last follow-up period after surgery, the mean hand-grip strength test values of the healthy side were found to be statistically significantly higher than the pathological side ( $p < 0.001$ ). In addition, when the wrist joint range of motion of the healthy and surgical sides was evaluated at the last follow-up period, no statistically significant difference was observed between the mean extension ( $p = 0.075$ ) and ulnar deviation ( $p = 0.234$ ) values, but the mean flexion ( $p = 0.006$ ) and radial deviation ( $p = 0.022$ ) values of the healthy side were found to be statistically significantly higher than the surgical side (Table 2). Nonunion was detected in a total of 4 patients, 3 male and 1 female, at their last follow-up. The mean age ( $p = 0.011$ ), and advanced osteoarthritis findings ( $p = 0.001$ ) of the nonunion group were found to be significantly higher than the union group (Table 3).

### DISCUSSION

In this study, where we evaluated the long-term results of patients who underwent surgical treatment with a volar approach and non-vascularized bone graft from the distal radius for proximal pole nonunion in scaphoid bone fractures, 86% complete union was achieved. We concluded that there was a significant clinical improvement compared to pre-surgical values in the clinical evaluation made with PRTEE and Q-DASH measurements. It was found that especially extension and ulnar deviation movements were almost completely gained when we evaluated the range of motion of the joint in comparison with the healthy wrist.

Despite the diversity and lack of consensus in management of nonunion after scaphoid bone fractures, studies have reported very successful long-term results (1,15,16). In a study by Reigstad et al. (15) evaluating scaphoid fracture nonunion with a long-term follow-up, they concluded that

**Table 1.** Comparison of clinical and functional test values of patients before and after (final evaluation) surgery

	Preoperative		Final evaluation		p
	Mean±SD	Median (IQR) [min-max]	Mean±SD	Median (IQR) [min-max]	
VAS	6.89±1.49	7 (6-8) [4-10]	1.03±1.48	1 (0-1) [0-5]	<0.001
Q-DASH	61.91±18.57	65.9 (43.2-70.5) [20.5-88.6]	6.97±9.45	0 (0-12.5) [0-36.4]	<0.001
PRTEE	66.21±11.92	66 (57-75) [40-90]	8.60±7.62	7 (0-15) [0-23.5]	<0.001

VAS: visual analog scale, Q-DASH: quick-disabilities of the arm, shoulder, and hand, PRTEE: patient-rated tennis elbow evaluation, SD: standard deviation, IQR: interquartile range

**Table 2.** Hand grip strength and joint range of motion values of the wrist with nonunion surgery and healthy wrist

	Healthy Wrist	Lesion Wrist	p
<b>Grip Strength</b>	82.52±14.05	65.69±21.82	<0.001
<b>Flexion</b>	78.38±11.72	72.93±13.30	0.006
<b>Extension</b>	69.00±10.10	66.21±10.17	0.075
<b>Radial Deviation</b>	29.00±5.35	25.93±6.82	0.022
<b>Ulnar Deviation</b>	41.76±5.93	39.62±8.96	0.234

**Table 3.** Comparison of patients with and without union after nonunion surgery due to scaphoid fracture

	Nonunion	Union	p
<b>Age (years), mean±SD</b>	39.00±1.55	29.32±7.02	0.011
<b>Gender, n (%)</b>			
Male	3 (75.0)	24 (96.0)	0.261
Female	1 (25.0)	1 (4.0)	
<b>Fracture, n (%)</b>			
Right	2 (50.0)	10 (40.0)	>0.999
Left	2 (50.0)	15 (60.0)	
<b>Smoking, n (%)</b>	2 (50.0)	12 (48.0)	>0.999
<b>Osteoarthritis, n (%)</b>			
None	0 (0.0)	19 (76.0)	0.001
Mild	1 (25.0)	3 (12.0)	
Moderate	0 (0.0)	3 (12.0)	
Extremely	3 (75.0)	0 (0.0)	

SD: standard deviation

the applied surgery reduced pain, improved wrist functions, and slowed down degenerative changes. In another scaphoid nonunion study by Jaminet et al. (16) evaluating the radiological results of 286 patients at the end of ten years, they emphasized that the prognosis of scaphoid nonunion could be very good with the application of a correct treatment algorithm. Similar to the literature, in this study, we obtained very successful results both clinically and functionally in proximal pole nonunion, which we followed up for a long time.

It is still a matter of debate whether the bone graft to be used in proximal pole nonunions of the scaphoid bone is vascularized or non-vascularized (17-20). Rancy et al. (19) emphasized that non-vascularized autograft and rigid fixation are quite effective in achieving union despite vascular ischemia and histopathological osteonecrosis in their prospective study on proximal pole nonunions of the scaphoid. In addition, the authors stated that vascularized bone grafting is rarely necessary for internal fixation of scaphoid nonunions. Similarly, Luchetti et al. (20) achieved

90% union after cancellous non-vascularized autograft taken from the distal radius and fixation in proximal pole nonunions and also stated that non-vascularized cancellous autograft and antegrade fixation a useful options in the treatment of proximal pole scaphoid nonunions.

The management of scaphoid nonunion surgery is quite difficult due to reasons such as the geometry of the scaphoid bone, the fracture site, and the vascular supply pattern (21). In particular, the decision to choose the volar or dorsal approach is very important in scaphoid proximal pole nonunions. The dorsal approach is the most preferred method in proximal pole nonunions, when the literature is examined, (22-28). For example, in the meta-analysis study conducted by Merrel et al. (26) in terms of scaphoid nonunion surgery, they emphasized that there was a 67% recovery rate for proximal pole nonunions in surgeries performed with the dorsal approach. In another study conducted by Weber et al. (27) in proximal pole scaphoid nonunions with the volar approach, they emphasized that union, joint range of motion, and grip strength were at a good level. Finsen et al. (28) evaluated bone chip graft and Kirschner wire fixation in scaphoid nonunion surgery with a 10-year follow-up period and reported that bone union was quite successful in another study. The authors also emphasized that this method is excellent for proximal pole nonunions. In contrast to these studies, some studies adopt retrograde fixation with a volar approach in proximal scaphoid fracture surgery (11,29). In a cadaver study by Daly et al. (11), they compared the biomechanical strength of retrograde fixation in proximal pole scaphoid fractures and divided 22 scaphoids into two groups to create proximal pole fractures. They compared antegrade fixation with a dorsal approach and retrograde fixation with a volar approach biomechanically in this current study. The authors emphasized that antegrade and retrograde screw configurations are equivalent in terms of biomechanical strength. In another clinical study by Jeon et al. (29), comparing percutaneous screw application with volar and dorsal approaches in scaphoid fractures, they stated that the screws were placed more parallel to the long axis of the scaphoid and more perpendicular to the fracture line with the dorsal approach, but they emphasized that there was no significant difference in terms of functional outcome and bone union.

In nonunion cases developing after scaphoid bone fractures, carpal instability, collapse or advanced osteoarthritic changes in the radio scaphoid joint may be observed after the conservative or surgical approaches (25,30,31). In a long-term follow-up study by Daecke et al. (31) evaluating the formation of carpal osteoarthritis after scaphoid nonunion treatment with bone graft and cannulated screws, it was stated that high patient satisfaction and good

function were observed after the healing of scaphoid nonunion. In addition, the authors emphasized that correct anatomical reconstruction of the non-arthritic joint with cannulated screws in long-term follow-ups suggests the onset of osteoarthritic changes in most patients. In this study, nonunion was detected in 4 of 29 patients, and advanced osteoarthritic changes developed in the radio scaphoid joint of the patients.

There are some limitations of this study in which we evaluated patients who underwent retrograde fixation with a volar approach for proximal pole scaphoid fracture nonunions. First, it is a retrospective study with a small number of patients. Second, the patient group consists of young patients, and therefore the clinical and functional results may have been quite good. Finally, the proximal fragment was not separated in terms of size, and all proximal pole nonunions were included in the study.

## CONCLUSION

Although the volar approach is not preferred in terms of the shape of the scaphoid bone, fracture pattern, and screw configuration in proximal pole nonunions of scaphoid fractures, non-vascularized cancellous autograft and retrograde fixation with the volar approach is a highly effective surgical treatment option in proximal pole nonunions of the scaphoid bone.

**Ethics Committee Approval:** The study was approved by the Non-invasive Health Research Ethics Committee of Düzce University (21.10.2019, 186).

**Conflict of Interest:** None declared by the authors.

**Financial Disclosure:** None declared by the authors.

**Acknowledgments:** None declared by the authors.

**Author Contributions:** Idea/Concept: MA; Design: MA; Data Collection/Processing: MA; Analysis/Interpretation: MA; Literature Review: MA; Drafting/Writing: MA; Critical Review: MA.

## REFERENCES

- Rhee PC, Jones DB Jr, Shin AY, Bishop AT. Evaluation and treatment of scaphoid nonunions: a critical analysis review. *JBJS Rev.* 2014;2(7):e4.
- Huang YC, Liu Y, Chen TH. Long-term results of scaphoid nonunion treated by intercalated bone grafting and Herbert's screw fixation--a study of 49 patients for at least five years. *Int Orthop.* 2009;33(5):1295-300.
- Steinmann SP, Adams JE. Scaphoid fractures and nonunions: diagnosis and treatment. *J Orthop Sci.* 2006;11(4):424-31.
- Yeo JH, Kim JY. Surgical strategy for scaphoid nonunion treatment. *J Hand Surg Asian Pac Vol.* 2018;23(4):450-62.
- Ammori MB, Elvey M, Mahmoud SS, Nicholls AJ, Robinson S, Rowan C, et al. The outcome of bone graft surgery for nonunion of fractures of the scaphoid. *J Hand Surg Eur Vol.* 2019;44(7):676-84.
- Rogers MJ, Ohlsen SM, Huang JI. Fixation techniques for scaphoid nonunion. *J Am Acad Orthop Surg.* 2023;31(15):783-92.
- Taleisnik J, Kelly PJ. The extraosseous and intraosseous blood supply of the scaphoid bone. *J Bone Joint Surg Am.* 1966;48(6):1125-37.
- Aibinder WR, Wagner ER, Bishop AT, Shin AY. Bone grafting for scaphoid nonunions: is free vascularized bone grafting superior for scaphoid nonunion? *Hand (N Y).* 2019;14(2):217-22.
- Papatheodorou LK, Papadopoulos DV, Graber MM, Sotereanos DG. Dorsal capsular-based vascularized distal radius graft for proximal pole scaphoid nonunion with avascular necrosis. *Injury.* 2021;52(12):3635-9.
- Miller EA, Huang JI. Traditional bone grafting in scaphoid nonunion. *Hand Clin.* 2024;40(1):105-16.
- Daly CA, Boden AL, Hutton WC, Gottschalk MB. Biomechanical strength of retrograde fixation in proximal third scaphoid fractures. *Hand (N Y).* 2019;14(6):760-4.
- Duncumb JW, Robinson PG, Williamson TR, Murray IR, Campbell D, Molyneux SG, et al. Bone grafting for scaphoid nonunion surgery: a systematic review and meta-analysis. *Bone Joint J.* 2022;104-B(5):549-58.
- Rancy SK, Wolfe SW, Jerome JTJ. Predictors of failure for vascularized and nonvascularized bone grafting of scaphoid nonunions: a systematic review. *J Hand Microsurg.* 2021;14(4):322-35.
- Fujihara Y, Yamamoto M, Hidaka S, Sakai A, Hirata H. Vascularised versus non-vascularised bone graft for scaphoid nonunion: Meta-analysis of randomised controlled trials and comparative studies. *JPRAS Open.* 2022;35:76-88.
- Reigstad O, Grimsgaard C, Thorkildsen R, Reigstad A, Rokkum M. Long-term results of scaphoid nonunion surgery: 50 patients reviewed after 8 to 18 years. *J Orthop Trauma.* 2012;26(4):241-5.
- Jaminet P, Götz M, Gonser P, Schaller HE, Lotter O. Treatment of scaphoid nonunion: radiologic outcome of 286 patients in 10 years. *Eplasty.* 2019;19:e5.
- Ribak S, Medina CE, Mattar R Jr, Ulson HJ, Ulson HJ, Etchebehere M. Treatment of scaphoid nonunion with vascularised and nonvascularised dorsal bone grafting from the distal radius. *Int Orthop.* 2010;34(5):683-8.
- Tambe AD, Cutler L, Murali SR, Trail IA, Stanley JK. In scaphoid non-union, does the source of graft affect outcome? Iliac crest versus distal end of radius bone graft. *J Hand Surg Br.* 2006;31(1):47-51.
- Rancy SK, Swanstrom MM, DiCarlo EF, Sneag DB, Lee SK, Wolfe SW. Success of scaphoid nonunion surgery is independent of proximal pole vascularity. *J Hand Surg Eur Vol.* 2018;43(1):32-40.
- Luchetti TJ, Rao AJ, Fernandez JJ, Cohen MS, Wysocki RW. Fixation of proximal pole scaphoid nonunion with non-vascularized cancellous autograft. *J Hand Surg Eur Vol.* 2018;43(1):66-72.
- McInnes CW, Giuffre JL. Fixation and grafting after limited debridement of scaphoid nonunions. *J Hand Surg Am.* 2015;40(9):1791-6.

22. Wagner ER, Spencer CC, Dawes AM, Gottschalk MB, Daly CA. Management of proximal pole scaphoid nonunions: a critical analysis review. *JBJS Rev.* 2021;9(4):e19.00181.
23. Waters PM, Stewart SL. Surgical treatment of nonunion and avascular necrosis of the proximal part of the scaphoid in adolescents. *J Bone Joint Surg Am.* 2002;84(6):915-20.
24. Severo AL, Lemos MB, Lech OLC, Barreto Filho D, Strack DP, Candido LK. Bone graft in the treatment of nonunion of the scaphoid with necrosis of the proximal pole: a literature review. *Rev Bras Ortop.* 2017;52(6):638-43.
25. Matsuki H, Ishikawa J, Iwasaki N, Uchiyama S, Minami A, Kato H. Non-vascularized bone graft with Herbert-type screw fixation for proximal pole scaphoid nonunion. *J Orthop Sci.* 2011;16(6):749-55.
26. Merrell GA, Wolfe SW, Slade JF 3rd. Treatment of scaphoid nonunions: quantitative meta-analysis of the literature. *J Hand Surg Am.* 2002;27(4):685-91.
27. Weber MB, Bishop AT, Shin AY. Osteochondral autograft transplantation for proximal pole scaphoid nonunions. *J Hand Surg Am.* 2023;48(7):655-64.
28. Finsen V, Hofstad M, Haugan H. Most scaphoid nonunions heal with bone chip grafting and Kirschner-wire fixation. Thirty-nine patients reviewed 10 years after operation. *Injury.* 2006;37(9):854-9.
29. Jeon IH, Micic ID, Oh CW, Park BC, Kim PT. Percutaneous screw fixation for scaphoid fracture: a comparison between the dorsal and the volar approaches. *J Hand Surg Am.* 2009;34(2):228-36.e1.
30. Lim TK, Kim HK, Koh KH, Lee HI, Woo SJ, Park MJ. Treatment of avascular proximal pole scaphoid nonunions with vascularized distal radius bone grafting. *J Hand Surg Am.* 2013;38(10):1906-12.e1.
31. Daecke W, Wieloch P, Vergetis P, Jung M, Martini AK. Occurrence of carpal osteoarthritis after treatment of scaphoid nonunion with bone graft and Herbert screw: a long-term follow-up study. *J Hand Surg Am.* 2005;30(5):923-31.