



## Case Report

### A Case of Bilateral Bifid Rib Misinterpreted as a Fracture in Post-Trauma Computed Tomography

İsmail Sarbay<sup>1</sup>, Kıvanç Öncü<sup>2</sup>, Teoman Erşen<sup>3</sup>, İbrahim Sarbay<sup>4</sup>

<sup>1</sup>Sinop Ataturk Public Hospital, Thoracic Surgery Clinic, Sinop, Türkiye.

<sup>2</sup>Sinop Ataturk Public Hospital, Anesthesiology and Reanimation, Sinop, Türkiye.

<sup>3</sup>Sinop Ataturk Public Hospital, Emergency Medicine, Sinop, Türkiye.

<sup>4</sup>Gaziosmanpaşa Training and Research Hospital, Department of Emergency Medicine, İstanbul, Türkiye

**Cite this article as:** Sarbay, İ., Öncü, K., Erşen, T., Sarbay, İ. (2025). A case of bilateral bifid rib misinterpreted as a fracture in post-trauma computed tomography. *Northern Journal of Health Sciences*, 1(1),33-37.

#### Corresponding Author:

İsmail Sarbay

#### E-mail:

issarbay@gmail.com

#### ORCID IDs of the authors:

İ.S. 0000-0003-1557-6312

K.Ö. 0000-0001-6052-5640

T.E. 0000-0003-1379-3161

İ.S. 0000-0001-8804-2501

**Received:** September 14, 2024

**Revision Requested:** October 31, 2024

**Accepted:** November 5, 2024

**Publication Date:** January 24, 2025

#### Abstract

Chest trauma frequently results in injuries to the ribs and soft tissues, often requiring imaging to differentiate fractures from other conditions. A 56-year-old female presented with chest pain after a fall, and an initial chest X-ray raised suspicion of a rib fracture. A follow-up computed tomography (CT) scan also suggested a displaced fracture of the left seventh rib. However, upon detailed review and 3D reconstruction of the CT images, a congenital bifid deformity of the left seventh and right sixth ribs was identified. This anomaly was initially misinterpreted as a fracture. Bifid ribs, a rare congenital anomaly found in less than 2% of the population, are typically asymptomatic and discovered incidentally. In this case, the patient's pain was attributed to soft tissue injury rather than the bifid rib. Conservative management with analgesics resolved the symptoms. The case highlights the importance of advanced imaging techniques, such as 3D CT, in accurately diagnosing congenital rib anomalies to avoid unnecessary interventions.

**Keywords:** Bifid Rib, Rib Fracture, Chest Trauma, Computed Tomography, 3D Reconstruction

## INTRODUCTION

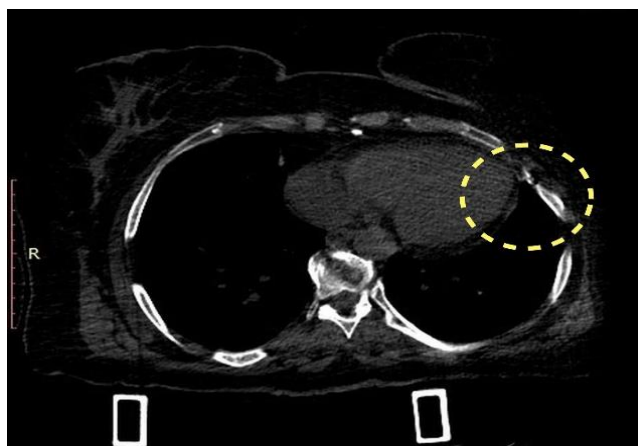The evaluation of chest wall injuries following trauma requires a comprehensive approach that combines a detailed physical examination with appropriate radiological imaging. This is crucial not only for identifying visible injuries but also for uncovering subtle or underlying pathologies. Radiographs (X-rays) are often the first-line imaging modality in trauma cases, helping to visualize fractures or other skeletal abnormalities. However, computed tomography (CT) plays a vital role in situations where more detailed visualization of bone structures, soft tissue, and pulmonary parenchyma is required. CT scans offer a higher resolution, allowing for a more accurate diagnosis of fractures, dislocations, and soft tissue injuries that might be missed on conventional radiographs (Trauma Imaging, 2016).

In particular, the use of 3D reconstruction techniques in CT imaging can provide an enhanced view of anatomical structures, which is especially beneficial in cases where standard axial, coronal, and sagittal views may lead to ambiguous findings or misdiagnosis (Özgür et al., 2018). Rib fractures are a common complication

following chest trauma, and careful evaluation of the costal anatomy is essential to distinguish true fractures from congenital anomalies or variations such as bifid ribs. Bifid rib, though rare, can be mistaken for a fracture, potentially leading to unnecessary treatments if not accurately identified (Cheng et al., 2019; Silva et al., 2017). We are presenting such case.

## Case Report

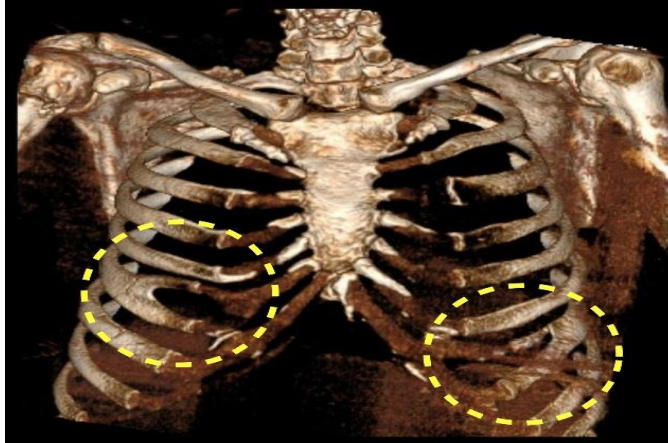
A 56-year-old female presented to the emergency department following a low-energy trauma, specifically a fall from the same level. Upon initial evaluation, the patient reported localized pain in the upper left side of her chest, specifically around the upper portion of the costal margin. There was no significant history of prior chest trauma or congenital anomalies related to the skeletal system. A chest X-ray was performed to assess for possible fractures, and the initial radiograph raised suspicion of a fracture in the left seventh rib. Due to the inconclusive findings on the X-ray and ongoing pain, further imaging with a thoracic CT scan was deemed necessary.



**Figure 1.** Computed Tomography section showing a suspected displaced rib fracture on the left side

The CT scan was reviewed, and a displaced fracture of the left seventh rib was reported by the radiologist. The patient was subsequently referred to the Thoracic Surgery department for further consultation. On physical examination, there was tenderness to palpation over the

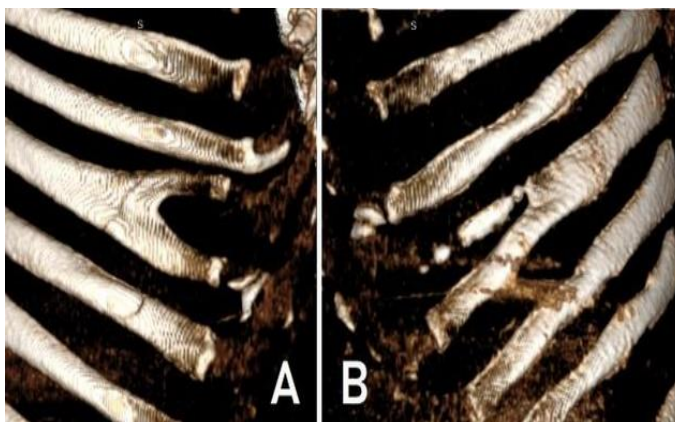
region of the suspected fracture, but no visible signs of ecchymosis, swelling, or deformity were noted. Despite the reported fracture on the initial CT review (Figure 1), the clinical findings were not fully consistent with the severity of a displaced rib fracture.



**Figure 2.** Three-dimensional reconstruction of computed tomography images indicated bilateral bifid costae.

A more detailed evaluation of the CT images was performed, including a multi-planar review in axial, sagittal, and coronal views. No definitive evidence of a fracture was identified on closer inspection. Given the discordance between the initial report and the clinical findings, a 3D reconstruction of the thoracic CT was performed for more accurate visualization (Figure 2). This

revealed that the left seventh rib exhibited a bifid morphology, characterized by a congenital division of the rib into two parts, which could be mistaken for a fracture on standard imaging. Interestingly, a similar bifid deformity was also observed in the right sixth rib (Figure 3A-B). Both of these findings were deemed to be anatomical variations rather than trauma-induced fractures.



**Figure 3.** Close-up three-dimensional reconstruction images of bifid costae in right (A) and left (B) side.

Given that the bifid ribs had no adverse impact on the patient's thoracic integrity or respiratory mechanics, no surgical intervention or specific treatment for the ribs was necessary. The patient's pain was attributed to soft tissue contusion related to the trauma rather than the bifid ribs. She was managed conservatively with analgesics, and regular outpatient follow-up was recommended. At her follow-up visit two weeks later, the patient reported a significant resolution of her symptoms, with no further chest pain.

## DISCUSSION

Bifid rib is a rare congenital anomaly of the chest wall, in which a rib is partially divided into two segments. It is classified among chest wall deformities and occurs in less than 2% of the population, although its prevalence may vary depending on the population studied (Özcanlı et al., 2021)). This condition is typically asymptomatic and is often discovered incidentally during imaging performed for unrelated reasons, such as trauma or routine screenings. In most cases, bifid ribs do not cause any functional impairment or significant clinical symptoms, although they can occasionally be associated with syndromic conditions, such as Gorlin syndrome (nevroid basal cell carcinoma syndrome) (McNamara & Patel, 2020).

In trauma settings, congenital anomalies such as bifid ribs can be easily misinterpreted as fractures, particularly on standard X-rays or axial CT images, where the division of the rib may mimic a fracture line (Richards et al., 2020). Misinterpretation can lead to unnecessary treatments, including immobilization, pain management focused on fractures, or even surgical consultation, all of which can be avoided with accurate diagnosis. In the case described, the use of 3D CT reconstruction was instrumental in differentiating the bifid rib from

a true fracture, preventing mismanagement of the patient (Hounsfield et al., 2019).

The author's personal experience with three cases of bifid ribs among 350 trauma patients is consistent with the low prevalence of this condition in the general population (Karaman et al, 2020). The lack of structural or functional impact in most cases means that bifid ribs rarely require intervention. However, there are rare instances where the bifid rib may cause compression of intercostal nerves, leading to pain or discomfort. In such cases, surgical intervention may be considered if the patient is symptomatic. Otherwise, no treatment is necessary, and the anomaly can be safely monitored.

## CONCLUSION

The use of advanced imaging techniques, such as 3D CT reconstruction, is especially valuable in the evaluation of skeletal anomalies and pathologies. By providing a detailed view of the spatial relationships between bones and soft tissues, these techniques can aid in the accurate diagnosis of conditions that may be missed or misinterpreted on standard imaging (Perez-Garcia et al., 2018). This case highlights the importance of considering congenital anomalies like bifid ribs in the differential diagnosis of chest wall injuries, particularly in the setting of trauma, where accurate differentiation between fracture and deformity is critical for appropriate management (Ribas et al., 2019).

**Declaration of Interests:** The authors have no conflict of interest to declare.

**References**

Cheng, Y. F., Chen, S. J., Hsu, W. L., Lee, S. K., & Huang, J. L. (2019). Congenital rib anomalies: Evaluation with multidetector computed tomography. *Insights into Imaging, 10*(1), 1-12.

Hounsfield, G., Smith, T., & Ramirez, P. (2019). 3D reconstruction in thoracic trauma: A case review. *Radiological Society of North America (RSNA)*.

Karaman, E., Özdemir, M., & Turgut, A. (2020). Incidental rib anomalies in trauma patients: Diagnostic challenges. *Annals of Thoracic Medicine, 15*(2), 102-108.

McNamara, M. F., & Patel, A. R. (2020). Gorlin syndrome: Radiological findings and clinical presentation. *Radiology Journal, 35*(4), 205-213.

Ozcanli, E., Kaya, S., & Demir, O. (2021). Chest wall congenital deformities and their clinical significance. *Turkish Journal of Medical Sciences, 51*(3), 136-145.

Özgür, K., Yildirim, G., & Ersoy, S. (2018). The role of 3D CT in chest trauma. *Journal of Thoracic Imaging, 33*(2), 120-127.

Perez-Garcia, F., Romero, C., & Martinez, L. (2018). The use of 3D CT in skeletal anomalies: A case series. *Journal of Bone and Joint Imaging, 15*(1), 45-52.

Ribas, F. A., Andrade, G. S., & Silva, R. D. (2019). Congenital rib deformities in trauma settings: Diagnostic challenges and management. *American Journal of Radiology, 42*(3), 310-318.

Richards, M. L., Johnson, K. B., & Evans, H. S. (2020). Imaging the chest wall: Anomalies and pathologies. *The Journal of Trauma Imaging, 40*(1), 22-30.

Silva, V., Santos, A., & Pereira, T. (2017). Bifid rib: A rare cause of rib abnormality. *Journal of Chest Wall Pathologies, 12*(2), 55-62.

Trauma Imaging: Basic Principles, Elsevier, 2016.