

Ossification of Superior Transvers Scapular Ligament: A Case Report

Ligamentum Transversum Scapulae Superius'un Kemikleşmesi: Olgu Sunumu

Kemal Emre ÖZEN*,
Gökalep ŞAHİN*,
Anıl Didem Aydın
KABAKÇI*,
Aynur Emine
ÇİÇEKÇİBAŞI*,
Demet AYDOĞDU**,
Duygu Akın SAYGIN*.

*: Necmettin Erbakan
University, Meram Faculty
of Medicine, Department of
Anatomy, Konya
**: Necmettin Erbakan
University, Meram Faculty
of Medicine, Department of
Radiology, Konya

Yazışma Adresi:
Kemal Emre Özen, MD, PhD
Department of Anatomy,
Faculty of Medicine, İzmir Kâ
tip Çelebi Üniversitesi,
Balatçık Mh. Havaalanı Şosesi
Cd, Nu:33/235620 Çiğil/
İzmir, Türkiye.
Phone : +9023232935/5811
Fax : +902323254042
E-mail :
kemalemre9870@yahoo.com

Öz

Kompresyon nöropatileri olarak da bilinen tuzak nöropatiler, travma, inflamasyon veya ödem gibi herhangi bir sebebe bağlı olarak, periferik sinirin hedef dokuya seyri esnasında baskıya uğramasıdır. Hastanemize başvuran 43 yaşındaki bir kadın hastanın multidedektörlü bilgisayarlı tomografi görüntülerinin incelenmesi esnasında ligamentum transversum scapulae superius'un kemikleştiği gözlemlendi. Anatomik varyasyonların klinik perspektifte tartışıldığı bu vaka takdimi, varyasyonların radyo-anatomik görüntülerinin omuz bölgesindeki tuzak nöropatilerin aydınlatılmasındaki önemini ortaya koymaktadır.

Anahtar Kelimeler : Incisura scapulae, multidedektörlü bilgisayarlı tomografi, tuzak nöropati, ligamentum transversum scapulae superius

Abstract

Entrapment neuropathies, also known as nerve compression syndrome or compression neuropathy, may be defined as the lesions of the peripheral nerves under exposure of any kind of physical stress, including any kind of traumas and inflammatory or edematous processes, on the route of the nerve to the target tissue. While performing a radiologic examination of multi-detector computerized tomography images of vascular structures in the right shoulder region of a 43 years old female Turkish patient who admitted to our hospital, we observed a complete ossification of the superior transverse scapular ligament. This case report, which is discussed in the clinical perspectives of anatomic variations, puts forth that radio-anatomic images about variations, like the one used in this report, are of importance while illuminating the etiopathologic background of entrapment neuropathies of the shoulder region.

Keywords: Suprascapular notch, Multi-detector computerized tomography, Entrapment neuropathy, Superior transverse scapular ligament

Introduction

On the superior border of the scapula which is the shortest margin, just medial to the coracoid process, a notch lies having different sizes and shapes in individuals. Several variations are described as to the shape of the suprascapular notch (1). This anatomic structure, the suprascapular notch, is arched by superior transverse scapular ligament (STSL) in order to create a passage containing the suprascapular nerve and defined as scapular foramen, if the ligament ossifies after roofing the notch in a portion of cases (2). This strong, thin and flat ligament clings to the base of coracoid process and ends at the medial border of the suprascapular notch. The suprascapular artery and vein passes over this – sometimes ossified – ligament while suprascapular nerve passes through the foramen. The studies were presented in literature detecting similar variations, using sonographic techniques or Magnetic Resonance Imaging (MRI) (3, 4). In this case report, entirely ossification of the STSL is described using Multidetector Computed Tomography (MDCT) images.

Case Report

While performing radiologic examination of MDCT images of vascular structures at the right shoulder region of a 43 years old female Turkish patient who admitted to our hospital, we observed a complete ossification of STSL. Patient had cardiologic complaints and had no complaints about peripheral nervous system. Dimensions of the foramen were measured, which was created by ossified STSL. Transverse and vertical diameter of the foramen was 4.47 mm and 8.57 mm, respectively. The scapula on the left side was not bearing any variational features (Figure).

Discussion: Compression of the suprascapular nerve passing scapular foramen causes a set of symptoms related to the paresis of the infraspinatus and supraspinatus muscles innervated by the suprascapular nerve when

STSL is ossified. Entrapment neuropathies, also known as nerve compression syndrome or compression neuropathy, may be defined as the lesions for the peripheral nerves under exposure of any kind of physical stress, including any kind of traumas and inflammatory or edematous processes, on the route of the nerve to the target tissue. Contrary to common thought that suprascapular entrapment neuropathy was first defined by Thompson and Kopell (5) in 1959, Pecina, Cummins (6) remind Andre Thomas' paper published in 1936 which provides the first description of suprascapular nerve entrapment syndrome (5, 6). However, detailed discussion of this issue was beyond the scope of this study.

Complaints of shoulder pain, muscle atrophy, weakness at the regional muscles and rigidity may occur, sometimes together, in individuals with the entrapment of the suprascapular nerve (7-9). Especially, weakness may be expected in anamnesis during external rotation and at the beginning of the abduction of the arm, which are the main functions of infraspinatus and supraspinatus muscles, respectively. Suprascapular nerve is under risk for injuries while traversing under not only bone bridge but also the STSL (10). Structural changes of the suprascapular notch predispose entrapment neuropathies, as well. Five different types of suprascapular notch were described (3). Variations of the suprascapular notch, combining with the ossification of STSL may exaggerate the complaints related to the entrapment of suprascapular nerve. Ossification of this ligament can be encountered about 10% (2). In the literature, many studies provided rates about existence of scapular foramen (Table)

Conservative treatment strategies are tending to be preferred for vast majority of the cases. For the purpose of treatment of cases with entrapment of the suprascapular nerve and with serious clinic reflections, not only open surgical approaches but also arthroscopic procedures are

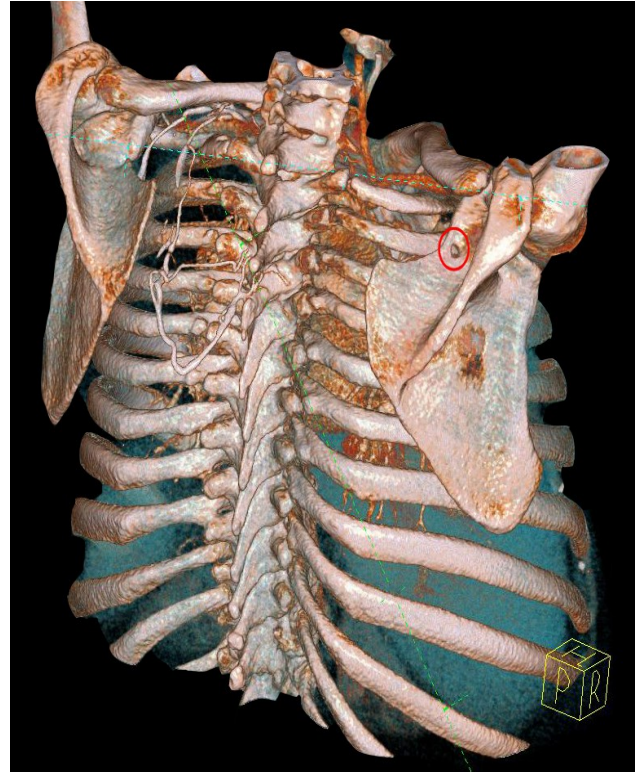
described as operative treatments as well as physical rehabilitation (11).

Awareness of the ossification of the STSL can help the clinicians to explain and treat some kind of chronic shoulder region symptoms after ruling out rotator cuff tears on account of complaint similarities. This case report, which is discussed in the clinical perspectives of anatomic variations, puts forth that radio-anatomic images about variations, like the one used in this report, are of importance while illuminating etiopathologic background of entrapment neuropathies of the shoulder region.

Table: Different rates from literature, indicating the existence of scapular foramen

Researcher	Number of scapulae included in study	Number of scapulae with scapular foramen	Rate
Wang, Chen (12)	295	4	1.3 %
Aydinlioglu, Diyarbakirli (13)	150	3	2%
Yang, Gil (14)	103	4	3.7 %
Bayramoglu, Demiryurek (15)	32	4	12.5 %

Figure: On 3D volume-rendered image, the scapular foramen on the right scapula (red circle)



References:

1. Hrdlička A. The adult scapula. Additional observations and measurements. *Am J Phys Anthropol.* 1942;29(3):363-415.
2. Prescher A. Anatomical basics, variations, and degenerative changes of the shoulder joint and shoulder girdle. *Eur J Radiol.* 2000;35(2):88-102.
3. Moriggl B. Grundlagen, Möglichkeiten und Grenzen der Sonographie osteofibröser Kanäle im Schulterbereich: Teil 1. *Ann Anat.* 1997;179(4):355-73.
4. Zeiss J, Woldenberg LS, Saddemi SR, Ebraheim NA. MRI of suprascapular neuropathy in a weight lifter. *J Comput Assist Tomogr.* 1993;17(2):303-8.
5. Thompson W, Kopell H. Peripheral entrapment neuropathies of the upper extremity. *New Engl J Med.* 1959;260(25):1261-5.
6. Pecina M, Cummins CA, Messer TM, Nuber

- GW. Who really first described and explained the suprascapular nerve entrapment syndrome? *J Bone Joint Surg.* 2001;83(8):1273-4.
7. Das S, Suri R, Kapur V. Ossification of superior transverse scapular ligament and its clinical implications. *Sultan Qaboos Univ Med J.* 2007;7(2):157-60.
8. Erginer R, Ogut T, Seyahi A, Dervisoglu S. Suprascapular nerve entrapment by a ganglion cyst: a case report. *Acta Orthop Traumatol Turc.* 2004;37(1):73-8.
9. Ozalay M, Akpınar S, Hersekli M, Ozkoc G, Tandogan RN. Spinoglenoid centik ganglionuna bağlı gelişen supraskapular sinir sikismasi: Olgu sunumu. *Acta Orthop Traumatol Turc.* 2002;36(1).
10. Cummins CA, Messer TM, Nuber GW. Current concepts review-Suprascapular nerve entrapment. *J Bone Joint Surg.* 2000;82(3):415-24.
11. Bhatia DN, de Beer JF, van Rooyen KS, du Toit DF. Arthroscopic suprascapular nerve decompression at the suprascapular notch. *Arthroscopy.* 2006;22(9):1009-13.
12. Wang HJ, Chen C, Wu LP, Pan CQ, Zhang WJ, Li YK. Variable morphology of the suprascapular notch: an investigation and quantitative measurements in Chinese population. *Clin Anat.* 2011;24(1):47-55.
13. Aydinlioglu A, Diyarbakirli S, Keles P, Yuceer N. Supraskapular centik degisiklikleri. *Turk Norosir Derg.* 1997;7:40-4.
14. Yang HJ, Gil YC, Jin JD, Ahn SV, Lee HY. Topographical anatomy of the suprascapular nerve and vessels at the suprascapular notch. *Clin Anat.* 2012;25(3):359-65.
15. Bayramoglu A, Demiryurek D, Tuccar E, Erbil M, Aldur M, Tetik O, et al. Variations in anatomy at the suprascapular notch possibly causing suprascapular nerve entrapment: an anatomical study. *Knee Surg Sports Traumatol Arthrosc.* 2003;11(6):393-8.