


## Surgical Treatment of Cranioschisis and Meningocele in a Newborn Calf

Kerem YENER<sup>1\*</sup> , Mehmet Salih KARADAĞ<sup>1</sup> , Kübra DİKMEN İLGİNOĞLU<sup>1</sup> ,

Mehmet Sıdık HURMA<sup>1</sup> 

<sup>1</sup>Harran University, Faculty of Veterinary Medicine, Department of Surgery, Şanlıurfa, Türkiye

\*Corresponding author: keremyener@harran.edu.tr

Received 06.11.2024

Accepted 15.12.2024

Published 31.12.2024

### Abstract

Congenital cranial diseases can be life-threatening and fatal in all animals. This case report aims to provide information about a meningocele case associated with cranioschisis observed in a 1-day-old Simmental male calf. Following clinical and radiographic examinations, the calf was diagnosed with cranioschisis and meningocele. After completing preoperative procedures, the patient was prepared for surgery. During the operation, an elliptical incision was made to remove the skin segment forming the swelling on the skull, and the cranial defect, measuring 4 cm in diameter, was closed by approximating the connective tissue in the area. No intraoperative complications were encountered. Postoperative evaluations conducted at the 2nd week and 2nd month revealed no neurological symptoms, and the calf's overall health status was good. In conclusion, this case report demonstrates that early intervention in small-scale defects and repair through tissue suturing can be successful. It also emphasizes the importance of considering surgical intervention over euthanasia in similar cases with a poor prognosis.

**Keywords:** Calf, cranial defect, cranioschisis, meningocele, surgery.

### Yenidoğan Bir Buzağda Kranioşizis ve Meningoselin Cerrahi Tedavisi

#### Öz

Konjenital kafatası hastalıkları tüm hayvanlarda yaşamsal riskler taşıyarak ölümlerle sonuçlanabilir. Bu olgu sunumu 1 günlük simental erkek buzağda karşılaşılan kranioşizise bağlı meningesel olgusu hakkında bilgi verilmesi amaçlanmıştır. Yapılan klinik ve radyografik muayeneler sonucunda buzağıya kranioşizis ve meningesel tanısı konuldu. Preoperatif işlemlerin ardından hasta operasyon için hazırlandı. Operatif işlemde kafatası üzerindeki şişliği oluşturan deri parçası eliptik bir enzisyon ile uzaklaştırılarak 4cm çaplarındaki kranial defekt bölgedeki bağ dokusu daraltılarak kapatıldı. İntraoperatif herhangi bir komplikasyon ile karşılaşılmadı. Postoperatif 2. hafta ve 2. ay kontrollerinde buzağın herhangi bir nörolojik bulgu göstermeyip genel sağlık durumunun iyi olduğu görüldü. Sonuç olarak, bu olgu sunumunda küçük çaplı defektlerde erken müdahale ve defektin doku dikişleri ile sağaltımında başarılı olunabileceği ve bunun gibi prognozu kötü hastalıklarda ötenazi yerine operatif işlemin değerlendirilmesinin önemli olabileceği sonucuna varıldı.

**Anahtar kelimeler:** Buzağı, kranial defekt, kranioşizis, meningesel, cerrahi.



## Introduction

Congenital deformities, such as meningoencephalocele, meningocele, encephalocele, encephalocele, anencephaly, hydrocephalus, and spina bifida, are defined as morphological and functional disorders resulting from neural tube defects during embryonic development. These anomalies can be observed in all animal species and may be hereditary or caused by various factors such as the consumption of toxic plants, viral infections, nutritional deficiencies, mycotoxins, and pesticides (Dantas et al., 2010; Santos et al., 2012; Boscarato et al., 2020; Cutler et al., 2006). These rare anomalies have been treated with different surgical approaches in calves and other animal species (Ahmadnejad et al., 2022; Krishna & Palli, 2016; Oliveira et al., 2014; Silva et al., 2023; Alonso et al., 2019).

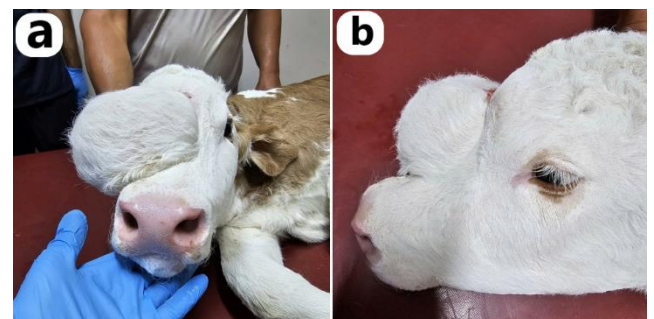
Cranioschisis is a malformation characterized by incomplete closure of the skull during embryological development and protrusion of the brain tissue through this opening (Cho et al., 2015). Meningocele occurs when the meninges, which contain cerebrospinal fluid (CSF), herniate through a defect in the skull (Boscarato et al., 2020). This anomaly has been reported in calves, lambs, foals, piglets, cats, dogs, and humans (Ahmadnejad et al. 2022). The lesions formed by herniated structures are mostly covered with skin and are approximately 2-10 cm in diameter. It has also been reported that the size of the hernia is always larger than that of the skull defect. (Cantile & Youssef, 2016). While meningoceles are mostly reported in the occipital and frontal regions (Cho et al., 2015), this condition has been reported differently in cattle in the parietal and frontal regions (Boscarato et al., 2020). The diagnostic process involves clinical examination and characteristic anatomopathological findings, revealing a deficiency in skull bones (Boscarato et al., 2020; Oliveira et al., 2009). Furthermore,

radiography and imaging modalities, such as tomography and magnetic resonance, can be used as complementary examinations to support the diagnosis (Boscarato et al., 2020; Nogueira et al., 2017).

The aim of this case report was to provide information about the diagnosis and treatment of meningocele associated with cranioschisis observed in a calf.

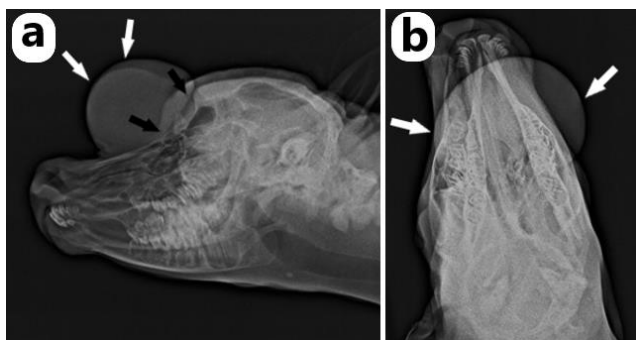
## Case Description

Our case involved a 1-day-old male Simmental calf weighing 45 kilograms. The calf was brought to the Harran University Animal Hospital Surgery Clinic with the complaint of a large fluid-filled swelling on the forehead. According to the anamnesis, the owner stated that the swelling was congenital; however, it did not affect the calf's nutrition or general condition, and the mass had remained the same size since birth. Clinical examination of the mass revealed fluctuating swelling following the median line from the supraorbital curve of the frontal bone to the midline of the nasal bones (Figure 1). When cranial and spinal reflexes were examined, it was determined that the swelling did not cause any neurological issues. The swelling was approximately 10x8x13.5 cm in diameter. In addition, a circular defect in the skull was detected on palpation of the root swelling.



**Figure 1.** In a 1-day-old calf, there is an increase in volume in the frontal region (a), characterized by a large mass extending along the median line from the supraorbital curve of the frontal bone to the midline of the nasal bones (b).

The radiographic images of the calf were taken in the laterolateral and dorsoventral positions to detect the presence of any other pathological findings. In the images obtained, a round and clearly demarcated mass with soft tissue-specific radiopacity was observed in the frontal bone near the skull (Figure 2). Approximately 120 ml of colloquio serosanguine-like transparent content was drained using a puncture procedure. It was observed that the mass shrunk as the fluid drained, and only an extra piece of skin remained. The contents were sent to the laboratory for analysis, and the presence of CSF was confirmed. At the end of all procedures, it was diagnosed that the calf's skull was swollen due to meningocele caused by a congenital cranioshisis defect.



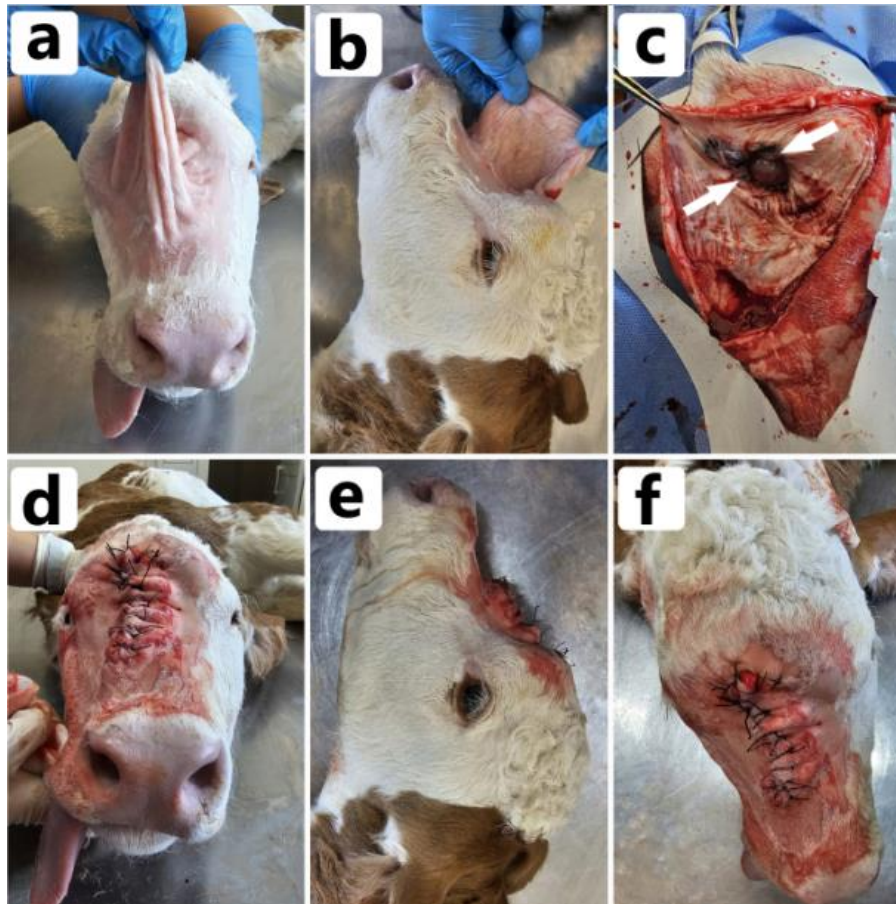
**Figure 2.** Lateral skull plain radiograph (a), dorsoventral radiograph (b). Showing the cranial defect (black arrows) and the hernial sac (white arrows).

Necessary information was provided to the patient owners, and the decision for the operative procedure was made. Accordingly, electrocardiogram (ECG), pulse rate (120), SpO<sub>2</sub> (92), etCO<sub>2</sub> (33), rectal temperature (38.7), and blood pressure (124/85) values were recorded using a mind-ray bedside monitor. Then, 3 ml of blood was collected from the vena jugularis separately for blood gas-electrolyte, hematologic, and biochemical evaluations. Blood gas electrolyte and hematochemical values were within the normal reference range. In addition, intraocular pressure (IOP) was measured using a tonovetplus (right eye IOP: 23 mmHg, left eye IOP: 25 mmHg). All values were within the reference range. Amoxicillin+clavulanic acid

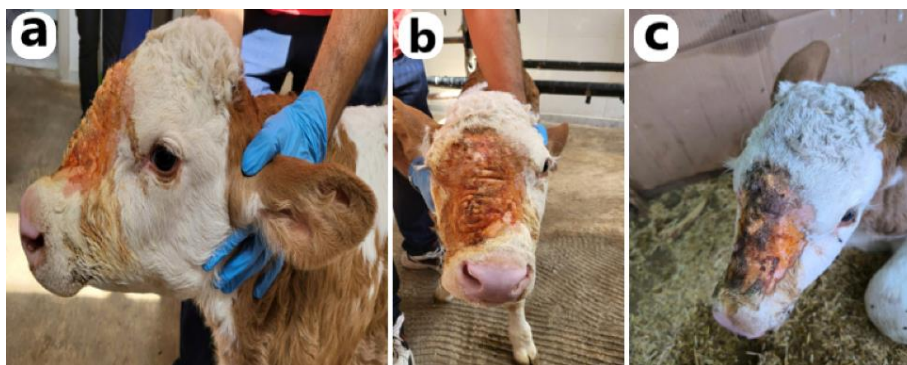(140+35 mg/ml, Synulox<sup>®</sup>, Pfizer, USA) was administered intramuscularly at a dose of 8.75 mg/kg body weight for prophylaxis during the preoperative period. For analgesic effect, meloxicam (20 mg/ml, Metacam<sup>®</sup>, Boehringer Ingelheim, Germany) was administered subcutaneously at a dose of 0.5 mg/kg body weight. Both preoperatively and during the operation, fluid support was provided via physiological saline through the jugular vein. Accordingly, the calf was pre-anesthetized with midazolam (0.1 mg/kg, intravenous (IV)) (15 mg/3 ml, Zolamid<sup>®</sup>, Vem İlaç, Turkey), and propofol (1.5 mg/kg, IV) (20 mg/mL, Propofol-PF MCT %2<sup>®</sup>, Polifarma, Turkey) was administered for induction. The calf was anesthetized with 2.5-3% sevofloran (Sevones<sup>®</sup>, Polifarma, Turkey) through endotracheal intubation and continued with 100% oxygen. After preparation for anesthesia, the calf was placed in the sternal position. After the aseptic application of the frontal region and sac, the skin was opened using a linear incision. After the skin was separated, a meningeal membrane protruding from the frontal opening, with a diameter of 4 cm, was observed in the cranium. This membrane, which looked similar to the internal hernial sac, was separated from the skin by blunt dissection. The meningeal membrane was resected, leaving sufficient tissue to allow for the closure of the inferior frontal defect later. The frontal defect was closed with polyglycolic acid (PGA) No. 1 suture using resected tissue with simple separate sutures. The skin was sutured with No.1 silk using a simple suture technique according to standard procedures (Figure 3). In the postoperative period, amoxicillin+clavulanic acid (140+35 mg/ml, Synulox<sup>®</sup>, Pfizer, USA) was administered as an intramuscular injection in body weight dose (8.75 mg/kg) once daily for 5 days, and meloxicam (20 mg/ml, Metacam<sup>®</sup>, Boehringer Ingelheim, Germany) was administered subcutaneously in body weight dose (0.5 mg/kg) once daily for 3 days. The calf showed uneventful

recovery in the 2nd week after surgery and it was observed that the 2nd and 3rd week follow-ups were satisfactory (Figure 4). Two months later, the calf showed a good nutritional status and no neurological signs. Postoperative evaluations at

the 2nd week and 2nd month showed that the blood gas, electrolyte, and hematochemical values were within the normal reference range.



**Figure 3.** Preparation of the area for surgery after drainage of the sac (a. b), a circular defect (white arrows) in the frontal bone (c), postoperative images of the suture area (d. e. c.).



**Figure 4.** Control images of the postoperative process for the 2nd (a. b) and 3rd weeks (c).

## Discussion

Congenital anomalies of the skull have been reported in different species using various surgical procedures. However, in many cases, it has been reported to result in the death of the animal within a short period of time (Alonso et al., 2019; Oliveira et al., 2014). In the present case report, surgical intervention for meningocele due to congenital cranioschisis in a calf yielded successful results. No complications were observed during follow-up. It has been reported that the use of ultrasound, X-ray and computed tomography for the diagnosis of meningoencephalocele and meningocele, which are congenital anomalies observed in the skull, is useful for the definitive diagnosis of the lesion (Back et al, 1991; Kohli & Naddaf, 1998; Ohba et al., 2008). In this case report, X-rays were used to detail the diagnosis of the lesion, and the observation of the defect in the frontal region and the radiopaque bulge arising from this defect were useful in finalizing the diagnosis.

In studies involving meningocele cases, it was reported that fluctuating swelling filled with CSF was drained before the surgical procedure in some studies, and in some studies, the procedures were performed without drainage. Additionally, the studies do not report any complications caused by fluid-filled masses during surgical procedures. (Boscarato et al., 2020; Krishna & Palli, 2016). In the present case, the operative procedure was performed by draining the CSF via puncture, and no complications were encountered.

In many studies on meningoceles, it has been reported that animals that were healthy in the preoperative period died in a short time due to neurological and septic complications in postoperative follow-up, and were even euthanized in some cases. For example, one study reported that in a case of meningocele observed in a foal, the animal was euthanized on the 13th

postoperative day owing to neurological complications (Alonso et al., 2019). In another case study, it was reported that the blood values of the lamb deteriorated significantly in the postoperative period, and the animal showed a general disorder and died on the 5th postoperative day (Ahmadnejad et al., 2022). In the present case report, all clinical and laboratory calf values were within the preoperative reference range. In the postoperative follow-up for 2 months, no complications were found in the calf, and the patient continued to live in a healthy manner. In light of these results, regular postoperative follow-up in cases with meningoencephalocele may prevent complications that may occur in the animal and increase the chance of survival. A calf with meningoencephalocele has been reported to have a circular defect with a diameter of 6 cm in the upper part of the median frontal line of the skull, and successful results were obtained without complications from skin suturing (Ohba et al., 2008). In another study, the aim was to create a new bone matrix using a cartilage graft to repair the defect in the parietal bone; however, apathy and seizures were reported to begin on the 13th day, ultimately resulting in death on the 15th day (Oliveira et al., 2014). In another case, cranioplasty using a polymethylmethacrylate plate was applied to a 5 cm diameter frontal opening in the treatment of meningocele-related cranioschisis, and satisfactory results were obtained 19 months after surgery (Silva et al., 2023). In another study, although the prognosis of the animal was not good, a 4.5 cm diameter frontal opening was surgically closed by suturing the edges of the meninges using a simple continuous suture method. This study did not yield the expected results, and resulted in euthanasia (Boscarato et al. 2020). From this study, it can be concluded that the general condition of animals with these anomalies is important to obtain favorable results in the postoperative period. A calf with a 7 cm diameter frontal defect closed without the use of a graft was

discharged 39 days later in a healthy condition without recurrence of deformity or CSF accumulation. These findings show that surgical treatment is effective and its use is recommended in similar cases (Nogueira et al., 2017). In our study, no material was used for the repair of a 4 cm diameter defect; the closure was achieved by suturing the meningeal membrane directly to the subcutaneous tissues. The sutures were removed in the 2nd week of the postoperative period, and no abnormalities were detected in the general examination. The nutritional status of the animals was quite good, and no neurological symptoms were observed. Similar findings were observed in controls performed two months later. In conclusion, closure of the defect with the surrounding tissues showed uncomplicated and short-term healing. The method of closure plays a significant role in prognosis, but the general health condition of the animal also greatly influences the healing process. Simple suture techniques usually provide positive results for smaller defects, while complex techniques involving grafts or synthetic materials may not always be successful, especially in animals with compromised health. This highlights the critical importance of carefully assessing and stabilizing the animal's overall condition before surgery to improve the chances of recovery.

## Conclusion

Despite the unfavorable prognosis of the disease current literature includes cases with good prognosis following surgical intervention. The preference for surgical intervention in the treatment of meningocele-associated cranioschisis has provided satisfactory results in terms of calf's quality of life and livestock sustainability. The cause of meningocele and cranioschisis in calves is not fully understood and further research is needed.

## Financial Support

This study did not receive a grant by any financial institution/sector.

## Ethical Statement

This study does not present any ethical concerns.

## Author Contributions

Investigation: K.Y. and M.S.K.; Material and Methodology: K.Y. and K.D.İ.; Supervision: M.S.K. and M.S.H.; Visualization: K.D.İ.; Writing-Original Draft: K.Y. and M.H.; Writing-review & Editing: K.Y.

## Conflict of Interest

The authors declared that there is no conflict of interest.

## Data Availability Statement

The data that support the findings of this study are available from the corresponding author upon reasonable request.

## References

- Ahmadnejad, M., Najamezhad, V., Hashemi-Asl, S. M., & Mohammadi, R. (2022). Cranium bifidum and meningocele in the caudal aspect of a lamb head. *Iranian Journal of Veterinary Surgery*, 17(1), 62-65. <https://doi.org/10.30500/ivsa.2021.274875.1254>
- Alonso, J. D. M., Pedro Filho, T. H., Ávila, A. R., Machado, V. M., Hataka, A., Bueno, L. M., ... & Watanabe, M. J. (2019). Surgical repair of an occipital meningocele in a foal. *Journal of Equine Veterinary Science*, 81, 102771. <https://doi.org/10.1016/j.jevs.2019.06.010>
- Back, W., Van Den Belt, A. J., Lagerweij, E., Van Overbeeke, J. J., & Van Der Velden, M. A. (1991). Surgical repair of a cranial meningocele in a calf. *Veterinary Record*, 128, 569-571. <https://doi.org/10.1136/vr.128.24.569>
- Boscarato, A. G., Pacheco, F. C., de Andrade, C. F. O., Jardim, G. F., de Oliveira, J. A. B., Ribeiro, R. D. C. L., & Alberton, L. R. (2020). Cranioschisis with

- meningocelis in newborn calf. *Acta Scientiae Veterinariae*, 48. <https://doi.org/10.22456/1679-9216.102030>
- Cantile, C., & Youssef, S. (2016). Nervous system. In Jubb, Kennedy, and Palmer's pathology of domestic animals (Vol. 1, 6th ed., pp.267–268). Elsevier Saunders, Philadelphia. <https://doi.org/10.1016/B978-0-7020-5317-7.00004-7>
- Cho, I. C., Park, Y. S., Yoo, J. G., Han, S. H., Cho, S. R., Park, H. B., & Kang, T. Y. (2015). Two cases of meningocele and meningoencephalocele in Jeju native pigs. *BMC Veterinary Research*, 11(89), 1-4. <https://doi.org/10.1186/s12917-015-0404-y>
- Cutler, R. S., Fahy, V. A., Cronin, G. M., & Spicer, E. M. (2006). Preweaning mortality. In: B. E. Straw, J. J. Zimmerman, S. D'Allaire, & D. J. Taylor (Eds.), *Diseases of swine* (9th ed., pp.1005-1006). Iowa: Blackwell Publishing.
- Dantas, A. F. M., Riet-Correa, F., Medeiros, G. J. N. G., Pimentel, L. A., Anjos, B. L., & Mota, R. A. (2010). Malformações congênitas em ruminantes no semiárido do Nordeste Brasileiro. *Pesquisa Veterinária Brasileira*, 30(10), 807-815. <https://doi.org/10.1590/S0100-736X2010001000002>
- Kohli, R. N., & Naddaf, H. (1998). Surgical treatment of cranial meningocele in Iranian calves. *Veterinary Record*, 142, 145. <https://doi.org/10.1136/vr.142.6.145>
- Krishna, N. V. V. H., & Palli, R. K. (2016). Surgical management of congenital meningoencephalocele in a newborn Jersey calf: A case report. *Journal of Advanced Veterinary and Animal Research*, 3(2), 192-194. <http://doi.org/10.5455/javar.2016.c143>
- Nogueira, D. B., Bastos, R. M., Rocha, L. M. S. B., Rocha, E. F., da Nóbrega Neto, P. I., de Miranda Neto, E. G., & da Silva, T. R. (2017). Correção cirúrgica como tratamento de meningocele associada à craniosquise em bezerro: relato de caso. *Medicina Veterinária*, 11(4), 222-226. <https://doi.org/10.26605/medvet-n4-1946>
- Ohba, Y., Iguchi, T., Hirose, Y., Takasu, M., Nishii, N., Maeda, S., & Kitagawa, H. (2008). Computer tomography diagnosis of meningoencephalocele in a calf. *Journal of Veterinary Medical Science*, 70, 829-831. <https://doi.org/10.1292/jvms.70.829>
- Oliveira, D., Medeiros, J., Araújo, A., Pimentel, L., Pierezan, F., Neto, E., et al. (2009). Pulmonary choristoma associated with calf meningocele. *Ciencia Rural*, 39(9), 2652–2654. <https://doi.org/10.1590/S0103-84782009000900045>
- Oliveira Filho, J. P., Badial, P. R., Oliveira, A. P., Alvarez, L. E. C., & Costa, J. L. O. (2014). Cranioplasty for repair of cranioschisis associated with meningocele in a Jersey calf. *Veterinária e Zootecnia*, 21(3), 392-398.
- Santos, J. R. S., Dantas, A. F. M., & Riet-Correa, F. (2012). Malformations, abortion, and embryonic death in sheep caused by the ingestion of *Mimosa tenuiflora* (Leguminosae). *Pesquisa Veterinária Brasileira*, 32(11), 1103-1106. <https://doi.org/10.1590/S0100-736X2012001100005>
- Silva, N. V. D., Delfiol, D. J. Z., Horr, M., Saut, J. P. E., & Nogueira, G. M. (2023). Use of polymethylmethacrylate plaque as a treatment of cranioschisis associated with meningocele in a Girolando heifer: A case report. *Ciência Animal Brasileira*, 24, e-74519. <https://doi.org/10.1590/1809-6891v24e-74519E>