

Total Lower Eyelid Reconstruction Due to Clear Cell Hidroadenocarcinoma

 İhtişam Zafer Cengiz¹,  Rana Kapukaya²,  Gazi Kutalmış Yaprak³

1 Department of Plastic and Reconstructive Surgery, Atlas University Hospital, Istanbul, Türkiye

2 Department of Plastic and Reconstructive Surgery, University of Health Sciences Adana City Research and Training Hospital, Adana, Türkiye

3 Department of Plastic and Reconstructive Surgery, Medical Park Adana Hospital, Adana, Türkiye

Abstract

Aim: To discuss the surgical management of near-total defects due to clear cell hidroadenocarcinoma, a rare tumor of the lower eyelid, and to contribute to the limited literature on reconstruction options in this area.

Methods: A 93-year-old female patient presented with a rapidly growing lesion on her left lower eyelid. Histopathological examination confirmed a diagnosis of malignant clear cell hidroadenocarcinoma. The tumor was excised with wide total excision under general anesthesia. The resultant defect was reconstructed using a full-thickness mucosal graft from the soft palate and a Mustarde cheek advancement flap. Postoperative medial canthus revision was performed with a local flap.

Results: Postoperative follow-ups revealed complete eyelid closure and sufficient tear drainage. Functional and aesthetic outcomes were satisfactory. Due to the patient's advanced age and general condition, no radiotherapy or chemotherapy was applied, and a follow-up process was recommended.

Conclusion: Clear cell hidroadenocarcinoma is a rare and aggressive malignant tumor. Mustarde cheek advancement flap is a suitable option for repairing extensive defects in the lower eyelid, especially in elderly patients, as it provides adequate tissue support. Detailed reporting of such cases contributes to the literature and aids in the management of this rare tumor.

Keywords: Clear cell hidroadenocarcinoma, lower eyelid reconstruction, Mustarde flap

1. Introduction

Due to the anatomy and functions of the lower eyelid, reconstruction options are quite limited. The goals in total full-thickness lower eyelid defect repair include maintaining the continuity of the lateral and medial canthi, tarsus, and posterior lamella, providing a drainage canal for tears, and repairing the dermis and hypodermis. Postoperatively, functional repair can be deemed successful if the upper and lower eyelids completely close when the eye is shut, and tear drainage to the inferior fornix is maintained.

Full-thickness losses exceeding 75% of the lower eyelid are rare. In elderly patients, nearly total lower eyelid defects are mostly caused by malignancies¹. Among malignant causes, basal cell carcinoma is the most common². As a low-grade tumor, basal cell carcinoma rarely shows extensive infiltration or nodular metastatic involvement. Clinicians should consider rare tumors like hidroadenocarcinoma and eccrine porocarcinoma in the differential diagnosis when encountering rapidly growing, malignant masses in the lower eyelid.

2. Case


A 93-year-old female presented to our center with complaints of a growing mass on her left lower eyelid. The patient reported that the lesion had developed over two years but had begun to grow rapidly in the last four months. She led a Mediterranean lifestyle as a farmer and had been exposed to sunlight extensively since childhood.

At the initial examination, the tumor measured 12 mm in diameter (Figure 1). By the time of surgery, the tumor had grown to 35 mm in diameter (Figure 2), with 15 days elapsed between the initial examination and the surgery. Macroscopically, the mass appeared raised, erythematous, with a central ulcer and crusted surface. The lesion had shown a slow growth pattern for the first two years but began to grow rapidly in the last four months, with associated pain reported in the last month.

MRI with contrast revealed full-thickness infiltration of the left lower eyelid, while the globe remained intact. Bilateral lymphatic involvement was observed in the cervical chain. No evidence of pulmonary metastasis was noted on direct radiographic imaging. The patient was discussed at a preoperative multidisciplinary oncology board meeting. A total wide excision of the mass was planned with subsequent treatment based on the pathological diagnosis.

2.1. Surgical Technique

Under general anesthesia, the patient underwent a wide total excision of the mass, followed by near-total lower eyelid recon-

Corresponding Author: İhtişam Zafer Cengiz, drizafercengiz@hotmail.com, Received: 18.12.2024, Accepted: 30.12.2024, Available Online Date: 31.12.2024 Cite this article as: Cengiz İZ, Kapukaya R, Yaprak GK. Total Lower Eyelid Reconstruction Due to Clear Cell Hidroadenocarcinoma. J Cukurova Anesth Surg. 2024; 7(4): 252-4. <https://doi.org/10.36516/jocass.1603662> Copyright © 2024 This is an open access article distributed under the terms of the Creative Commons Attribution-Non-Commercial-No Derivatives License 4.0 (CC-BY-NC-ND), where it is permissible to download and share the work provided it is properly cited. The work cannot be changed in any way or used commercially without permission from the journal. 

struction (Figure 3). Continuity of the conjunctiva was achieved using a full-thickness mucosal graft harvested from the soft palate (Figure 4). Conjunctival sutures were placed using 5.0 vicryl rapid in a continuous manner. The donor site was covered with Surgicel and closed with absorbable sutures. A simultaneous dacryocystorhinostomy was planned but could not be performed as the distal duct could not be explored following tumor excision. The entire defect was repaired using a cheek advancement flap. Medial canthopexy was achieved by securing the conjunctival graft to the periosteum at the medial canthus. Postoperatively, the patient was prescribed oral antibiotics and analgesics for one week. The eye was covered with a sterile dressing, which was changed daily. Sutures were removed on postoperative day 10. Medial canthus revision was planned due to a 5 mm x 1 cm distal flap necrosis. Reconstruction was completed using a local flap rotated from the nasal dorsum (Figure 5). Postoperative care included upward massage of the cheek and lifelong artificial tear use 3–4 times daily. Follow-up visits every six months were recommended. Subsequent evaluations revealed no eyelid gap in the closed state, and functional restoration was achieved.

Figure 1 Initial appearance of the tumor during the first clinical examination.

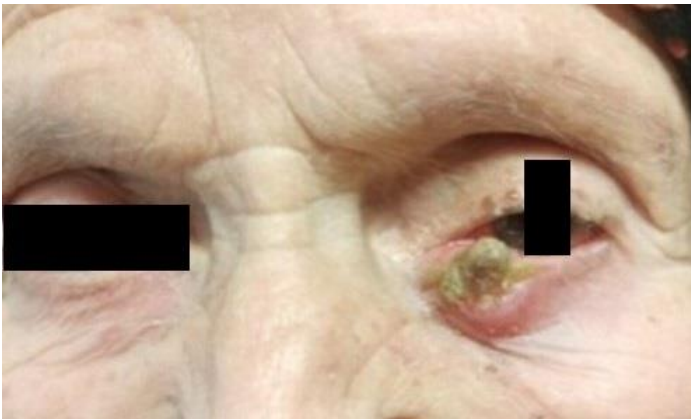


Figure 2 Rapid growth of the tumor within 15 days before surgery

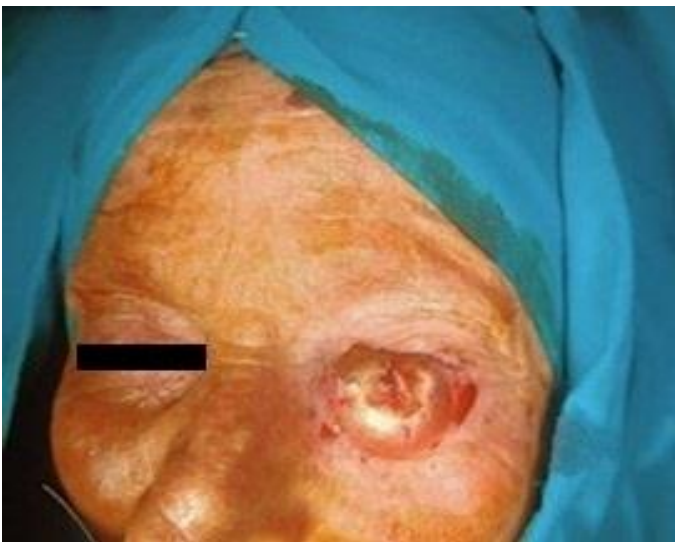

Figure 3 Intraoperative image showing the reconstructed defect after the Mustarde cheek advancement flap was applied

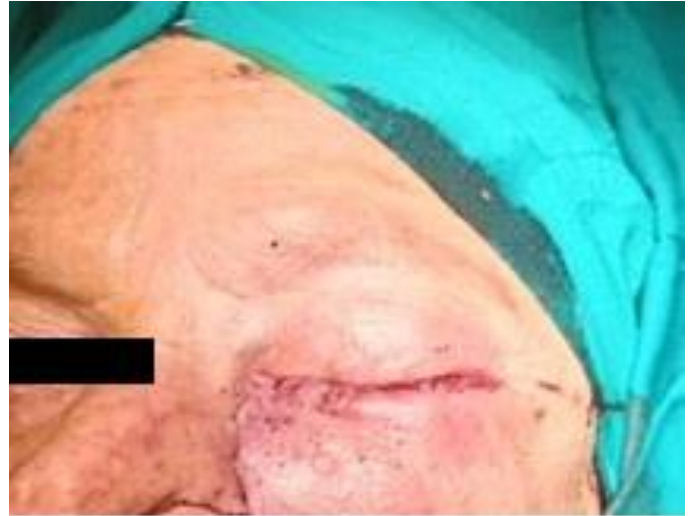
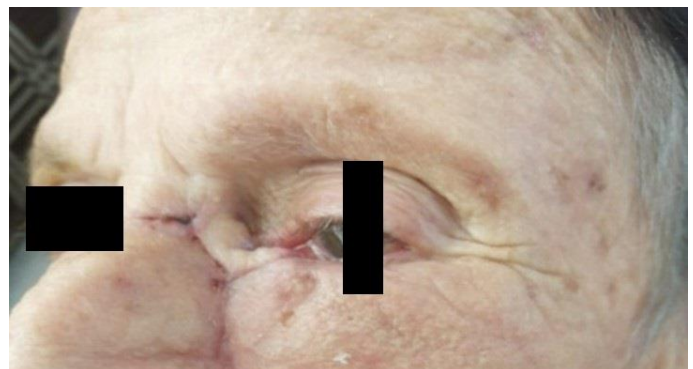


Figure 4 Soft palate mucosal graft used to reconstruct the posterior lamella of the lower eyelid

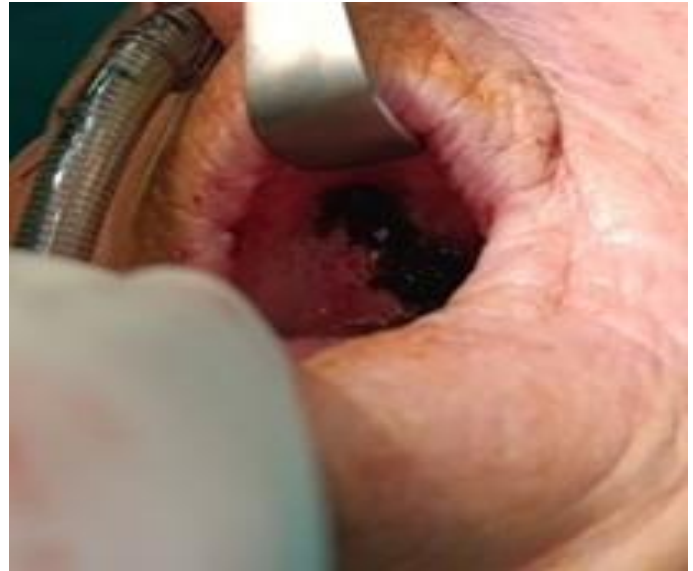

Figure 5 Post-revision image after medial canthus repair using a local flap rotated from the nasal dorsum



2.2. Histopathological Examination

Histopathological evaluation confirmed malignancy. Immunohistochemical staining results included CK7(+), CD10(+), P53(+), CK20(-), EMA (focal positive), PANCK (+), BERP4(-), ANDROGEN (artefactual), S-100(-), PAX8(-), and Ki-67 (60–70%). Based on histomorphological and immunohistochemical findings, the diagnosis remained inconclusive between clear cell hidroadenocarcinoma and eccrine porocarcinoma. Multidisciplinary oncology board evaluation was recommended. The surgical margins were clear with 4 mm of healthy tissue laterally, medially, and inferiorly.

2.3. Treatment

Due to the patient's advanced age, chronic sun exposure, and the tumor's locally aggressive and metastatic nature, a diagnosis of clear cell hidroadenocarcinoma was favored. Radical neck dissection, low-dose chemotherapy, and localized radiotherapy were deemed unsuitable given the patient's age and general condition. The patient was placed under surveillance for follow-up.

3. Discussion

Numerous techniques have been described for repairing lower eyelid defects exceeding 75%. Bilateral pedicle flap transfers from the upper eyelid are suitable for elderly patients but are impractical for large tissue defects³. Cheek advancement flaps are highly effective for extensive defects^{4,5}. For defects near the medial canthus, a composite island flap with a reverse-flow angular artery pedicle from the lateral nasal dorsum offers a three-layered (mucosa, cartilage, skin) repair⁶. However, this technique has limitations, such as flap thickness and donor site constraints. The auriculotemporal artery perforator temporal fascia island flap should be considered for large defect repairs⁷.

In this case, the defect measured approximately 45 mm x 45 mm. The patient's elderly and frail condition provided a large, sagging soft tissue reservoir in the malar region. Due to the defect size, a Mustarde cheek advancement flap was deemed the most appropriate reconstruction option.

For conjunctival repair of the lower eyelid, the soft palate mucosa is an excellent option due to its sufficient size for grafting⁸. Posterior lamella reconstruction using buccal mucosa grafts has been associated with high graft loss rates⁹. Auricular cartilage, tendon, and even temporal fascia are ideal donors for tarsus reconstruction^{10,11,12}.

However, successful three-layered reconstruction requires the continuity of the orbicularis muscle. Without muscle integrity, posterior lamellar grafts are at risk of ischemia and subsequent loss.

4. Conclusions

Hidroadenocarcinoma is a rare, locally aggressive tumor. Detailed reporting of rare cases is essential for building a network of knowledge regarding the disease's course and treatment. Due to the anatomy of the lower eyelid, achieving total functional reconstruction in this region is challenging. For total and full-thickness lower eyelid defects, the Mustarde cheek advancement flap offers an excellent tissue support option, particularly in elderly patients.

Declaration of patient consent

The authors certify that they have obtained all appropriate patient consent forms. In the form the patient has given her consent for his/her/their images and other clinical information to be reported in the journal. The patient understand that her name and initials will not be published and due efforts will be made to conceal their

identity, but anonymity cannot be guaranteed.

Source of Finance

The authors declare that they have received no financial support for this study

Conflict of interest statement

The authors declare that they have no conflict of interest.

References

- Altın Ekin M, Karadeniz Uğurlu Ş. Alt Ve Üst Göz Kapağı Tam Kat Defektlerinin Rekonstrüksiyon Sonuçları: 10 Yıllık Tek Merkez Deneyimi. *İstanbul Tıp Fakültesi Derg.* 2020;84(1):83-91. <https://doi.org/10.26650/IUITFD.2019.0083>
- Kapukaya R, Çiloğlu O. Evaluation of the demographic and clinical features of skin cancers: a single-center experience. *Eur J Ther.* 2020;26(3):214-7. <https://doi.org/10.5152/EurJTher.2020.20016>
- Elliot D, Britto JA. Tripiet's innervated myocutaneous flap1889. *Br J Plast Surg.* 2004;57(06):543-9. <https://doi.org/10.1016/j.bjps.2004.02.021>
- Mutaf M, Temel M. A New Technique for Total Reconstruction of the Lower Lid. *Ann Plast Surg.* 2017;78(2):171-7. <https://doi.org/10.1097/SAP.0000000000000862>
- Mustardé JC. Major reconstruction of the eyelids: functional and aesthetic considerations. *Clin Plast Surg.* 1981;8(02):227-36. [https://doi.org/10.1016/S0094-1298\(20\)30449-1](https://doi.org/10.1016/S0094-1298(20)30449-1)
- Keçeci Y, Bali ZU, Ahmedov A, Yoleri L. Angular artery island flap for eyelid defect reconstruction. *J Plast Surg Hand Surg.* 2019;54(1):1-5. <https://doi.org/10.1080/2000656X.2019.1647851>
- Yamashita K, Yotsuyanagi T, Sugai A, et al. Full-thickness total upper eyelid reconstruction with a lid switch flap and a reverse superficial temporal artery flap. *J Plast Reconstr Aesthetic Surg.* 2020;73(7):1312-7. <https://doi.org/10.1016/j.bjps.2020.02.017>
- Hendriks S, Bruant-Rodier C, Lupon E, Zink S, Bodin F, Dissaux C. Damak mukozal greft: Kapsamlı tam kalınlıkta göz kapağı rekonstrüksiyonunda yeterli posterior lameller rekonstrüksiyon. *Ann Chir Plast Esthet.* 2020;65:61-697. <https://doi.org/10.1016/j.anplas.2019.01.007>
- Gixti A, Malhotra R. Periorbital rekonstrüksiyonda oral mukoza grefti. *Orbit.* 2018;37:411-428. <https://doi.org/10.1080/01676830.2018.1435693>
- Yamamoto N, Ogi H, Yanagibayashi S, et al. Eyelid Reconstruction Using Oral Mucosa and Ear Cartilage Strips as Sandwich Grafting. *Plast Reconstr Surg Glob Open.* 2017;5:e1301. <https://doi.org/10.1097/GOX.0000000000001301>
- Iwanaga H, Nuri T, Okada M, Ueda K. Functional reconstruction of total upper eyelid defects with a composite radial forearm-palmaris longus tenocutaneous free flap: A report of two cases. *Microsurgery.* 2019;39:559-562. <https://doi.org/10.1002/micr.30410>
- Kim YS, Lee NH, Roh SG, Shin JY. Reconstruction of a total defect of the lower eyelid with a temporoparietal fascial flap: a case report. *Arch Craniofacial Surg.* 2022;23(1):39-42. <https://doi.org/10.7181/acfs.2021.00591>