



Spontaneous Subcutaneous Orbital Emphysema Following Sneezing

Hapşırma Sonrası Spontan Subkutanöz Orbital Amfizem

Ataman Köse¹, Beril Köse², Dağhan Işık³

¹Mersin University Faculty of Medicine, Department of Emergency Medicine, MERSİN

²Mersin Toros State Hospital, Department of Emergency Medicine, MERSİN

³Yüzüncü Yıl University Faculty Of Medicine, Department of Plastic And Reconstructive Surgery, VAN

Cukurova Medical Journal 2015;40(1):193-194.

A previously healthy 55-year-old man presented to the emergency department with a sudden onset of mild pain in the right eye and swelling after an episode of sneezing. He denied diplopia or any other visual changes after the swelling took place, but had difficulty opening his eyes from ptosis and swelling of the upper eyelid. There was no history of sinusitis, facial trauma or previous surgery. Furthermore, he did not have any symptoms related to dental or upper respiratory tract infections, insect bites, or open wounds. Vital signs of the patient were normal. On physical examination, there was mild ecchymosis, periorbital swelling, ptosis associated with crepitus on palpation in the around of the right eye (mostly in the right upper eyelid) without localized heat or tenderness (Figure. 1). An ophthalmologist as urgently consulted after reviewing physical examination findings. On ophthalmologic examination, the visual acuity, pupillary light reactions, extraocular movements, and the funduscopic examination were normal. Other systems examinations were also normal. CT revealed subcutaneous air right superior orbit without fracture in the orbit (Figure. 2). The patient was managed conservatively with non-steroidal antiinflammatory drug, and advised avoidance of nose blowing, sneezing or perform

activities that might elevate sinus pressures. He was discharged for the outpatient treatment and followed-up during two weeks. Two week later, on follow-up, the subcutaneous emphysema gradually resolved without any complications.

Orbital emphysema is an uncommon condition in the absence of facial trauma, previous surgery, insect bites, open wounds or sinusitis¹. In rare instances, it is observed after spontaneous, atraumatic causes such as nose blowing, sneezing or during air travel^{1,2}. These conditions (such as sneezing) may lead to a sudden increase in intranasal pressure, causing the defect in the lamina papyracea and subsequently allowing air to enter the surrounding orbital tissue (orbital emphysema)²⁻⁴. In most patients, orbital emphysema usually resolves in a week or 2, without adverse sequelae^{3,4}. Patients should be counseled to avoid activities that raise intranasal pressure such as nose blowing, sneezing, diving in pools, and flying on airplanes. All patients should have close follow-up and careful observation with physicians^{2,4}.

In conclusion, orbital emphysema may occur spontaneously after unexpected events such as sneezing in the absence of trauma. The aim of this presentation is to bring awareness to physicians of this uncommon condition, and a relatively simple

treatment is advised (i.e. careful observation and close follow-up).

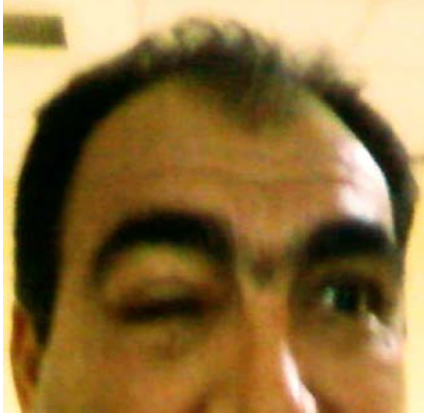

Figure 1. Physical examination findings. Mild ecchymosis, periorbital swelling, ptosis in the around the right eye (mostly in the right upper eyelid).

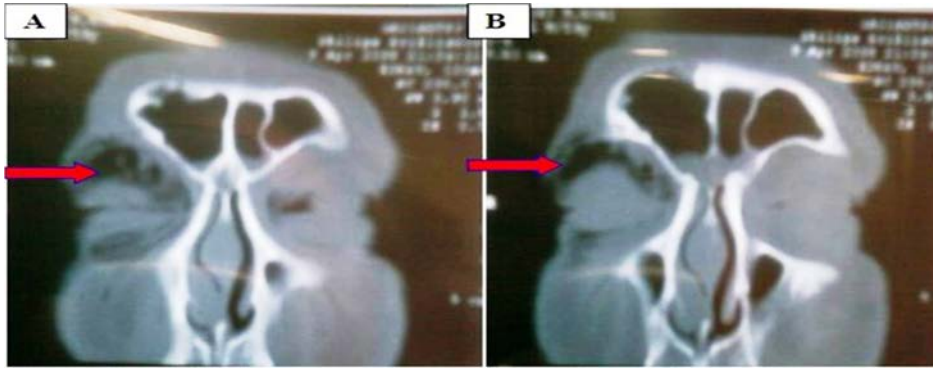


Figure 2. A and B CT scan show subcutaneous emphysema in the right superior orbit without fracture in the orbit (red arrows)

REFERENCES

1. Gonzalez F, Cal V, Elhendi W. Orbital emphysema after sneezing. *Ophthal Plast Reconstr Surg.* 2005;21:309-11.
2. Rosh AJ, Sharma R. Orbital emphysema after nose blowing. *J Emerg Med.* 2008;34:327-9.
3. Chiu WC, Lih M, Huang TY, Ku WC, Wang W. Spontaneous orbital subcutaneous emphysema after sneezing. *Am J Emerg Med.* 2008;26:381.e1-2.
4. Yüce İslamoğlu Y, Mülazimoğlu S, Özgürsoy OB. Unilateral Orbital Emphysema after Nose Blowing. *Cukurova Medical Journal.* 2014;39:876-9.

Yazışma Adresi / Address for Correspondence:

Dr. Ataman Köse
Mersin University Faculty of Medicine
Department of Emergency Medicine
E-mail: ataberk76@yahoo.com.tr

Geliş tarihi/Received on : 17.08.2014

Kabul tarihi/Accepted on: 22.09.2014