



### Aggressive Angiomyxoma of the Vulva: a Distinct Clinical Entity

Vulvar Agresif Anjiomiksom: Farklı Bir Klinik Tablo

Sevgi Bakaris<sup>1</sup>, Alparslan Osdarendeli<sup>2</sup>

<sup>1</sup>Kahramanmaraş Sutcuimam University, School of Medicine Department of Pathology, KAHRAMANMARAŞ

<sup>2</sup>State Hospital Kahramanmaraş Obstetrics and Gynecology, KAHRAMANMARAŞ

*Cukurova Medical Journal 2015;40(4):803-806.*

#### ABSTRACT

Aggressive angiomyxoma is a rare mesenchymal tumour arising from connective tissue of the perineum or the lower pelvis, and affect predominantly young women. Our case was 20-year-old female who was operated for a vulvar mass clinically misdiagnosed as Polyp . Histopathological examination of the surgical specimen revealed, haphazardly scattered spindle or stellate shaped mesenchymal cells and vessels of medium size having dilated lumens within a loose hyposellular myxoid stroma No mitoses were evident. The spindle-or stellate-shaped tumor cells were diffusely positive for vimentin, but negative for cytokeratin, S-100 protein, and myoglobin and  $\alpha$ -smooth muscle actin by immunohistochemistry. These histologic and immunohistochemical findings were compatible with diagnosis of AA. Clinically AA is mixed with Bartholin's duct cyst, vulvar abscess, lipoma, vaginal cysts in diagnosis AA of the vulva must be distinguished from the more common benign and malignant myxoid tumors including myxoma, myxoid neurofibroma, pseudosarcoma, myxoid liposarcoma, myxoid leiomyosarcoma and other soft tissue tumors with secondary myxoid changes.

**Key words:** Aggressive angiomyxoma, vulva.

#### ÖZET

Agresif anjiomiksom (AA), çoğunlukla genç kadınları etkileyen ve alt pelvis veya perinenin konnektif dokusunda ender olarak saptanan mezenchimal bir tümördür. Yirmi yaşındaki kadın olgumuz klinik olarak vulvar polip ön tanısıyla opere edildi. Ameliyat materyalinin histopatolojik incelemesinde, gevşek, hiposellüler miksoid stroma içerisinde iğsi şekilli, dar eozinofilik sitoplazmalı stromal hücrelerin rastgele dağıldığı ve belirgin, orta büyüklükte, geniş lümenli damar yapılarının yer aldığı gözlemlendi. Mitoz izlenmedi. İmmunohistokimyasal olarak stromal hücrelerde vimentin diffüz pozitif, sitokeratin, S-100 protein, myoglobulin ve düz kas atin (SMA) için negatif yanıt gözlemlendi. Bu bulgular AA tanımızla uyumluydu. Klinik olarak tanıda AA; bartolin kisti, vulvar abse, lipoma ve vajinal kist ile karışır Miksoma, miksoid nörofibroma, psodosarkom, miksoid liposarkom, miksoid leiomyosarkom, ve diğer sekonder miksoid değişikli benign ve malign yumuşak doku tümörlerinden ayırt edilmelidir.

**Anahtar kelimeler:** Agresifanjiomiksom, Vulvar

#### INTRODUCTION

Aggressive angiomyxoma (AA) of the pelvis, described by Steeper and Rosai in 1983, is a neoplasm that chiefly involves the vulval and

perineal region of young women<sup>1</sup>. AA characteristically grows slowly and insidiously, has no capsule and is locally infiltrative<sup>2</sup>. Despite its benign histological appearance, and although it

does not metastasize, the neoplasm exhibits a pronounced tendency for multiple local recurrences. Because of its infiltrative behavior, complete surgical excision is difficult, and a multiple recurrences occur in 70% of cases, often within a few years. Clinical presentation may resemble other benign conditions such as a Bartholin's cyst, obturator hernia or pelvic abscess<sup>1,2</sup>. Hence pre-operative diagnosis is often not established and the tumors are frequently misdiagnosed at presentation. Treatment typically involves surgery.

We describe an unusual case of AA of the vulva complicated by a severe infection of the tumor. The initial diagnoses was different from the operative diagnoses.

### CASE REPORT

A 20- year-old woman presented with increasing swelling of the vulva, which was clinically thought to be a polyp, and a fever of unknown origin. Laboratory tests found leukocytosis. On examination a globular mass of 6x5x4 cm. size was seen arising from the left labium majus in its middle part. The surface of the tumor was ulcerated heavily, and it bled on contact. The rest of the external genitalia and bimanual pelvic examination were normal. She had no menstrual abnormalities. Antibiotics were given following bacterial culture of the ulcerated tumor surface. Under general anesthesia, the patient

underwent a detailed evaluation and complete tumor resection, including local excision of the left vulva. The cut surface of resected tumor had a diffuse gelatinous appearance. Histologically the superficial, ulcerated area showed layers of necrotic tissue and acute inflammatory exudate (Figure1). Vascularization was abundant just beneath the epidermis with variably sized vessels, ranging from small thin-walled capillaries to larger vessels with medial hypertrophy. and the extremely loose myxomatous stroma surrounding them. In the deeper parts of the tumor, spindle-or stellate-shaped mesenchymal cells, exhibiting neither significant nuclear atypia nor mitotic figures, were distributed loosely within a diffuse myxomatous background (Figure2). Cellularity was low and quite uniformly distributed, with an increase around some vessels. Cells had round or oval nuclei, with small, centrally located nucleoli. The spindle-or stellate-shaped tumor cells were diffusely positive for vimentin, but negative for cytokeratin, S-100 protein, and myoglobin and  $\alpha$ -smooth muscle actin by immunohistochemistry. These histologic and immunohistochemical findings were compatible with diagnosis of AA.

The surgical borders of the specimen were positive for tumor. Therefore, a second wider excision was carried out with the tumor negative margins. After the procedure, her fever dropped. The patient had no post operative problem and is free of recurrence on follow up at 5 year.

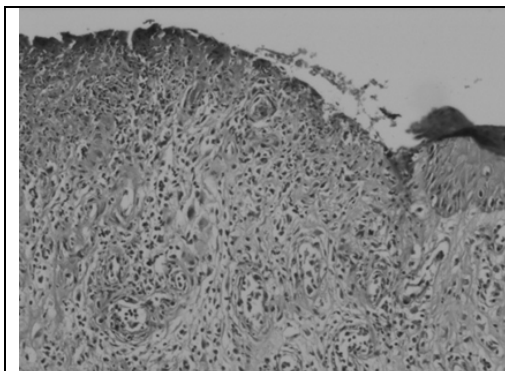


Figure 1. Aggressive angiomyxoma. Photomicrograph showing superficial, ulcerated area (HE X40)

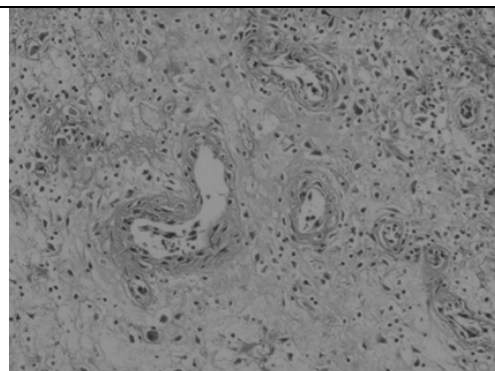


Figure 2. Aggressive angiomyxoma. Spindle, stellate-shaped cells are distributed in a myxoid stroma. Prominent vessels are apparent. (HE X20).



## DISCUSSION

AA is a locally infiltrative, but non-metastasising, lesion chiefly involving the vulvar and perineal region of women and girls during the reproductive years. The term "aggressive" was chosen in the view of the neoplastic nature of the blood vessels, locally infiltrative and recurrent character<sup>1</sup>. The ischioanal fossa, perineum, pelvis and retroperitoneum are the common sites of recurrence. Clinically the mass is often misdiagnosed as a vulvar mass, vulvar abscess, lipoma, Gartner's duct cyst, Bartholin's duct cyst or abscess, vaginal cyst, vaginal prolapse, obturator and levator hernia, hernia of the canal of Nuck or as an ill-defined swelling in the pelvic space<sup>2</sup>. In our case, the clinical diagnosis was vulvar polyp. Misdiagnosis of this tumor is a common problem. The final diagnosis of AA is confirmed on histopathology. On gross examination these tumors are characteristically soft, bulky masses measuring between 3 and 60 cm in its greatest dimension. The external surface is smooth and usually appears not to be encapsulated as was seen in our case<sup>2</sup>. The ulceration of the skin covering the tumor might have been important in the development of the infection.

The abundant vessels present just beneath the epidermis, and the extremely loose myxomatous stroma surrounding them, might have promoted the spread of infection. The cut surface reveals a glittering grey tumor of homogenous consistency with focal areas of congestion and hemorrhage. Differential diagnosis of the tumor includes myxoma, myxoid neurofibroma, pseudosarcoma, myxoid liposarcoma and myxoid leiomyosarcoma. The term angiomyxoma refer to the microscopic appearance of the tumor, resembling that of a myxoma with a well developed vascular component. None of the other myxoid tumors have a prominent vascular component. Histologically, differentiation from fibroma, fibroangioma, neurofibroma, lymphangioma,

sclerosing hemangioma, myxoma, myxoid neurofibromas, myxoid liposarcoma or fibrosarcomas, myxoid leiomyosarcoma, sarcoma botryoides, embryonal rhabdomyosarcoma, vaginal botryoid pseudosarcoma and myxoid type malignant fibrous histiocytoma may be difficult<sup>2</sup>. In contrast to AA, the distinctively prominent vascular pattern is usually absent in most of these tumors. A recently described tumor labelled as angiofibroblastoma closely mimics AA on histopathology. Distinguishing features of angiofibroblastoma are a well circumscribed border, much higher cellularity, more numerous blood vessels, minimal stroma and rarity of erythrocyte extravasation. There is no recurrence in angiofibroblastoma. AA often recur but do not metastasize. Misdiagnosis is seen in 82% of the cases<sup>2</sup>. A correct preoperative diagnosis is rarely made, thus the assessment of perineal and pelvic involvement is not done routinely. If possible a wide surgical excision to tumor free margins is the basis of curative treatment. Recurrence may occur several years after excision and long term follow up is necessary in these patients Two factors may contribute to the high rate of multiple local recurrences (36-72%). Firstly, the tumor is not diagnosed or imaged before initial surgery and the extent of the tumor is frequently not recognized leading to incomplete resection. Secondly, the strategic location of the tumor close to the urethra, vagina, anal sphincter and rectum with extension above and below the pelvic diaphragm, makes complete resection difficult.

The etiology of AA is undetermined. Rotmentsh et al.<sup>3</sup> have reported immunohistochemical analysis of hormone receptors and proliferative cell nuclear antigens in two cases of angiomyxoma to establish the etiology. Cytogenetic and molecular analysis carried out by Kazmierczak et al.<sup>4</sup> has revealed chromosomal aberrations involving the break point chromosomal region 12q<sup>4,5</sup>. Possible hormone dependency of this tumor has been reported by its

growth during pregnancy in a patient, the tumor was positive for progesterone receptors on immunohistochemical study<sup>5</sup>. In addition, several reports have demonstrated estrogen receptor (ER) and/or progesterone receptor (PR) positivity within this neoplasm, either by immunohistochemistry or by direct assay<sup>2</sup>. These studies may have a role in the work up and follow-up of a patient or if recurrence of angiomyxoma is suspected.

Excision of tumor with wide tumor-free margins seems to be the best therapeutic means for preventing recurrence of AA. However, sometimes patients with clear resection margins develop recurrence. Second wider excision has been advocated after primary resection<sup>2</sup>. Preoperative counseling is important because of the possibility of incomplete excision. When multiple organ systems are involved, surgical management may be accomplished with a multidisciplinary team. Due to the low mitotic activity, it is unlikely that radiation therapy or chemotherapy will be a useful adjunct to primary surgical treatment. In one case report, preoperative external beam irradiation and angiographic embolisation was described in the name reducing the chance of local recurrence<sup>2</sup>. The neoplastic cells of AA exhibit fibroblastic and myofibroblastic features and appear to be hormonally influenced. In spite of this, the role of hormonal therapy in the management of tumor has yet to determine. In conclusion, AA is a rare, benign neoplasm that can be mistaken both

clinically and on microscopy for several other conditions. The final diagnosis is usually provided by the pathologist. It is important to diagnose this condition because the tumor is locally infiltrative and requires wide excision and follow up.

## REFERENCES

1. Steeper TA, Rosai J. Aggressive angiomyxoma of the female pelvis and perineum. Report of nine cases of a distinctive type of gynecologic soft-tissue neoplasm. *Am J Surg Pathol.* 1983;7:463-75.
2. Fetsch JF, Laskin WB, Lefkowitz M, Kindblom LG, Meis-Kindblom JM. Aggressive angiomyxoma: a clinicopathologic study of 29 female patients. *Cancer.* 1996;78:79-90.
3. Rotmensch EJ, Kasznica J, Hamid MA. Immunohistochemical analysis of hormone receptors and proliferating cell nuclear antigen in aggressive angiomyxoma of the vulva. *Int J Gynaecol Obstet.* 1993;41:171-9.
4. Kazmierczak B, Wanschura S, Meyer-Bolte K, Caselitz J, Meister P, Bartnitzke S, Van de Ven W, Bullerdiek J. Cytogenetic and molecular analysis of an aggressive angiomyxoma. *Am J Pathol.* 1995;147:580-5.
5. Htwe M, Deppisch LM, Saint-Julien JS. Hormone-dependent, aggressive angiomyxoma of the vulva. *Obstet Gynecol.* 1995;86:697-9.

## Yazışma Adresi / Address for Correspondence:

Dr. Sevgi Bakaris,  
Kahramanmaraş Sütçüimam University Faculty of Medicine  
Department of Pathology  
46000 KAHRAMANMARAS  
E-mail: sevgi.bakaris@gmail.com

Geliş tarihi/Received on : 20.08.2014

Kabul tarihi/Accepted on: 23.09.2014