



### Short-Term Response to Infliximab in Rheumatoid Pattern Polyarthropathy Complicating Ulcerative Colitis

Ülseratif Koliti Komplike Eden Romatoid Paternli Poliartropatide Kısa Dönem Infliximab Yanıtı

İlke Coşkun Benliday<sup>1</sup>, Erkan Kozanoğlu<sup>1</sup>, Emine Aygül Ortaç<sup>1</sup>

<sup>1</sup>Cukurova University Faculty of Medicine, Department of Physical Medicine and Rehabilitation, ADANA-

*Cukurova Medical Journal 2015;40(4):818-821.*

#### ABSTRACT

Ulcerative colitis (UC) is a progressive inflammatory disease (IBD) of the bowel which can be accompanied by extra-intestinal findings such as peripheral and axial arthropathies. Patients with UC sometimes display rheumatoid pattern polyarthropathy which is challenging to differ from rheumatoid arthritis. We describe a case with rheumatoid pattern polyarthropathy complicating UC and her favourable response to infliximab therapy. A 25-year-old female with a diagnosis of UC was admitted due to swelling and pain in multiple joints. Laboratory tests revealed elevated acute phase reactants. Since the patient was refractory to the combination therapy comprising methotrexate, sulphasalazine and steroid, she was started on an infliximab regimen. She experienced an improvement both in terms of pain scores and biochemical findings. The patient was asymptomatic with reduced acute phase reactants following a 6-month-course of anti-tumor necrosis factor (anti-TNF) therapy. Infliximab serves as an effective treatment option for the management of rheumatoid pattern peripheral polyarthritis associated with UC.

**Key words:** anti-TNF, arthritis, infliximab, polyarthropathy, ulcerative colitis

#### ÖZET

Ülseratif kolit, periferik ve aksiyel artropatiler gibi ekstraintestinal bulguların eşlik ettiği progresif bir inflamatuvar barsak hastalığıdır. Ülseratif kolitli hastalarda bazen romatoid artritren ayırt edilmesi zor olan romatoid paternli poliartropati görülebilmektedir. Bu yazıda, ülseratif koliti komplike eden romatoid paternli bir poliartropati vakası ve infliximab tedavisine verdiği olumlu yanıt sunulmaktadır. Ülseratif kolit tanısı almış 25 yaşında bir kadın hasta çeşitli eklemlerinde şişlik ve ağrı yakınmasıyla başvurdu. Laboratuvar testlerinde akut faz reaktanları yüksekti. Metotreksat, sulfasalazin ve steroid kombinasyonuna yanıtız olması nedeniyle hastaya infliximab tedavisi başlandı. Ağrı skorları ve biyokimyasal belirteçlerde düzelleme gözlemlendi. Altı aylık anti-tümör nekrozis faktör (anti-TNF) tedavisi sonunda akut faz reaktanları düştü ve hasta asemptomattı. Infliximab, ülseratif kolitle ilişkili romatoid paternli periferik poliartropatide kullanılabilcek etkin bir tedavi seçeneğidir.

**Anahtar kelimeler:** anti-TNF, artrit, infliximab, poliartropati, ülseratif kolit

#### INTRODUCTION

Ulcerative colitis (UC) is a progressive inflammatory bowel disease (IBD) characterized by the recurrent inflammation of the colon. Other organs such as joints, skin, eyes, lung and kidney

may be involved in UC<sup>1</sup>. The most common extra-intestinal manifestations of UC are the musculoskeletal disorders in a wide spectrum of symptoms including axial and peripheral arthropathies<sup>2</sup>. Enteropathic peripheral arthropathy

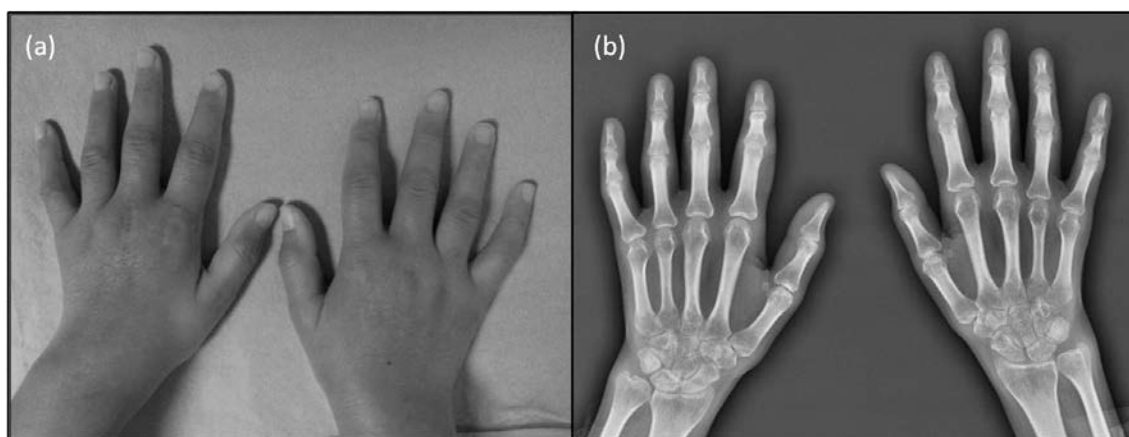
in IBD was subdivided into two distinct groups by Orchard et al.<sup>3</sup> Type 1 refers to a pauciarticular arthropathy with the arthritis of less than five joints. Type 2 peripheral arthropathy is the polyarticular form with the evidence of arthritis in five or more joints. Extraintestinal presentations including arthritis share a common pathogenic tumour necrosis factor (TNF) alpha dependent mechanism common with UC<sup>1</sup>. Significant increase of IL-1 and TNF levels in plasma is observed in patients with joint manifestations<sup>4</sup>. Therefore, UC related arthritis can respond to anti-TNF treatment<sup>1</sup>.

Herein, short-term response to infliximab (Remicade<sup>®</sup>; Merck & Co, New Jersey, United States) therapy in a patient with rheumatoid pattern arthropathy complicating ulcerative colitis is presented.

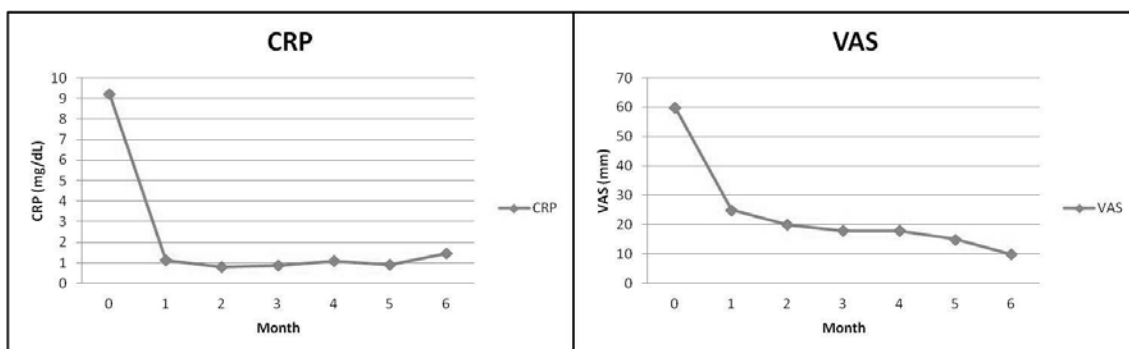
### CASE REPORT

A 25-year-old female with a diagnosis of UC was admitted with pain and swelling in multiple joints. Symptoms of the inflammatory bowel disease started during her pregnancy. Following the delivery, her complaints aggravated and a bowel biopsy led to a clear diagnosis of UC. Oral mesalamine therapy was started at a dose of 3 g/day. Later on, the patient developed joint pain and swelling in her hands and knees. With these complaints, she was admitted to a city hospital where she was started on methotrexate,

sulphasalazine and prednisolone. Since she was refractory to the medications over the course of months she was admitted to our outpatient clinic. Physical examination revealed provoked pain during passive movements of the peripheral joints. The patient had arthritis of the wrists, second and third metacarpophalangeal joints, second, third and fourth interphalangeal joints on both sides, in the right shoulder and right knee (Fig. 1). Laboratory tests at that time revealed erythrocyte sedimentation rate of 120 mm/hour and C-reactive protein of 9.23mg/dL (0-0.8 mg/dL). Despite a negative test result for rheumatoid factor (RF), anti-cyclic citrullinated peptide (Anti-CCP) was at the lower limit of range, with a titer of 20.09 U/ml (0-20 U/ml). Antinuclear antibodies and anti-deoxyribonucleic acid identification were both negative. Radiographs of the hands showed remarkable periarticular osteoporosis with no definite erosions (Fig. 1). Infliximab therapy was initiated along with methotrexate. At the first-month follow-up, the biochemical and clinical findings improved, visual analogue scale (VAS) score for joint pain changed to 25 from 60 and only one joint of the patient was still swollen and painful. Six months after treatment, the patient had neither signs of arthritis nor morning stiffness. She had minimal arthralgia in some phalangeal joints of her hands which she scored as 10/100 in VAS (Fig. 2).



**Figure 1.** (a) Clinical presentation of the patient (b) Radiography of the patient.



**Figure 2.** Improvements in C-reactive protein (CRP) and Visual Analogue Scale (VAS) for joint pain.

## DISCUSSION

Polyarthritis during the course of UC can be explained in at least two ways: UC related peripheral polyarthropathy and concurrent rheumatoid arthritis (RA). Unfortunately, it is often challenging to rule out RA from UC related polyarthropathy, especially in the absence of the antibodies of RA<sup>5</sup>. Peripheral arthropathy in IBD is generally asymmetric, migratory, non-deforming and associated with other extraintestinal findings<sup>6</sup>. Type 2 arthropathy in UC is associated with human leukocyte antigen (HLA)-B44. Class 1 antigen HLA-B44 is possessed by 62% of the patients with type 2 arthritis<sup>7</sup>. Nevertheless, HLA-B44 is negative in this present case.

Rheumatoid arthritis which is another progressive inflammatory disease may occur during the course of UC. This concurrence is so rare in the literature and the underlying mechanism remains uncertain<sup>8</sup>. Both of these diseases are immune-mediated inflammatory diseases sharing common pathogenic tumor necrosis factor alpha-dependent mechanism of damage which respond to the same biological treatment regimens<sup>9</sup>. Modification in Th1/Th2 balance can be esteemed as a pathogenetic mechanism through which UC and RA may interact<sup>5</sup>. The present case experienced polyarthritis right after delivery. This exacerbation can be explained by the loss of pregnancy associated shift from Th1 to Th2<sup>5</sup>.

Regarding this current case, non-erosive arthritic pattern causes a similarity to UC associated peripheral polyarticular arthropathy. On the other hand, HLA haplotype was not concordant with IBD related arthropathy. The case has similarities and differences with RA, as well. While the symmetrical pattern of the arthritis brings us a step closer to RA, absence of antibodies and erosions differ it from RA. When the absence of erosions is attributed to the initiation of methotrexate therapy at the very beginning of arthritis, it is more reasonable to consider the patient as having seronegative RA during the course of UC.

Arthritis in UC should be managed meticulously when first recognized. Regardless with the presence of arthropathies, when conventional drugs for IBD fail to control the disease activity, biologic agents can be used. Amongst these biologic agents, infliximab is the most widely used in the treatment of IBD<sup>9</sup>. Besides, anti-TNF therapy serves as a promising option for the treatment of arthritis in IBD. The current case was treated with infliximab. Clinical and biochemical effects of this drug appeared very early in the treatment course. The effectiveness of infliximab can be attributed to the down regulation of Th1 cytokines<sup>10</sup>.

In conclusion, early recognition of the arthropathies in the course of UC is of paramount importance in order to prevent severe consequences. Infliximab can be a reasonable

treatment option for patients suffering from arthropathies complicating UC.

#### Conflict of interest

The authors declare no conflicts of interest.

#### REFERENCES

1. Andrisani G, Guidi L, Papa A, Armuzzi A. Anti-TNF alpha therapy in the management of extraintestinal manifestation of inflammatory bowel disease. *Eur Rev Med Pharmacol Sci.* 2012;16:890-901.
2. D'Inca R, Podswiadek M, Ferronato A, Punzi L, Salvagnini M, Sturniolo GC. Articular manifestations in inflammatory bowel disease patients: a prospective study. *Dig Liver Dis* 2009;41:11565-9.
3. Orchard TR, Orchard TR, Wordsworth BP, Jewell DP. Peripheral arthropathies in inflammatory bowel disease: their articular distribution and natural history. *Gut.* 1998;42:387-91.
4. Dorofeyev AE, Vasilenko IV, Rassokhina OA. Joint extraintestinal manifestations in ulcerative colitis. *Dig Dis* 2009;27: 502-10.
5. Boyer F, Fontanges E, Miossec P. Rheumatoid arthritis associated with ulcerative colitis: a case with severe flare of both diseases after delivery. *Ann Rheum Dis.* 2001;60:901.
6. Yuksel I, Ataseven H, Basar O, Koklu S, Ertugrul I, Ulker A, et al. Peripheral arthritis in the course of inflammatory bowel diseases. *Dig Dis Sci.* 2011;56:183-7.
7. Orchard TR, Thiyagaraja S, Welsh KI, Wordsworth BP, Hill Gaston JS, Jewell DP. Clinical phenotype is related to HLA genotype in the peripheral arthropathies of inflammatory bowel disease. *Gastroenterology.* 2000;118:274-8.
8. Cruz VA, Yamaguchi L, Ribeiro CN, Magalhães Vde O, Rego J, Silva NA. Ulcerative colitis and rheumatoid arthritis: a rare association--case report. *Rev Bras Reumatol.* 2012;52:648-50.
9. Lesuis N, Befrits R, Nyberg F, van Vollenhoven RF. Gender and the treatment of immune-mediated chronic inflammatory diseases: rheumatoid arthritis, inflammatory bowel disease and psoriasis: an observational study. *BMC Med.* 2012;10:82.
10. Kollias G, Douni E, Kassiotis G, Kontoyiannis D. On the role of tumor necrosis factor and receptors in models of multiorgan failure, rheumatoid arthritis, multiple sclerosis and inflammatory bowel disease. *Immunol Rev.* 1999;169:175-94.

#### Yazışma Adresi / Address for Correspondence:

Dr. Ilke Coskun Benlidayı  
Cukurova University Faculty of Medicine  
Department of Physical Medicine and Rehabilitation  
ADANA  
E-mail: icbenlidayi@hotmail.com

Geliş tarihi/Received on : 27.08.2014

Kabul tarihi/Accepted on: 01.10.2014