

## A case of Krukenberg tumor, eight years after treatment of gastric cancer

### Mide kanseri tedavisinden 8 yıl sonra gelişen Krukenberg tümörü olgusu

Servet KARAGÜL, Fatih SÜMER, Asım ONUR, Ali TARDU, Adile Ferda DAĞLI, Cuneyt KAYAALP

#### ABSTRACT

Krukenberg tumor is a rare metastatic tumor of the ovary. The primary tumors are usually gastrointestinal cancers. Most of the Krukenberg tumors reported in the literature occurred within the first 2 years after treatment of the primary disease. Herein, we present a case of Krukenberg tumor in a 37-year-old woman who previously underwent surgery and chemotherapy for stomach cancer. This patient is noteworthy because it is one of the few documented cases of ovarian metastasis appearing after a disease-free period of 8 years following treatment of the primary tumor. Krukenberg tumors are associated with poor prognosis; therefore, regular gynecological examination in female patients with history of gastric cancer is very important for the early diagnosis and treatment of this disease.

**Keywords:** Krukenberg tumor, Gastric cancer, Ovarian metastasis

#### ÖZ

Krukenberg tümörü overleri tutan, nadir görülen metastatik bir tümördür. Sıklıkla primer odak gastrointestinal kanserlerdir. Literatürdeki Krukenberg tümörlerinin çoğunluğu primer hastalığın tedavisinden sonra ilk 2 yıl içinde meydana gelmektedir. Biz burada mide kanseri nedeniyle cerrahi tedavi ve kemoterapi uygulanmış 37 yaşında bir kadın hastada karşılaştığımız Krukenberg olgusunu sunduk. Olgumuzun dikkat çeken tarafı primer hastalığın tedavisinden sonra hastalıksız geçen 8 yılın ardından over metastazı görülmesi olup, literatürdeki nadir olgulardan biridir. Mide kanserli kadın hastalarda düzenli jinekolojik muayene, prognozu oldukça kötü olan bu hastalığın erken tanı ve tedavisi açısından önemlidir.

**Anahtar kelimeler:** Krukenberg tümörü, Mide kanseri, Over metastazı

#### Introduction

Krukenberg tumor is a rare metastatic tumor involving the ovaries. Gastric cancer is usually the primary site [1]. Friedrich Ernst Krukenberg, who first described the tumor in 1896, originally named it 'ovarian mucocellular fibrosarcoma' [2]. They account for 1-2% of all ovarian tumors [3,4]. Reports of Krukenberg tumors developing very late after gastric cancer treatment are very rare in the literature [5,6]. Though uncommon, the prognosis of Krukenberg tumors is poor. Therefore, gynecologic follow-up of gastric cancer patients is important. In this report, we describe a patient previously operated for gastric cancer who presented with Krukenberg tumor 8 years later, after a long disease-free period.

#### Case Report

A 37-year-old female patient underwent gastric surgery and chemotherapy for stomach cancer at another center 8

Servet Karagül (✉), Fatih Sümer, Asım Onur, Ali Tardu, Cuneyt Kayaalp  
Department of General Surgery, School of Medicine, Inonu University,  
Malatya, Turkey  
e-mail: e-mail.servetkaragul@hotmail.com

Adile Ferda Dağlı  
Department of Pathology, School of Medicine, Fırat University,  
Elazığ, Turkey

Submitted / Gönderilme: 13.02.2018 Accepted/Kabul: 21.04.2018

years earlier and had uneventful follow-up until the last 3 months. However, 3 months ago she consulted a primary care physician due to abdominal pain. A mass measuring about 5 cm in diameter was detected in the right ovary by ultrasound and she was referred to our hospital. The patient had been unable to obtain her surgical notes or pathology report from 8 years earlier; she only had a note from the referring surgeon regarding the subtotal gastrectomy + D2 lymph node dissection performed due to adenocarcinoma.

Computed tomography (CT) done in our clinic revealed a complex cystic mass of 135x66 mm in size in the right ovary (Figure 1). The patient's past subtotal gastrectomy was evident but there were no signs of pathology in upper gastrointestinal endoscopic examination. Colonoscopy was normal. Given the patient's history of stomach cancer, we suspected an isolated ovarian metastasis and scheduled the patient for surgery. Upon exploration, a mass approximately 14 cm in diameter was found in the right ovary. Frozen section was interpreted as metastatic adenocarcinoma. Total abdominal hysterectomy and bilateral salpingo-oophorectomy were performed. The remaining abdominal organs appeared healthy. There were no complications and the patient was discharged on postoperative day 4. The pathology report indicated signet ring cell adenocarcinoma metastasis (Figures 2,3). Due to her socioeconomic status, the patient stated that she would go to her local hospital for adjuvant treatment, after which she did not contact our center again.

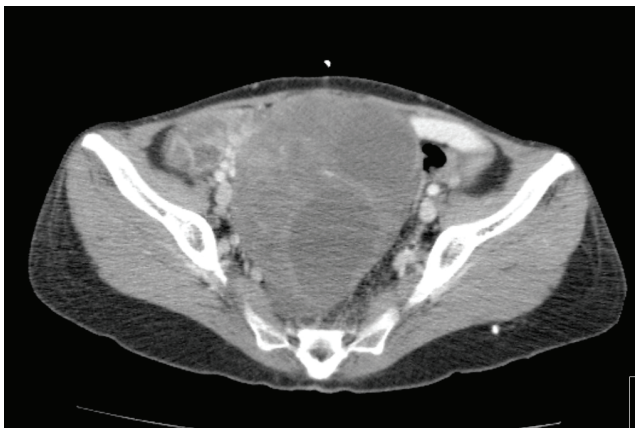


Figure 1. Computed tomography image of Krukenberg tumor

At postoperative 16 months, she was again referred to our emergency department due to deterioration of her general condition. She was admitted to the intensive care unit where a tumoral lesion in the gingiva was observed during physical examination. CT revealed a lesion that appeared metastatic,

about 4 cm in diameter, in the bony pelvis. The patient died due to cardiopulmonary insufficiency on the first day after admission.

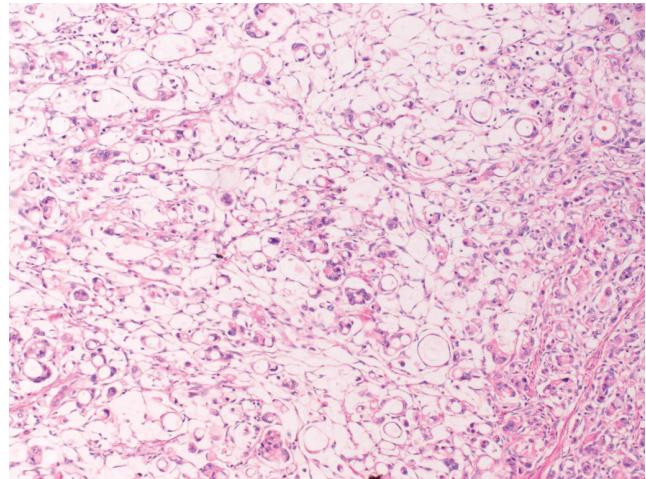


Figure 2. Tumor infiltration comprising signet ring cells with cytoplasmic mucin displacing the nucleus to the periphery. H&E x100

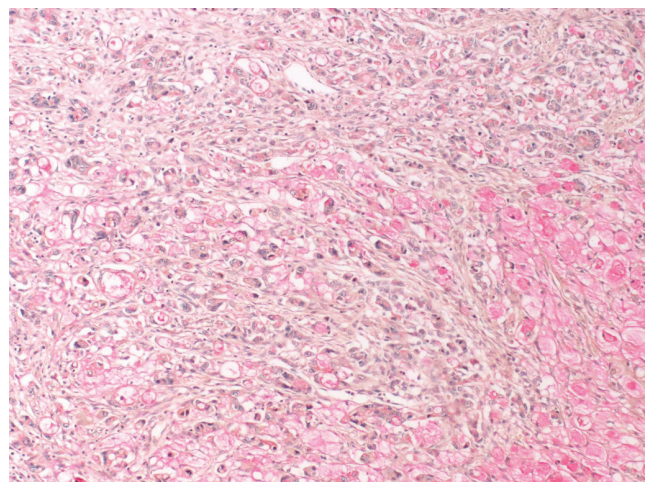


Figure 3. Cytoplasm of the tumor cells was positive in histochemical mucicarmine staining. Mucin x100

## Discussion

Gastric cancer is one of the most common cancers worldwide and can lead to both synchronous and metachronous ovarian metastases. Approximately 90% of metastatic ovarian tumors originate from the gastrointestinal tract [7]. The mechanism of metastasis is unknown. Hematogenous system, lymphatic system and transcoelomic pathway can spread the tumor cells [8]. The lymphatic route is thought to be the most likely way of the metastasis. Gastric cancers metastasize to

the ovaries more frequently than colon cancers, though the reason for this is not fully understood. Ovarian metastases from gastric cancer have worse prognosis than metastases from other organs [9,10]. Consistent with the literature, our patient also had poor prognosis and survived 16 months after metastasis to the ovary.

A very broad time range has been reported for gastrointestinal system metastasis to the ovaries. Although, the majority of ovarian metastases occur within the first two years, there are also a few cases of ovarian metastasis appearing years later [5,6]. For this reason, patients must be followed indefinitely and have regular gynecological examinations. Unfortunately, there are no characteristic symptoms of these tumors, and these patients can be asymptomatic when diagnosed with Krukenberg tumor. That is why any pelvic pain, dyspareunia and menstrual irregularity in the patient with a history of gastric cancer must be examined for ovarian metastasis [9]. In the present case, we were unable to acquire detailed information about the pathology results, follow-up intervals, and tests performed 8 years ago due to the socioeconomic situation of our patient, our inability to maintain contact with her, and her residence in a city far from our hospital. We only observed that the patient was diagnosed with Krukenberg tumor 8 years after primary treatment.

Although, there is still much we do not understand about ovarian metastases, it is known that Krukenberg tumors from gastric cancer are more common in premenopausal women. Our patient was also a young woman and is included in this group. The higher blood flow in the ovaries prior to menopause has been suggested as an explanation for this pattern [9]. Primary Krukenberg tumors have also been reported in the literature. However, we have doubts regarding these cases. Nakamura et al., reported a case of ovarian signet ring cell carcinoma in a patient in whom no primary origin could be detected endoscopically or radiologically [11]. The patient developed bone metastasis 6 months later and died another 6 months after that despite treatment. In the autopsy, however, 4 small (<1 mm) lesions were detected in the stomach and diagnosed as signet ring carcinoma. Krukenberg tumors after intramucosal stomach cancers have also been documented [12]. Therefore, gastric cancers at any stage are important in terms of ovarian metastasis.

The optimal treatment for Krukenberg tumor from gastric cancer has not yet been established. Despite conflicting views in the literature, metastasectomy and chemotherapy appears

to be the most accepted approach. Our patient also underwent surgical resection and chemotherapy. Radiotherapy and cytoreductive surgery were not considered for the patient. There are also no recommendations in the literature about radiotherapy. There is insufficient information regarding the place of cytoreductive surgery in Krukenberg tumors of gastric origin. It is believed to be more beneficial for colonic metastases [9,13].

As the number of reported cases of Krukenberg tumor is limited, there is a paucity of data regarding the various primary sources. There is no general treatment regimen, and it is also necessary to consider the primary site when making treatment decisions. It should be kept in mind that there is no time limit for distant metastasis risk after treatment for gastric cancer, and gynecological follow-up should be performed accordingly in these patients.

## References

1. Kubecek O, Laco J, Spacek J, et al. The pathogenesis, diagnosis, and management of metastatic tumors to the ovary: a comprehensive review. *Clin Exp Metastasis* 2017; 34 : 295-307. doi: 10.1007/s10585-017-9856-8
2. Krukenberg F E. Fibrosarcoma ovarii mucocellulare (carcinomatodes). *Arch Gynäkol* 1896; 50: 287-321. doi: 10.1007/BF01700650
3. Schlagenhauser F. Ueber das metastatische ovarial carcinom nach Krebs des Magens, Darmes, und anderer Bauchorgane. *Monatschr Geburtst Gynakol* 1902;1:485-528ç doi: 10.1159/000283419
4. Young RH. From Krukenberg to today: part I. Historical perspective, general principles, mucinous tumors including the Krukenberg tumor. *Adv Anat Pathol* 2006; 13: 205-7. doi: 10.1097/01.pap.0000213038.85704.e4
5. Malgorzata J, Janusz E. Krukenberg tumor—8 years after surgical treatment of gastric carcinoma. *Ginekol Pol* 2008; 79: 564-6.
6. Szarmach A, Swieton D, Szydłowska-Szarmach E, et al. Krukenberg tumor—a multidisciplinary approach—a case report. *Ginekol Pol* 2014; 85: 545-8.
7. Li W, Wang H, Wang J, Fangfang LV, Zhu X, Wang Z. Ovarian metastases resection from extragenital primary sites: outcome and prognostic factor analysis of 147 patients. *BMC Cancer* 2012; 12: 278. doi:10.1186/1471-2407-12-278
8. Aziz M, Kasi A. *Cancer, Krukenberg Tumor*. StatPearls [Internet]. Treasure Island (FL): StatPearls Publishing; 2018. [Access on 14.03.2018]
9. Matsushita H, Watanabe K, Wakatsuki A. Metastatic gastric cancer to the female genital tract. *Mol Clin Oncol* 2016; 5: 495-9. doi: 10.3892/mco.2016.1035
10. Wu F, Zhao X, Mi B, et al. Clinical characteristics and prognostic analysis of Krukenberg tumor. *Mol Clin Oncol* 2015; 3: 1323-8. doi: 10.3892/mco.2015.634

11. Nakamura Y, Hiramatsu A, Koyama T, Oyama Y, Tanaka A, Honma K. A krukenberg tumor from an occult intramucosal gastric carcinoma identified during an autopsy. *Case Rep Oncol Med* 2014; 2014: 797429. doi: 10.1155/2014/797429
12. Kakushima N, Kamoshida T, Hirai S, et al. Early gastric cancer with Krukenberg tumor and review of cases of intramucosal gastric cancers with Krukenberg tumor. *J Gastroenterol* 2003; 38: 1176-80. doi:10.1007/s00535-003-1227-3
13. Yu P, Huang L, Cheng G, et al. Treatment strategy and prognostic factors for Krukenberg tumors of gastric origin: report of a 10-year single-center experience from China. *Oncotarget* 2017; 8: 82558-70. doi: 10.18632/oncotarget.19759