

Case Report

## Pediatric paraspinal penetrating sewing needle

İsmail Demir<sup>a,\*</sup>, Nejmi Kıymaz<sup>b</sup>, Burhan Oral GÜdü<sup>c</sup>, Abdülbaki Kozan<sup>d</sup>, Abdulsemat Gökalp<sup>e</sup>

<sup>a</sup>Department of Neurosurgery, Pamukkale University, Medical School, Denizli, Turkey

<sup>b</sup>Department of Neurosurgery, Akdeniz University, Medical School, Antalya, Turkey

<sup>c</sup>Department of Neurosurgery, Kanuni Sultan Süleyman Training and Research Hospital, İstanbul, Turkey

<sup>d</sup>Department of Neurosurgery, Yuzuncu Yil University, Medical School, Van, Turkey

<sup>e</sup>Department of Neurosurgery, Tatvan State Hospital, Bitlis, Turkey

**Abstract.** Pediatric spinal injuries are very rare conditions and account for 1%-10% of all spinal injuries. Domestic accidents, such as falling and bumping, are frequent events during childhood. In this study, a 1-year-old boy who was under treatment due to a penetrating trauma at the posterior thoracolumbar intersection is presented. The patient was referred to our clinic after a needle became impaled into his back due to an accident that occurred at home. The patient's neurologic assessment was normal. A radiologic study of the patient showed the presence of a metallic foreign object, extending into the paravertebral muscle on the left side of the T12-L1 intersection. The needle was removed promptly after an emergent surgical procedure. No any complications were present during the follow-up visit after 1 month. Emergent surgical intervention is necessary in paraspinal and spinal penetrating traumas.

Key words: Paraspinal trauma, domestic accident, sewing needle

### 1. Introduction

Pediatric spinal injuries are very rare conditions and account for 1%-10% of all spinal injuries. Domestic accidents, such as falling and bumping, are frequent events during childhood. However, pediatric injuries and wounds due to spinal cuts/penetrating devices are rare. The case of a 1-year-old boy is presented in whom a sewing needle pierced the left side of the thoracolumbar intersection and broke off during a domestic household accident. The relevant literature is reviewed.

### 2. Case report

A 1-year-old boy was referred to our emergency outpatient clinic for evaluation and treatment of an impaled sewing needle in his back. The patient was examined and it was determined that the foreign object had entered the back at the left side of the thoracolumbar

intersection. The patient was agitated and withdrew his legs towards his abdomen. The flat x-ray radiograph showed a metallic foreign object that extended into the paravertebral muscles on the left side of the T12-L1 intersection (Figure 1a,1b). The patient underwent surgery immediately and after an incision was performed through an endoscope under general anesthesia, a 4 cm sewing needle was removed from the site of entrance in the left vertebral muscles (Figure 2). Prophylactic antibiotic therapy was started. The patient was discharged 3 days after the operation without any signs of a neurologic deficit. No pathologic findings were noted at the follow-up visit 3 months later.

### 3. Discussion

Spinal injuries in childhood are rare events, comprising 1%-10% of all spinal injuries (1-4). The management of penetrating spinal trauma in children differs from the therapeutic approach applied to adults. A child may not be able to express pain and sensitivity, and therefore a complete systemic examination must be conducted and local dermal lesions and injuries detected. However, it may be difficult to determine the site of entrance of a foreign object. Osenbach and Menezes (5) studied childhood spinal trauma in 179 children and found that cervical trauma (63%) was the most frequently encountered condition, while thoracic (13%),

\*Corresponding Author: Dr. İsmail Demir

Department of Neurosurgery, Pamukkale University, Medical School, 20070 Denizli- TURKEY

Phone: +90-0-258.4440728/5380, +90-0-.532 332 8640

fax: 90.258.2131034

e-mail address: i.demir2006@hotmail.com

Received: 19.08.2013

Accepted: 05.02.2015

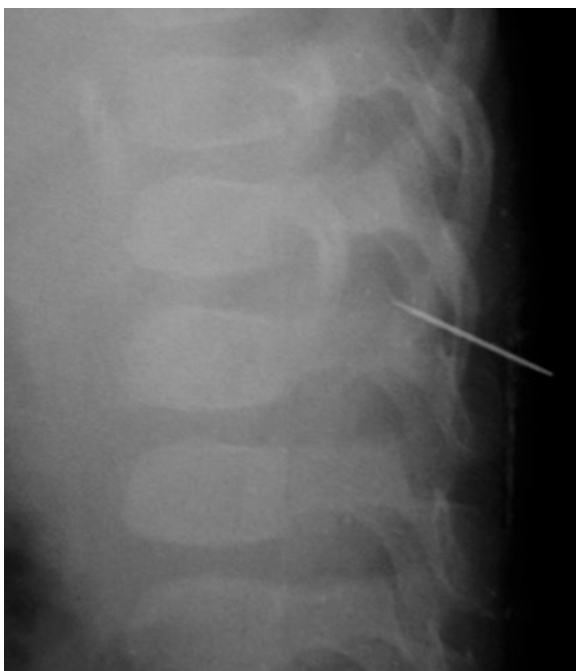

Fig. 1a. Lateral plain radiograph of the thoracolumbar spine showed a metallic foreign object.

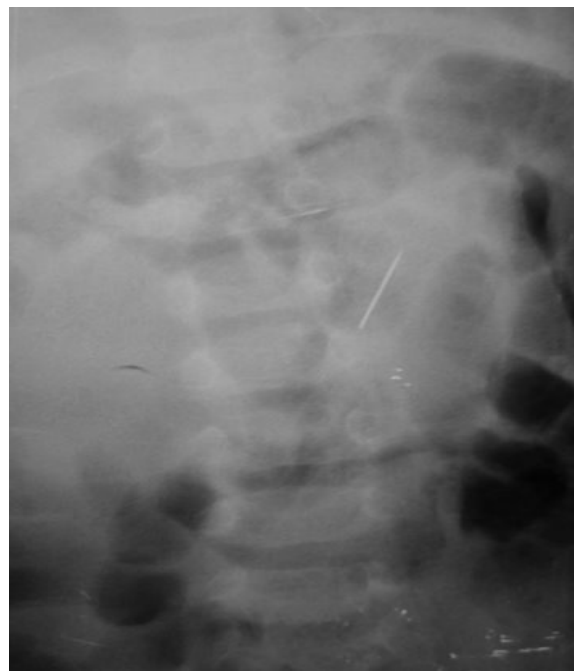


Fig. 1b. Anteroposterior plain radiograph of the thoracolumbar spine showed a metallic foreign object.

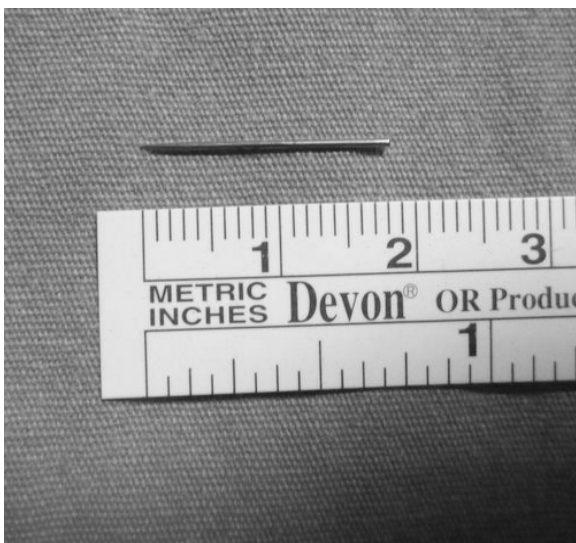

Fig. 2. Photograph of the sewing needle.

thoracolumbar (11%), and trauma to the lumbar region (14%) were rare. The etiology of such events include accidents due to motor vehicles (53%), falls (17%), neonatal trauma (6%), and injuries because of penetrating firearms (4%). Trauma due to penetrating foreign objects to the spine is rare. The instruments of such injuries include knives, wooden materials, glass, pencils, firearms, and as described herein, a sewing needle (4,6). Sometimes foreign objects are occult and may manifest by a complication (7,8).

Injuries may effect the medulla spinalis, spinal nerves, vertebrae, and one or more veins (3,4,9). In the case here in, the foreign object failed to reach the spinal cord and remained inert in the paraspinal zone, and therefore demonstrated no neurologic symptoms. A flat radiograph and tomography are appropriate methods to identify foreign objects, while magnetic resonance imaging is preferred to demonstrate the location of non-metallic foreign objects (10,11,12).

Foreign objects that penetrate into the spinal region may cause an infection. The origin of infection is commonly the normal dermal flora. *Staphylococcus aureus* and *Enterobacteria* species are pathogenic microorganisms that can be isolated. Prophylactic antibiotic therapy must be started against these bacteria (5,13). In our case, ceftriaxone and ampicillin-sulbactam were used as prophylactic antibiotics and no infections developed. Penetrating foreign objects in the spinal region may cause neurologic deficits, hypoesthesia, anesthesia, infections, abscesses, and formation of a CSF fistula. Appropriate therapy must be utilized against these complications (8,13). No complications were determined during the 1-month follow-up period in our patient.

Trauma due to penetrating foreign objects in the pediatric spinal region are important because of the location, and therefore early surgical intervention should be considered. Foreign

objects can be removed by endoscopy or a stereotactic route (14). Accidents due to motor vehicles and falling from high places are accidents that are frequently encountered in early childhood.

The upper cervical region is the most affected zone. Penetrating injuries are more frequent at the thoracic and/or lumbar regions. It is necessary to provide emergent surgical intervention in pediatric paraspinal penetrating injuries and overcome the management of complications.

The nature of penetrating foreign objects, the penetrated tissue, the site, and the damage at the penetration site dictate the extent and nature of the operation. The detection of a metallic foreign object is possible with a flat x-ray radiograph. The detection of foreign objects, such as wood and glass with a lower opacity ratio, may be difficult during surgical intervention.

The present case is the first reported pediatric case involving a penetrating paraspinal needle. Pediatric spinal injuries may be dependent on several factors, such as age, and may affect the vertebrae, medulla spinalis, and/or paravertebral regions of the body. Early surgical intervention must be considered in the management of penetrating injuries.

## References

1. Dias MS. Traumatic brain and spinal cord injury. *Pediatr Clin N Am* 2004; 51:271-303.
2. Grabb PA, Hadley MN. Spinal column trauma in children, in *Principles and Practice of Pediatric Neurosurgery*, Edited by L. Albright, I. Pollack and D. Andelson. Thieme Medical Publishers, Inc., New-York 1999; 935-953.
3. ReKate HL, Theodore N, Sonntag VKH, Dickman CA. Pediatric spine and spinal cord trauma. State of the art for the third millennium. *Child's Nerv Syst* 1999; 15:743-750.
4. Cirak B, Ziegfeld S, Knight VM, Chang D, Avellino AM, Paidas CN. Spinal Injuries in Children. *J Pediatr Surg* 2004; 39:607-612.
5. Osenbach RK, Menezes AH. Pediatric spinal cord and vertebral column injury. *Neurosurgery* 1992; 30:385-390.
6. Haffner DL, Hoffer MM, Wiedbusch R. Etiology of children's spinal injuries at Rancho Los Amigos. *Spine* 1993; 18:679-684.
7. Silvestro C, Cocito L, Pisani R. Delayed Effects of a Migrated Foreign Body (Sewing Needle) in the Cervical Spine. *Spine* 2001; 26:578-579.
8. Yanay O, Vaughan DJ, Diab M, Brownstein D, Brogan T. Retained wooden foreign body in a child's thigh complicated by severe necrotizing fasciitis: a case report and discussion of imaging modalities for early diagnosis. *Pediatr Emerg Care* 2001; 17:354-355.
9. Benzel EC, Hadden TA, Coleman JE. Civilian gunshot wounds to spinal cord and cauda equina. *Neurosurgery* 1987; 20: 281-285.
10. Opel DJ, Lundin DA, Stevenson KL, Klein EJ. Glass foreign body in the spinal canal of a child, case report and review of the literature. *Pediatr Emerg Care* 2004; 20:468-472.
11. Roche C, Carty H. Spinal trauma in children. *Pediatr Radiol* 2000; 31:677-700.
12. Hadley MN. Spinal cord injury without radiographic abnormality. *Neurosurgery* 2002; 50:100-104.
13. Pal D, Timothy J, Marks P. Penetrating spinal injury with wooden fragments causing cauda equina syndrome: case report and literature review. *Eur Spine J* 2006; 15:574-577.
14. Çinçin TG. Yumuşak Doku İçindeki Radyopak Yabancı Cisimlerin Stereotaksik Yöntemle Çıkarılması. *Kartal Eğitim ve Araştırma Hastanesi Tıp Dergisi* 2005; 16:59-62.