

EFFECTS OF PAMIDRONATE ADMINISTRATION ON TOOTH ERUPTION AND MANDIBULAR GROWTH IN NEW BORN RATS

Yeni Doğan Sıçanlara Pamidronat Uygulamasının Diş sürmesi ve Mandibula Gelişimi Üzerine Etkileri

İbrahim TUNCER ¹, Çağrı DELİLBAŞI ², Ediz DENİZ ¹, Merva SOLUK-TEKKEŞİN ³, Vakur OLGAÇ ³, Kemal ŞENÇİFT ¹

Received: 23/03/2016

Accepted: 04/06/2016

ABSTRACT

Purpose: Bisphosphonates are commonly used drugs in pediatric patients in the treatment of osteoporotic diseases and various types of cancers. The purpose of this study was to evaluate the effects of pamidronate administration on mandibular growth and tooth eruption in new born rats.

Materials and Methods: Forty Sprague Dawley rats were included in the study and divided into four groups as; 14th day pamidronate group, 30th day pamidronate group, 14th day control group and 30th day control group. Pamidronate groups were daily injected with 1.25 µg/g pamidronate disodium subcutaneously whereas control groups were injected with sterile saline. Eruption levels of lower incisor and molar teeth were assessed macroscopically. Mandibular growth was assessed by measuring reference points in cone beam tomography. Histological and histomorphometric examinations were performed under light microscope to evaluate tooth morphology and number of osteoclasts.

Results: Retardation in mandibular growth, decrease in number of osteoclasts, delay in tooth eruption, degeneration in both tooth morphology and structure were observed in the pamidronate groups compared to control groups.

Conclusion: Pamidronate administration during growth and development stage may adversely affect tooth eruption and mandibular growth in new born rats.

Keywords: Bisphosphonate; mandibular growth; pamidronate; tooth eruption

ÖZ

Amaç: Bifosfonatlar çocuk hastalarda osteoporotik hastalıkların ve çeşitli kanserlerin tedavisinde yaygın olarak kullanılırlar. Bu çalışmanın amacı yeni doğan sıçanlarda pamidronat uygulanmasının mandibular gelişim ve diş sürmesi üzerine etkilerinin araştırılmasıdır.

Gereç ve Yöntem: Bu çalışmada kırk adet Sprague Dawley cinsi sıçan kullanılmıştır. Deney hayvanlarından 14. gün pamidronat grubu, 30. gün pamidronat grubu, 14. gün kontrol grubu ve 30. gün kontrol grubu olmak üzere dört grup oluşturuldu. Pamidronat grubuna günlük olarak 1.25 µg/g dozda subkutan pamidronat disodyum enjeksiyonu yapılırken, kontrol grubuna steril serum fizyolojik enjeksiyonu yapıldı. Kesici ve azı dişlerinin sürme dereceleri makroskopik olarak değerlendirildi. Mandibular gelişim konik ışınli bilgisayarlı tomografi kesitlerinden referans noktalarının ölçülmesiyle incelendi. Diş morfolojisi ve osteoklast sayısını araştırmak için histolojik ve histomorfometrik incelemeler ışık mikroskobu altında yapıldı.

Bulgular: Pamidronat gruplarında kontrol gruplarıyla karşılaştırıldıklarında, mandibula gelişiminde gerilik, osteoklast sayısında azalma, diş sürmesinde gecikme ya da sürememe, diş morfolojisi ve yapısında dejenerasyon gibi bulgular saptandı.

Sonuç: Büyüme ve gelişim döneminde pamidronat uygulanması yeni doğan sıçanlarda diş sürmesini ve mandibula gelişimini olumsuz yönde etkileyebilir.

Anahtar kelimeler: Bifosfonat; mandibula gelişimi; pamidronat; diş sürmesi

¹ Department of Oral and Maxillofacial Surgery Faculty of Dentistry Yeditepe University

² Department of Oral and Maxillofacial Surgery Faculty of Dentistry Istanbul Medipol University

³ Department of Tumor Pathology Institute of Oncology Istanbul University



Introduction

Bisphosphonates (BPs), are synthetic, nonhydrolyzable pyrophosphate analogues. They are capable of accumulating in bone tissue and thereby of inhibiting function of osteoclasts. Since BPs are metabolized very slowly, they can reside within the bone tissue for long periods of time (1). BPs are being successfully used to treat osteoporosis, metabolic bone diseases and bone metastasis in adults (1-4). BPs were first used for the treatment of osteogenesis imperfecta in children and the field of application extended including Paget's disease, resistant hyperkalemia as well as primary and secondary osteoporosis (5, 6). Since BPs accumulate in bones, the effects of their long term use on growth and development in children should be elucidated. Tooth eruption is a process that includes the movement of a tooth from the alveolar bone to inside the oral cavity. For this process, osteoclast activity thus bone resorption should take place (7). Administration of BPs during this period may affect tooth development and eruption. Pamidronate (3-amino-1-hydroxypropylidene-1, 1-bisphosphonates) is a type of BP being commonly used in pediatric osteoporotic disorders such as; osteogenesis imperfecta, fibrous dysplasia, and in some causes of secondary osteoporosis, like cerebral palsy and meningomyelocele. As in other BPs, pamidronate suppresses osteoclast functions. Pamidronate decreases bone pain in symptomatic patients, as well as the incidence of fractures. It improves ambulatory status and increases the growth rate. In addition, increases in bone mineral density and vertebral height have been reported (8-10). There are few published animal studies regarding effects of BPs on mandibular development and tooth eruption (1, 2, 11). The aim of the present study was to evaluate the effects of pamidronate administration, since this BP has not been previously studied considering mandibular growth and tooth eruption. Furthermore, we aimed to investigate the pamidronate effects using macroscopic, microscopic and radiological measures in new born rats in order to make a contribution on the effects of bisphosphonates during growth and development.

Materials and Methods

Experimental animals and study design

Forty new born male Sprague-Dawley rats (N=40) were obtained from Yeditepe University, laboratory animal research center (Istanbul, Turkey). The protocol

for the study was approved by the Yeditepe University Laboratory Animals Ethical Committee. Rats were housed in cages and they were provided with filtered air at a temperature of $22 \pm 1^\circ\text{C}$ and $50 \pm 5\%$ relative humidity. A 12 h light/dark cycle was maintained and the animals were fed with a standard diet of rat chow and water *ad libitum*. Animals were randomly divided into four groups: 14th day pamidronate group (n=10), 30th day pamidronate group (n=10), 14th day control group (n=10), and 30th day control group (n=10). Rats in the pamidronate groups were daily injected in the dorsal neck subcutaneously with 1.25 $\mu\text{g/g}$ pamidronate disodium (Aredia®, Novartis Pharmaceuticals Co., East Hanover, NJ, USA) as described previously (11). Rats in the control group were treated similar to the pamidronate groups using sterile saline and they were humanely killed by pentothal overdose at 14th and 30th days. Injections initiated the day after birth.

Macroscopic evaluation

The mandibles of the sacrificed animals were surgically dissected and removed. Thorough dissection of condylar and angular region was carried out carefully for accurate measurement in the cone beam tomography. In this study eruption was defined as the time the tooth pierces the gingiva. The eruption levels of the incisor and molar teeth were inspected and scored on the 14th and 30th days following injection by the same researcher who was blind to the groups formed. Eruption level was scored as 0: Fully impacted, 1/3: One third of the crown erupted, 1/2: Half of the crown erupted, 1: Fully erupted. Mandibles were then divided into right and left hemimandibles for radiological and microscopic evaluation.

Cone beam computed tomography (CBCT) analysis

Horizontal and vertical growth patterns of mandibles were analyzed with CBCT (Iluma CBCT scanner, IMTEC Imaging Co., Ardmore, OK, USA) adjusted with 120 kVp, 4 mA and 40 second pose for each sample. Calibration of the machine was performed by regular scanning of a cylinder with a diameter of 2.0000 inches. Allowed deviation was measured to determine the acceptability of calibration. Furthermore, noise level, autofocus and modulation transfer function parameters were evaluated for validity. Measurements were done using orthodontic reference points which were described previously (12). Four lines were drawn in order to determine the

length of the mandible: First line was drawn tangent to the menton (Me) and antegenion (Ag) points whereas the second line passed through the condylar peak point parallel to the first line. The distance between these two lines were determined as the vertical length (VL). Then, two lines perpendicular to the first two lines were drawn that passed from the anterior and posterior terminal points of the mandible. The distance between the intersection points in the horizontal plane was defined as horizontal length (HL) (Figure 1).

Left hemimandibles were fixed in 10% neutral formalin solution and processed for histological and histomorphometric evaluation at Istanbul University, Institute of Oncology, Department of Tumor Pathology. Bone samples were decalcified in 10% EDTA (pH 7.2) at 4 °C for 21 days. Decalcified hemimandibles including molar teeth were sliced from sagittal orientation.

The sections were embedded in paraffin using the standard histological protocol and 5 μ thick sections were prepared, they were stained with Hematoxylin-Eosin (HE) and were evaluated under a light microscope (Eclipse E600; Nikon Corp., Konan, Tokyo, Japan). The most representative 5 microscopic high-power fields were evaluated. Osteoclasts were counted in bone tissue around germs at the 14th day sacrifice groups, and expressed as a percentage of the total bone surface area (n/mm²).

The analysis was done with AnalySIS FIVE digital imaging software (Olympus Soft Imaging Solutions GmbH, Münster, Germany).

Statistical analysis

Number Cruncher Statistical System (NCSS) 2007 and Power Analysis and Sample Size Software (PASS) 2008, (both software from NCSS LLC, Kaysville, Utah, USA) were used for statistical analysis. Multiple comparisons were performed with Student's t-test and pair-wise comparisons were performed using paired sample t-test. p values less than 0.05 were considered significant for all tests.

Results

Tooth eruption levels

When the tooth eruption time in rats is considered, eruption of both mandibular incisors and molars were found to be delayed in pamidronate injected newborn rats when compared with controls. Furthermore, while second molar eruption was observed in the 30th day control group, no eruption was evident in the 30th day pamidronate group. Tooth eruption levels are shown in Table 1.

Mandibular growth

When 14th day groups are compared; horizontal length of the mandible in the pamidronate group was significantly shorter than that of the control group (p=0.02) but, there was no significant difference regarding vertical length of the mandible (p=0.20) (Table 2). When 30th day groups are compared; both horizontal and vertical lengths of the mandibles of the pamidronate group were significantly shorter than those in control group (p=0.001 and p=0.001, respectively) (Table 2).

Table 1. Level of mandibular tooth eruption in pamidronate and control groups.

Tooth eruption level	Incisors	1.Molar	2.Molar
<i>14th day pamidronate group (n=10)</i>	-	-	-
<i>14th day control group (n=10)</i>	1/3	-	-
<i>30th day pamidronate group (n=10)</i>	1/3	1/3	-
<i>30th day control group (n=10)</i>	+	+	+

+ : Fully erupted, 1/3 : 1/3 of the crown was erupted, - : Fully impacted

Table 2. Mandibular horizontal and vertical growth and number of osteoclasts in the pamidronate and control groups.

Mandibular Growth (mm)	Horizontal	Vertical
14 th day pamidronate group (n=10)	10.50±1.43	4.75±1.03
14 th day control group (n=10)	12.30±1.70	5.30±0.82
P value	0.020	0.205
30 th day pamidronate group (n=10)	10.00±0.47	4.50±0.71
30 th day control group (n=10)	15.00±1.05	7.30±0.67
P value	0.001	0.001
Osteoclast number (n)/tissue surface (mm ²)	n/mm ²	
14 th day pamidronate group (n=10)	6.06±1.47	
14 th day control group (n=10)	10.26±2.20	
P value	0.001	

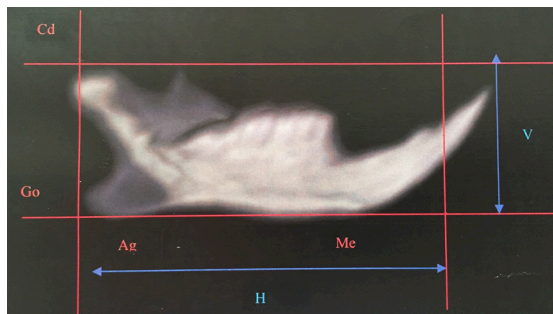


Figure 1. Four lines were drawn in order to determine the length of the mandible. First line was drawn tangent to the menton (Me) and antegenion (Ag) points whereas the second line passed through the condylar peak point parallel to the first line. The distance between these two lines were determined as the vertical length (VL). Then, two lines perpendicular to the first two lines were drawn that passed from the anterior and posterior terminal points of the mandible. The distance between the intersections points in the horizontal plane were named as horizontal length (HL).

Microscopic evaluation

Normal structures of pulp, dentin and enamel in all teeth were observed in the 14th day control group (Figure 2). On the other hand, unerupted incisor and molar teeth were observed at different stages of osteogenesis in the 14th day pamidronate group (Figure 3). Morphological malformations; irregular dentin formation as well as shrinkage in the pulp chamber were noted in tooth germs. Enamel and dentin were seen in the first and second molars but dentin was thin and irregular while predentin was wide. The enamel had irregular thickness but was mostly thin.

There was no enamel formation in third molars, odontoblast arrangement was irregular and dentinal tissue contained mixamatus degenerations. All teeth in the 30th day control group erupted and there were no histological or morphological malformations (Figure 4) whereas, 30th day pamidronate group disclosed erupted hypoplastic incisor teeth and unerupted molar teeth. Structural malformation of the teeth germs were also seen (Figure 5). The number of osteoclasts in the 14th day pamidronate group was statistically less than that of the 14th day control group (p=0.001) (Table 2).

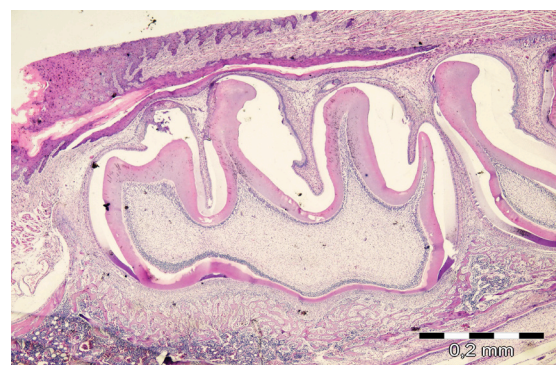


Figure 2. A first molar tooth germ with normal structure (H&E X40).

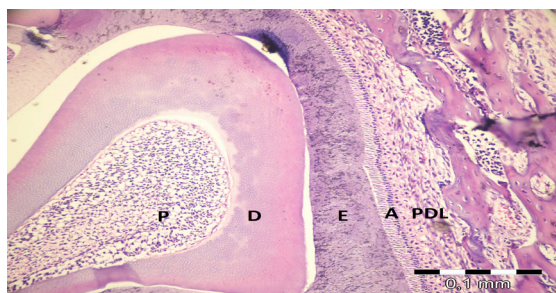


Figure 3. Pulp (P)-Dentin (D)-Enamel (E)-Ameloblasts (A) and Periodontal ligament (PDL) with normal structures. (H&E X200). Specimen from the 14th day control group.

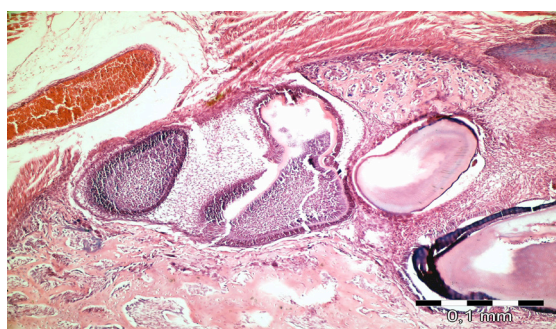


Figure 4. Molar teeth germ with developmental malformations that have occurred at different stages of odontogenesis. Specimen from the 14th day pamidronate group. (H&E X100).

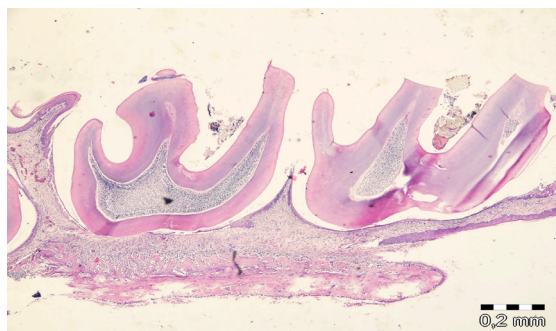


Figure 5. On the 30th day, all teeth in the control group were observed to be erupted and there were no histological or morphological malformation (H&E X40).

Discussion

BPs are the first choice of drugs in the treatment of osteoporosis and bone metastasis of various types of cancers due to their inhibiting osteoclastic activity and antiangiogenic properties. Evidence shows that BPs might have beneficial effects in pediatric, as well as adult patients (5). BPs are deposited in the bone and remain in the body for a long period of time

which restricts their use in children. Pamidronate is a nitrogen-containing BP which is being increasingly used in children, particularly for osteoporotic disorders. Therefore, we aimed to evaluate the effects of pamidronate in this study.

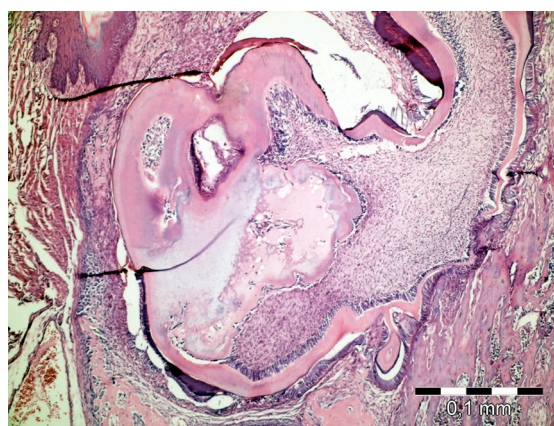


Figure 6. An impacted molar tooth germ from the 30th day pamidronate group with structural malformations (H&E X100).

Tooth eruption is a process that occurs via sequential mechanisms including tooth development and bone remodeling. Osteoclastic bone resorption accompanies tooth development and eruption thus; it is expected that BPs administered during childhood will possibly affect these processes. Previous studies have shown that treatment with BPs including zoledronic acid, pamidronate and alendronate during tooth development might cause delays or completely inhibit tooth eruption (1, 2, 11, 13). Kamoun-Goldrat *et al.* (13) observed 33 children (age range 6.2 to 14.6 years) with osteogenesis imperfecta receiving nitrogen containing bisphosphonate drugs. They concluded that bisphosphonate therapy is responsible for delayed tooth eruption and this delay is independent from therapy duration but dose dependent. Grier and Wise (11) reported delay in tooth eruption of 8 days for the mandibular first molar, 1.6 days for the mandibular incisors and 2.5 days for the maxillary incisors in pamidronate injected rats. Hiraga *et al.* (1) reported inhibition of eruption and root formation of molar and incisor teeth in 7-day-old rats injected with zoledronic acid. However, when 14-day-old rats were injected with zoledronic acid, partial erupted molars continued erupting whereas, full bony covered teeth could not erupt. These results suggested that, bisphosphonate-induced delay in eruption of teeth is dependent on the individual developmental stage of a tooth. The

findings of the current study also support the evidence that shows a delay in the teeth eruption. More definite results can be obtained when the observation period of the tooth eruption exceeds 30 days (period of this study) concerning eruption period in the rats.

In this study, enamel and dentin malformations were observed in both erupted and developing teeth in the pamidronate groups. Irregular structure and thickness in dentin and enamel tissues, myxomatous degeneration, and morphologic disruptions in tooth germs, narrowed pulp chamber were evident in the pamidronate group. These findings are consistent with those reported by Fouda *et al.* (14) and Hiraga *et al.* (1) but in contrast with the study by Grier and Wise (11). The latter authors stated that there was no significant effect of BPs on the formation and morphology of tooth germs. We think that one may expect dental malformations in patients who are administered BPs during tooth development. This finding should be further supported with clinical investigations and long-term observations. Osteoclastic bone resorption is an important component of the teeth eruption process. The action mechanism of BPs is directly based on inhibition of the osteoclastic activity; therefore, it is expected that they may cause alteration in the tooth formation and eruption process. Grier and Wise (11) stated that there was no difference between the number of osteoclasts in pamidronate-treated and control rats; however, they observed an increase in the osteoclast size and number of nuclei per osteoclast were found to be two times greater than the controls. They also emphasized that osteoclasts try to make up for the loss in the activity by growing their size. Higara *et al.* (1) and Bradaschia-Correa *et al.* (15) reported partial or total ankylosis between tooth surface and alveolar bone due to BP administration; however, in this study we did not observe the presence of ankylosis in partially erupted or impacted teeth. The number osteoclasts, thus resorption of alveolar bone decreased in the pamidronate groups which we believe is the reason for delayed tooth eruption. We only compared the number of osteoclasts between the 14th day pamidronate and control groups, because teeth in the 30th day control group erupted resorbing the alveolar bone. Information regarding the effects of bisphosphonates on facial growth is limited. The mandibular condyle that develops by endochondral ossification is a mandibular growth site. In the endochondral bone growth of the condyle, the proliferative layer which is located under the fibrous layer that covers the temporomandibular

joint effects the length of the mandibular ramus. It provides chondrocytes and is essential for mandibular condyle growth (16-18). Bradaschia-Correa *et al.* (2) investigated the effects of alendronate on endochondral ossification in mandibular condyles of new born rats. They found that alendronate has limited the removal of calcified cartilage and maturation of bone trabeculae in the mandibular ramus. Alendronate treatment was observed to significantly alter endochondral ossification. According to Kimura *et al.* (19) alendronate inhibited longitudinal growth of mandibular condyle by inhibiting chondrocyte proliferation and the resorption of hypertrophied cartilage for ossification. In the present study, pamidronate administration not only inhibited tooth eruption but also negatively affected mandibular growth pattern. Mandibular height and length of the study groups were statistically shorter than the control groups. It is not possible to make an objective explanation for this finding because mandibular condyles were not histologically examined.

Conclusion

Our results suggest that treatment with pamidronate during tooth development may disrupt tooth eruption, formation and morphology, as well as mandibular growth pattern in new born rats. Our findings should be further supported by clinical trials to determine the extent of the effects of BP therapy on tooth development and facial growth in pediatric population.

Conflict of interest

None declared.

Source of funding

None declared.

References

1. Hiraga T, Ninomiya T, Hosoya A, Nakamura H. Administration of the bisphosphonate zoledronic acid during tooth development inhibits tooth eruption and formation and induces dental abnormalities in rats. *Calcif Tissue Int* 2010;86(6):502-510.
2. Bradaschia-Correa V, Massa LF, Arana-Chavez VE. Effects of alendronate on tooth eruption and molar root formation in young growing rats. *Cell Tissue Res* 2007;330(3):475-485.

3. Rogers MJ, Gordon S, Benford HL, Coxon FP, Luckman SP, Monkkonen J, Frith JC. Cellular and molecular mechanisms of action of bisphosphonates. *Cancer* 2000;88(12 Suppl):2961-2978.
4. Vasikaran SD. Bisphosphonates: An overview with special reference to alendronate. *Ann Clin Biochem* 2001;38(Pt 6):608-623.
5. Bachrach LK, Ward LM. Clinical review 1: Bisphosphonate use in childhood osteoporosis. *J Clin Endocrinol Metab* 2009;94(2):400-409.
6. Castillo H, Samson-Fang L, American Academy for Cerebral P, Developmental Medicine Treatment Outcomes Committee Review P. Effects of bisphosphonates in children with osteogenesis imperfecta: An AACPDM systematic review. *Dev Med Child Neurol* 2009;51(1):17-29.
7. Wise GE, King GJ. Mechanisms of tooth eruption and orthodontic tooth movement. *J Dent Res* 2008;87(5):414-434.
8. Chilbule SK, Madhuri V. Complications of pamidronate therapy in paediatric osteoporosis. *J Child Orthop* 2012;6(1):37-43.
9. Piper K, Boyde A, Jones SJ. The effect of 3-amino-1-hydroxypropylidene-1,1-bisphosphonate (APD) on the resorptive function of osteoclasts of known nuclear number. *Calcif Tissue Int* 1994;54(1):56-61.
10. Reitsma PH, Bijvoet OL, Verlinden-Ooms H, van der Wee-Pals LJ. Kinetic studies of bone and mineral metabolism during treatment with (3-amino-1-hydroxypropylidene)-1,1-bisphosphonate (APD) in rats. *Calcif Tissue Int* 1980;32(2):145-157.
11. Grier RL, Wise GE. Inhibition of tooth eruption in the rat by a bisphosphonate. *J Dent Res* 1998;77(1):8-15.
12. Fujita Y, Konoo T, Maki K. Short-term etidronate treatment prevents glucocorticoid-induced bone debility of the mandible in growing rats. *Orthod Craniofac Res* 2008;11(4):187-195.
13. Kamoun-Goldrat A, Ginisty D, Le Merrer M. Effects of bisphosphonates on tooth eruption in children with osteogenesis imperfecta. *Eur J Oral Sci* 2008;116(3):195-198.
14. Fouda N, Caracatsanis M, Kut IA, Hammarstrom L. Mineralization disturbances of the developing rat molar induced by mono- and bisphosphonates. *J Biol Buccale* 1991;19(1):106-115.
15. Bradaschia-Correa V, Barrence FA, Ferreira LB, Massa LF, Arana-Chavez VE. Effect of alendronate on endochondral ossification in mandibular condyles of growing rats. *Eur J Histochem* 2012;56(2):e24.
16. Anil S, Preethanath RS, AlMoharib HS, Kamath KP, Anand PS. Impact of osteoporosis and its treatment on oral health. *Am J Med Sci* 2013;346(5):396-401.
17. Evans KD, Lau ST, Oberbauer AM, Martin RB. Alendronate affects long bone length and growth plate morphology in the oim mouse model for osteogenesis imperfecta. *Bone* 2003;32(3):268-274.
18. Kim MS, Jung SY, Kang JH, Kim HJ, Ko HM, Jung JY, Koh JT, Kim WJ, Kim SM, Lee EJ, Kim SH. Effects of bisphosphonate on the endochondral bone formation of the mandibular condyle. *Anat Histol Embryol* 2009;38(5):321-326.
19. Kimura M, Miyazawa K, Tabuchi M, Maeda H, Kameyama Y, Goto S. Bisphosphonate treatment increases the size of the mandibular condyle and normalizes growth of the mandibular ramus in osteoprotegerin-deficient mice. *Calcif Tissue Int* 2008;82(2):137-147.

Corresponding Author:**Çağrı DELİLBAŞI**

Department of Oral and Maxillofacial Surgery
 Faculty of Dentistry Istanbul Medipol University
 34083 Unkapani-Fatih-Istanbul/Turkey
 Phone: +90 212 453 49 50
 e-mail: cdelilbasi@yahoo.com