

DENTAL FINDINGS IN MARFAN SYNDROME: A CASE REPORT

Marfan Sendromunda Dental Bulgular: Olgu Sunumu

Büşra BOSTANCI¹, Emre KORKUT², Nimet ÜNLÜ³

Received: 17/08/2016

Accepted: 18/01/2017

ABSTRACT

Marfan syndrome is an autosomal dominant disorder of connective tissue primarily characterized with anomalies affecting the musculoskeletal system, the cardiovascular system and the eyes. It has been suggested that early diagnosis of the syndrome is important, because of the risk of infective endocarditis. A 7-year-old female was referred to our clinic, with a chief complaint of dental crowding in the anterior region of mandible. It was observed that the patient needed multiple treatments based on detailed clinical and radiographic examinations. The treatment was carried out with antibiotic prophylaxis an hour prior to her appointment considering her profound caries. The patient was advised to visit regularly for follow up and she was referred for orthodontic evaluation.

Keywords: Marfan syndrome; dental management; antibiotic prophylaxis; infective endocarditis.

ÖZ

Marfan sendromu, öncelikle kas-iskelet sistemi, kalp-damar sistemi ve gözleri etkileyen anomaliler ile karakterize, otozomal dominant bir bağ dokusu hastalığıdır. Enfektif endokardit riski nedeniyle sendromun erken tanısının önemli olduğu ileri sürülmektedir. 7 yaşındaki kadın hasta alt çenenin ön bölgesindeki dişlerin çapraşıklığı şikâyeti ile kliniğimize başvurdu. Ayrıntılı klinik ve radyografik muayene sonucu hastanın çoklu tedavi ihtiyacı olduğu belirlendi. Hastanın derin çürükleri dikkate tedaviler girişimden bir saat önce olacak şekilde tasarlanan antibiyotik profilaksisi altında gerçekleştirildi. Hastaya diş hekimine düzenli olarak gelmesi önerildi ve ortodontik değerlendirilmeye yönlendirildi.

Anahtar kelimeler: Marfan sendromu; dental tedavi; antibiyotik profilaksi; enfektif endokardit.

¹ Department of Pediatric Dentistry Faculty of Dentistry Abant İzzet Baysal University

² Department of Pediatric Dentistry Faculty of Dentistry Konya Necmettin Erbakan University

³ Department of Restorative Dentistry Faculty of Dentistry Konya Necmettin Erbakan University



Introduction

Marfan syndrome is an autosomal dominant disorder of connective tissue primarily characterized with anomalies affecting the musculoskeletal system, the cardiovascular system and the eyes (1, 2). The incidence of Marfan syndrome is approximately 1:5000 with no reported difference between gender, ethnic and geographic groups (3-5). Marfan syndrome arises out of mutation in the fibrillin-1 gene (FBN1) encoding the elastic fibers, a major component of connective tissue. This gene is localized in chromosome 15 (15q21) (6, 7). Mutations in the fibrillin-1 gene may present in 92% patients with Marfan syndrome (8). Fibrillin is an important part of connective tissue, the diseases of which can affect several parts of the body; such as skin, muscles, skeleton, pulmonary system, blood vessels in varying degrees (3, 7). However, patients with this syndrome have some typical clinical manifestations including tall and slender structure, mitral valve prolapse, aortic disorders, ectopia lentis, positive thumb and wrist signs (4, 9). This syndrome may be asymptomatic. Diagnosis of Marfan syndrome relies therefore on previously defined clinical criteria (Ghent nosology); family/genetic history, organ system disorders and molecular data (10). Marfan syndrome may be difficult to diagnose, especially in children. Orofacial characteristics comprising long and narrow face, maxillary/mandibular retrognathia, temporomandibular joint alterations, high arched palate, dental crowding, posterior crossbite, periodontal conditions may be beneficial in identification of the syndrome (11-13). Nevertheless, symptoms severity varies within and between individuals (14). The early diagnosis of the syndrome is important, because of the risk of infective endocarditis (5, 15). In this regard, pediatric dentists bears significant responsibility. However, the orofacial manifestations of the Marfan syndrome have not been sufficiently described in the literature. Therefore, the purpose of this article was to present a case report of the orofacial manifestations of this syndrome.

Case Report

A 7-year-old female was referred to Department of Pediatric Dentistry along with her father, with a chief complaint of dental crowding in the anterior region of mandible. Based on her medical history, she had ophthalmic problems including V pattern strabismus, high myopia, as well as cardiac disorders

including mitral valve prolapse, mitral regurgitation, tricuspid valve prolapse, tricuspid regurgitation, sinus aneurysm. Furthermore, she had undergone some genetic tests performed on the suspicion of Marfan syndrome. The family history revealed that none of the other members had similar problems, and she also had a twin brother who has no medical issues. She was not taking any medications. The patient's social and intellectual development was normal and she exhibited even more mature and cooperative behavior for dental treatment than her twin brother. On general examination, when compared to her twin brother, patient was taller and she had a slender structure, with lower part of her body being extended than the upper half. She was greater than 97th percentile for weight and height (135 cm in height, 22 kg in weight) (16). She had elongated arms, legs and fingers. The patient had positive wrist (Walker-Murdoch sign: the distal phalanx of the first and fifth fingers of the hand overlap when surrounded around the opposite wrist) and positive thumb (Steinberg sign: a flexed thumb clutched within a clenched palm protrudes beyond the ulnar border of that hand) evidence (Figure 1). Her skin was dry. Facial characteristics involved dolichocephaly, maxillary retrognathia, broad forehead, downward slanting palpebral fissures, prominent chin and convex profile.

Intraorally, the patient had a high arched palate, midline shift and class I malocclusion on the right side and class II malocclusion with posterior crossbite on the left side (Figure 2). Teeth showed anterior crowding in both the arches. Also, several profound caries on deciduous teeth and initial enamel caries on permanent first molars were observed. Patient was consulted with the department of cardiology to assess the risk of infective endocarditis considering cardiac disorders. Risk was found to be significant and infective antibiotic prophylaxis was recommended. Meanwhile, the diagnosis of Marfan syndrome was confirmed. Patient and her parents were informed about the treatment plan, and written and verbal consents were obtained. Intraoral and extraoral photographs were taken and radiographic examination was done by using orthopantomograph and hand-wrist radiograph (Figure 2, Figure 3, Figure 4). Two digit FDI numbering system was used for chart entry. As a result, profound caries was recorded in 53, 54, 55, 63, 64, 65, 83, 84, 74, 75 and initial enamel caries in the pits and fissures of 16, 26, 36, 46. She had black-stains in her teeth and mild gingivitis (Figure 2). In order to make the child's initial contact with the dentist

more pleasant, the first visit was ended with only pumice prophylaxis and oral hygiene motivation was given. On subsequent appointments, the permanent first molar teeth were sealed with resin based fissure sealant (Clinpro Sealant, 3M ESPE, St. Paul, MN, USA) and fluoride containing varnish (Colgate Duraphat Fluoride Varnish, Colgate- Palmolive (UK) Ltd, England) was applied each segment of the jaws and the caries in deciduous teeth were restored with compomer resins (Glasiosite Caps, Voco, Cuxhaven, Germany) under local anesthesia in the Department of Pediatric Dentistry. The treatment was carried

out following 50 mg/kg amoxicillin antibiotic prophylaxis an hour prior to the dental visit. Patient was later referred for orthodontic evaluation. Clinical photographs were taken after restorative treatments were completed (Figure 5). Patient and her parents were informed about the possibility of new dental caries and they were advised to mind the oral hygiene and to visit regularly for check-up.

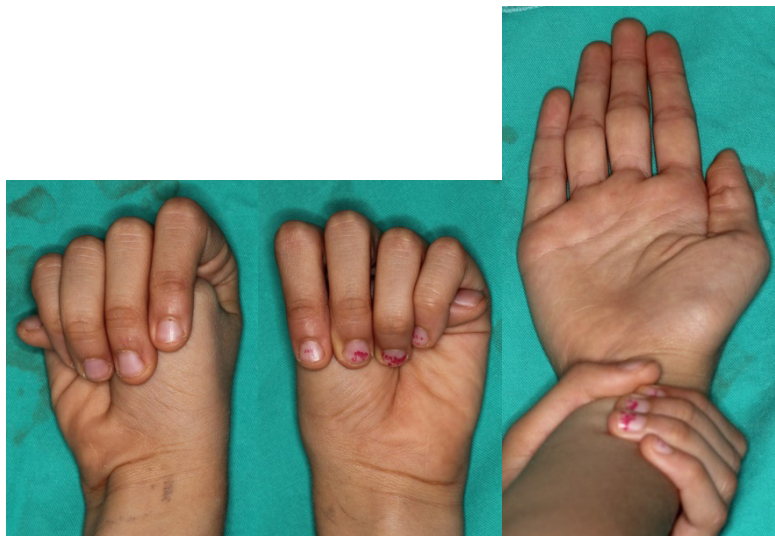


Figure 1. Positive thumb and wrist signs (positive wrist-Walker-Murdoch sign-the distal phalanx of the first and fifth fingers of the hand overlap when surrounded around the opponent wrist and positive thumb-Steinberg sign-a flexed thumb clutched within a clenched palm protrudes beyond the ulnar border of that hand)

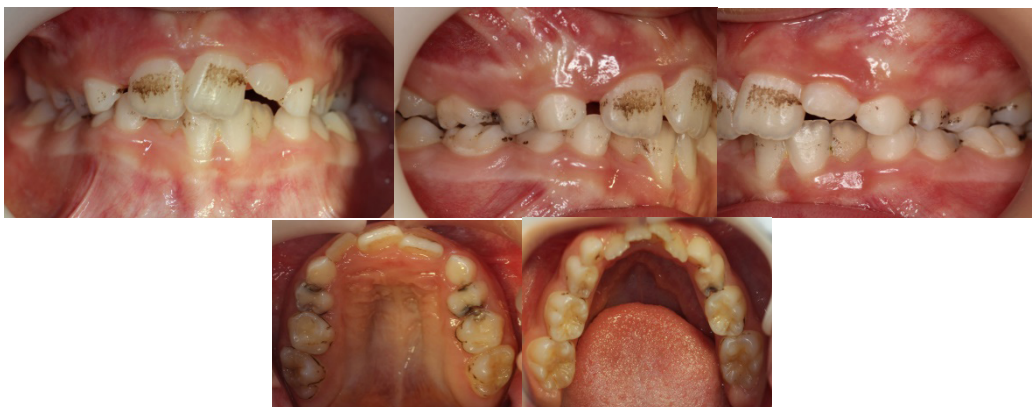

Figure 2. Pretreatment clinical photographs showing profound caries and stains on teeth.

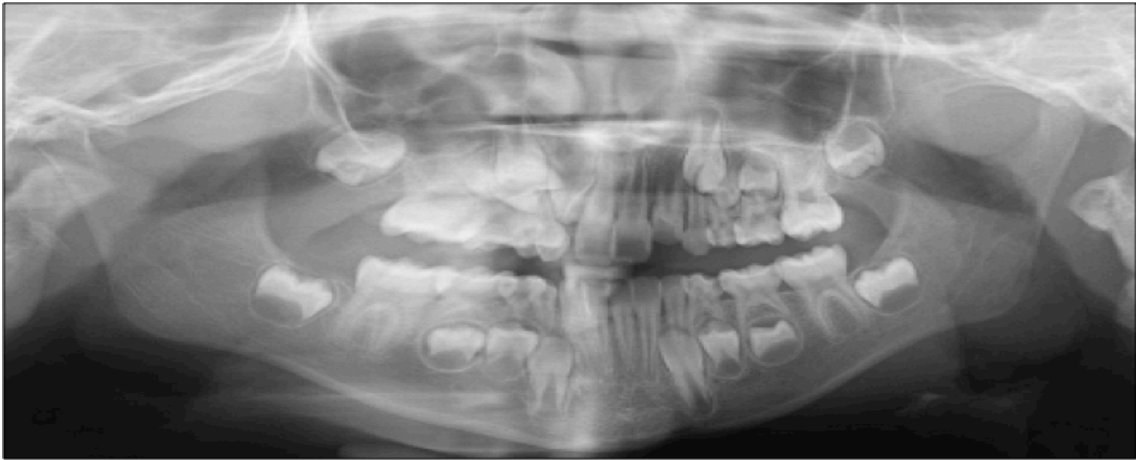

Figure 3. Panoramic radiography of the patient taken before dental treatment.

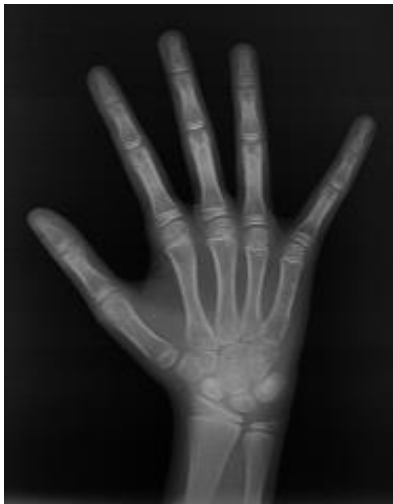

Figure 4. Hand-wrist radiograph.

Discussion

Marfan syndrome is a hereditary disorder that affects multiple organs and systems (4). Clinical appearance and severity of the condition varies among individuals with Marfan syndrome, even within the same family. The majority of people with Marfan syndrome do not have all the characteristic features and/or complications associated with this syndrome. In some cases, the condition may not be recognized by parents and may be asymptomatic (17, 18). In this case, all of the three systems, which are the most commonly affected by this syndrome, had malformations and her twin brother was healthy. Family history revealed no previously diagnosed individual in her family with this syndrome but her grandfather had suffered from heart disease and he had long limbs.

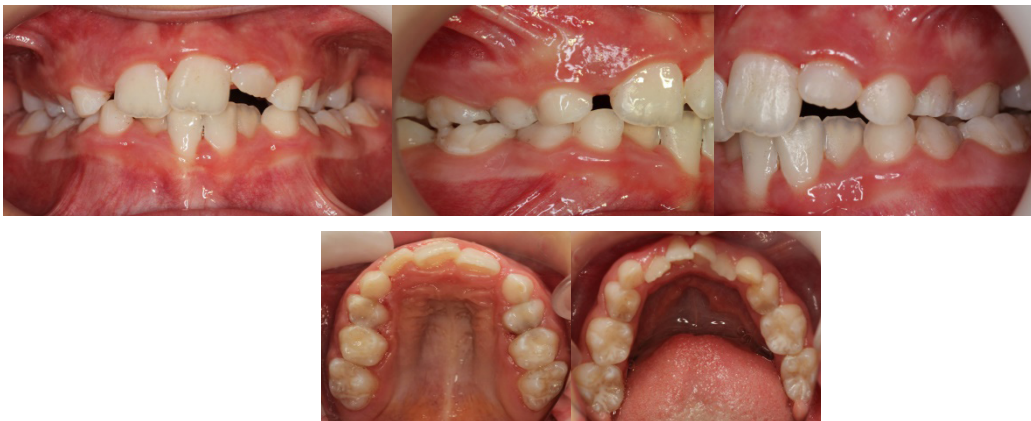

Figure 5. Intraoral photographs taken after restorative treatment was completed.

The syndrome primarily involves the malformations of skeletal, cardiovascular and ocular systems. The most common manifestations of the syndrome are disproportionately tall and slender structure, long arms, legs and fingers, pectus deformities and scoliosis, and often using eyeglasses because of severe myopia (5, 9, 19). The most serious problems associated with Marfan syndrome include the cardiovascular system, and commonly the wall of the aorta can become weakened and stretched (aortic dilatation). Patients may have sinus arrhythmia associated with mitral valve prolapse. Cardiac insufficiency may occur over time if not controlled adequately. The other cardiovascular problems include thoracic aortic dilatation/rupture, aortic regurgitation, mitral regurgitation, and abdominal aortic aneurysm. Furthermore, dentists has an important role in terms of the risk of infective endocarditis that may occur during invasive dental treatments, which should not be overlooked (20). The 90% of individuals with Marfan syndrome has cardiac disorders. These problems constitute the main cause of morbidity and mortality for these patients (20, 21). Dental care for patients with Marfan syndrome is important to minimize the treatment need that could increase the risk of bacteraemia. Hence, periodic oral examination must be carried out. Cardiovascular disorders seen in this case were mitral valve prolapse, mitral regurgitation, tricuspid valve prolapse, tricuspid regurgitation, and sinus aneurysm. These conditions did not require any surgery or medication.

The most common ocular problems include ectopia lentis, glaucoma and severe myopia; strabismus, enophthalmos, retinal lattice degeneration, retinal detachment, unstable refraction are the less frequent manifestations of the syndrome (22). V pattern strabismus, enophthalmos, and high myopia were the ocular problems in our patient. Consistently, she was using glasses since childhood. She also had a typical eye appearance which is described as having down-slanting palpebral fissures. The patients with Marfan syndrome have pulmonary alterations including increased risk of asthma, emphysema, bronchitis, pneumonia; and dermatological alterations including decline of skin elasticity and formation of striae on the skin (23, 24). Orofacial features of Marfan syndrome include dolichocephaly, malar hypoplasia, long and narrow face, frontal bossing, prominent supraorbital ridges, maxillary and mandibular retrognathia, skeletal malocclusion, hypermobility of the temporomandibular joint. Furthermore, the

patients need to have orthodontic treatment because of having high arched palate, dental crowding, and posterior openbite. Uteja *et al.* (12) stated that it is important for the patients with Marfan syndrome to initiate the orthodontic treatment at an early age to limit the need for surgical procedures. Westlig *et al.* (13) found that 50% of the patients with Marfan syndrome had high and deep palates. In the present case, most of these manifestations were observed such as the presence of high and narrow palate arches, posterior cross-bite and crowding but, fortunately, patient was identified and treatment initiated early.

Developmental abnormalities of the teeth may also be evident among which the supernumerary teeth is the most common. More rarely; enamel defects, dentinogenesis imperfecta, dysplasia of teeth and cysts formation in the jaws have been reported (11, 25-28). De Coster *et al.* (11) evaluated the patients with Marfan syndrome in a case-control study for cariologic and periodontal alterations. It was reported that patients whose enamel hypoplasia is frequently seen are at high risk of caries. Radicular deformations and pulp obliterations were also reported as common findings. Endodontic treatment may therefore be necessary for some patients. However, no developmental dental anomalies was observed in the present case. Patients with this syndrome may have increased prevalence of gingivitis and periodontitis due to the excessive concentration of elastic fibers in the periodontal tissues (29).

Periodontal problems may also be related to the difficulty of effective brushing because of the high-arched palate and mouth breathing which particularly affects the anterior region (30). Parents' awareness and their knowledge of the patient's special needs are very important. Regular dental visits, oral hygiene motivation and preventive management may help to avoid having complex and invasive treatments. In addition, Tsang *et al.* (28) and Morales-Chavez *et al.* (26) reported that patients with Marfan syndrome could be anxious and may not comply well with dental treatment which, in turn, may require the use of sedation or general anesthesia (25, 26, 28). On the contrary, present case was cooperative during the treatment. In the literature, systemic manifestations of Marfan syndrome have been published on many occasions (11, 26-28), however, relatively few articles are available regarding the orofacial findings of this syndrome (11-13, 25, 26, 28, 29).

Conclusion

Dental management in Marfan syndrome requires the use of customized treatment plans which focus on the special needs of the patients. Treatment may even not be necessary for some individuals with the syndrome but all patients should be advised to have regular dental visits. The early diagnosis and medical management of the syndrome considerably increases patient's quality of life. Pediatric dentists should be aware of this condition and its differential diagnosis, given that the characteristic orofacial findings of Marfan syndrome and high caries incidence can lead patients to have specialized treatment.

Source of funding

None declared.

Conflict of Interest

None declared.

References

- McKusick VA. Heritable disorders of connective tissue. III. The Marfan syndrome. *J Chronic Dis* 1955;2(6):609-644.
- Shirley ED, Sponseller PD. Marfan syndrome. *J Am Acad Orthop Surg* 2009;17(9):572-581.
- Dietz HC, Cutting GR, Pyeritz RE, Maslen CL, Sakai LY, Corson GM, Puffenberger EG, Hamosh A, Nanthakumar EJ, Curristin SM, et al. Marfan syndrome caused by a recurrent de novo missense mutation in the fibrillin gene. *Nature* 1991;352(6333):337-339.
- Hirst AE, Jr., Gore I. Marfan's syndrome: A review. *Prog Cardiovasc Dis* 1973;16(2):187-198.
- Rybczynski M, Bernhardt AM, Rehder U, Fuisting B, Meiss L, Voss U, Habermann C, Detter C, Robinson PN, Arslan-Kirchner M, Schmidtke J, Mir TS, Berger J, Meinertz T, von Kodolitsch Y. The spectrum of syndromes and manifestations in individuals screened for suspected Marfan syndrome. *Am J Med Genet A* 2008;146A(24):3157-3166.
- Dean JC. Management of Marfan syndrome. *Heart* 2002;88(1):97-103.
- Maslen CL, Corson GM, Maddox BK, Glanville RW, Sakai LY. Partial sequence of a candidate gene for the Marfan syndrome. *Nature* 1991;352(6333):334-337.
- Biros E, Walker PJ, Nataatmadja M, West M, Golledge J. Downregulation of transforming growth factor, beta receptor 2 and notch signaling pathway in human abdominal aortic aneurysm. *Atherosclerosis* 2012;221(2):383-386.
- Grimes SJ, Acheson LS, Matthews AL, Wiesner GL. Clinical consult: Marfan syndrome. *Prim Care* 2004;31(3):739-742.
- Loeys BL, Dietz HC, Braverman AC, Callewaert BL, De Backer J, Devereux RB, Hilhorst-Hofstee Y, Jondeau G, Faivre L, Milewicz DM, Pyeritz RE, Sponseller PD, Wordworth P, De Paepe AM. The revised ghent nosology for the marfan syndrome. *J Med Genet* 2010;47(7):476-485.
- De Coster PJ, Martens LC, De Paepe A. Oral manifestations of patients with Marfan syndrome: A case-control study. *Oral Surg Oral Med Oral Pathol Oral Radiol Endod* 2002;93(5):564-572.
- Utreja A, Evans CA. Marfan syndrome-an orthodontic perspective. *Angle Orthod* 2009;79(2):394-400.
- Westling L, Mohlin B, Bresin A. Craniofacial manifestations in the marfan syndrome: Palatal dimensions and a comparative cephalometric analysis. *J Craniofac Genet Dev Biol* 1998;18(4):211-218.
- S. Judith, F. Rebecca, T. Gale, "Marfan Syndrome," *Gale Encyclopedia of Children's Health: Infancy through Adolescence*, 2006. Available from: http://www.encyclopedia.com/topic/Marfan_Syndrome.aspx.
- Jaiswal S, Magar BS, Poudel M, Joshi LN, Neopane A, Karki DB. Marfan's syndrome with aortic valve endocarditis. *Kathmandu Univ Med J (KUMJ)* 2004;2(3):230-233.
- Nwosu BU, Lee MM. Evaluation of short and tall stature in children. *Am Fam Physician* 2008;78(5):597-604.
- De Paepe A, Devereux RB, Dietz HC, Hennekam RC, Pyeritz RE. Revised diagnostic criteria for the Marfan syndrome. *Am J Med Genet* 1996;62(4):417-426.
- Dietz HC, McIntosh I, Sakai LY, Corson GM, Chalberg SC, Pyeritz RE, Francomano CA. Four novel fbn1 mutations: Significance for mutant transcript level and egf-like domain calcium binding in the pathogenesis of Marfan syndrome. *Genomics* 1993;17(2):468-475.
- Ammash NM, Sundt TM, Connolly HM. Marfan syndrome-diagnosis and management. *Curr Probl Cardiol* 2008;33(1):7-39.

20. Suzuki J, Aoyama N, Izumi Y, Isobe M, Komuro I, Hirata Y. Effect of periodontitis on cardiovascular manifestations in Marfan syndrome. Critical common role of tgf-beta. *Int Heart J* 2015;56(2):121-124.
21. Murdoch JL, Walker BA, Halpern BL, Kuzma JW, McKusick VA. Life expectancy and causes of death in the Marfan syndrome. *N Engl J Med* 1972;286(15):804-808.
22. Kumar A, Agarwal S. Marfan syndrome: An eyesight of syndrome. *Meta Gene* 2014;2:96-105.
23. Dyhdalo K, Farver C. Pulmonary histologic changes in marfan syndrome: A case series and literature review. *Am J Clin Pathol* 2011;136(6):857-863.
24. Gray JR, Bridges AB, West RR, McLeish L, Stuart AG, Dean JC, Porteous ME, Boxer M, Davies SJ. Life expectancy in British Marfan syndrome populations. *Clin Genet* 1998;54(2):124-128.
25. Ganesh R, Vijayakumar R, Selvakumar H. Marfan syndrome: A case report. *Case Rep Dent* 2012;2012:595343.
26. Morales-Chavez MC, Rodriguez-Lopez MV. Dental treatment of marfan syndrome. With regard to a case. *Med Oral Patol Oral Cir Bucal* 2010;15(6):e859-862.
27. Randhawa AK, Mishra C, Gogineni SB, Shetty S. Marfan syndrome: Report of two cases with review of literature. *Niger J Clin Pract* 2012;15(3):364-368.
28. Tsang AK, Taverne A, Holcombe T. Marfan syndrome: A review of the literature and case report. *Spec Care Dentist* 2013;33(5):248-254.
29. Staufenbiel I, Hauschild C, Kahl-Nieke B, Vahle-Hinz E, von Kodolitsch Y, Berner M, Bauss O, Geurtsen W, Rahman A. Periodontal conditions in patients with marfan syndrome - a multicenter case control study. *BMC Oral Health* 2013;13:59.
30. Cistulli PA, Sullivan CE. Influence of maxillary morphology on nasal airway resistance in Marfan's syndrome. *Acta Otolaryngol* 2000;120(3):410-413.

Corresponding Author:**Büşra BOSTANCI**

Department of Pediatric Dentistry

Faculty of Dentistry Abant İzzet Baysal University

14030, Bolu /Turkey

Phone: +90 3742541000/8428 (ext)

e-mail: dtbusrabostancii@gmail.com