

Absence of Costal Element of The Foramen Transversarium of Atlas Vertebrae: A Case Report

Foramen Transversarium'unda Kostal Elementi Gelişmemiş

Bir Atlas Omuru: Olgu Sunumu

Hüseyin Baylan¹, Gökşin Nilüfer Yonguç², Mürvet Hayran³,

¹ Department of Anatomy, Faculty of Medicine, Sakarya University, Sakarya, Turkey

² Department of Anatomy, Faculty of Medicine, 9 Eylül University, İzmir, Turkey

³ Department of Anatomy, Faculty of Medicine, İzmir Ekonomi University, İzmir, Turkey

Yazışma Adresi / Correspondence:

Hüseyin Baylan

Sakarya University, Faculty of Medicine, Department of Medical Anatomy, Adapazari,
Sakarya, 54290, Turkey

T: +90 264 2953139 E-mail: hbgitar@gmail.com

Geliş Tarihi / Received : 21.03.2018 Kabul Tarihi / Accepted : 29.05.2018

Abstract

We detected an atlas vertebra of which costal elements of its foramen transversarium were not developed bilaterally. The costal element is an arch of bone that form the anterior portion of foramen transversarium. The vertebral arteries running towards cranial cavity are surrounded and protected by foramina transversarium of upper six cervical vertebrae. Surgeons should be aware of this variation before operations to neck region, because the vertebral arteries may easily be injured due to lack of anterior bony protection of the costal elements. As well as the vertebral artery, the nerve plexus around vertebral artery may also be responsible of some complications due to failure of this bony protection. (*Sakarya Med J*, 2018, 8(2):442-446)

Keywords

Atlas; transverse foramen; variation; costal element

Öz

Objective: Foramen transversarium'larında kostal elementleri bilateral olarak gelişmemiş bir atlas omuru tespit ettik. Kostal element foramen transversarium'un anterior kısmını oluşturan kemikten bir kemerdir. Kranial kaviteye doğru yönelen arteria vertebralis, üst altı servikal omurun foramen transversarium'ları tarafından çevrilir ve korunur. Cerrahlar boyun bölgesine yapılan cerrahi operasyonlar öncesinde kostal elementin yokluğu varyasyonundan haberdar olmalıdır, çünkü arteria vertebralis kostal elementlerce sağlanan kemik korumasından yoksun kaldığından dolayı daha kolayca zedelenebilir. Ayrıca arterin etrafında bulunan sinir pleksusu da zedeleneleme bağlı komplikasyonlara yol açabilir. (*Sakarya Tıp Dergisi*, 2018, 8(2):442-446).

Anahtar kelimeler

Atlas; foramen transversarium; varyasyon; kostal element

Introduction

Between the occipital bone and the second cervical vertebra is the atlas that has attachment areas for some muscles functioning in head movements and balance. The atlas having neither body (corpus vertebrae in Latin) nor spinous process (processus spinosus in Latin) is among atypical vertebrae with a short anterior and long posterior arches (figure 1).

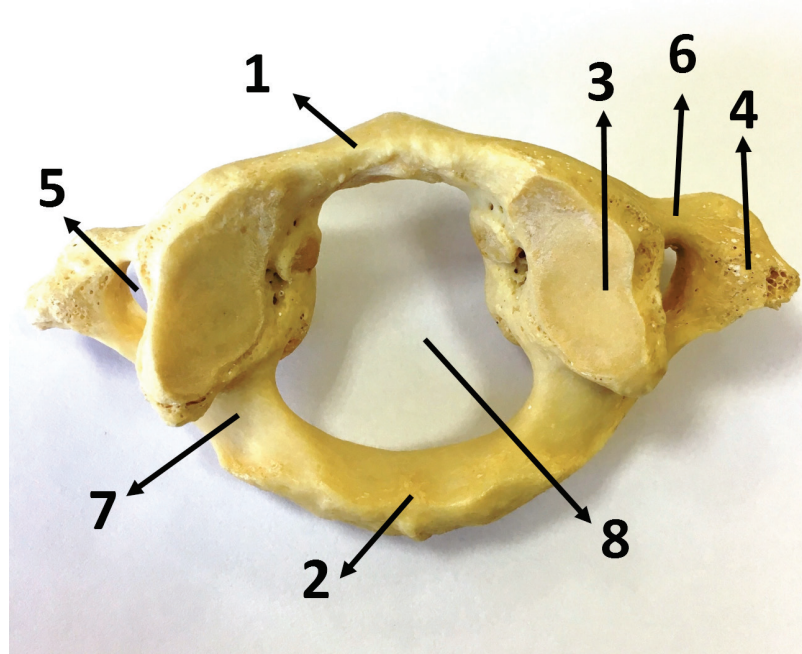


Figure 1: Atlas (1st cervical vertebra) (superior aspect)

1. Anterior arch (Arcus anterior in Latin)
2. Posterior arch (Arcus posterior in Latin)
3. Superior articular surface (facies articularis superior in Latin)
4. Transverse process (Processus transversus in Latin)
5. Transverse foramen (foramen transversarium in Latin)
6. Costal element
7. Groove for vertebral artery (sulcus arteria vertebralis in Latin)
8. Vertebral foramen (Foramen vertebrale in Latin)

Two thick lateral masses that bind the anterior and posterior arches have joint areas for the occipital condyles and the axis (2nd cervical vertebra). The longest transverse processes among upper six cervical vertebrae are of the atlas, and the vertebral artery and a nervous plexus around the arteries are transmitted inside a bony covering called the foramen transversarium of the transverse processes.^{1,2} The anterior parts of each transverse processes are called 'costal element' or 'costal process' which refers that they are the homologue of the ribs.¹ The cervical spinal nerves emerge above the costotransverse bar where the anterior and posterior parts of the transverse processes unite laterally.²

Behind the lateral mass of the atlas, there is a groove over the posterior arch for the vertebral artery. The vertebral artery pierces the posterior atlantooccipital membrane along with the first cervical nerve and targets to foramen magnum.³ The vertebral arteries join together to form the

basilar artery anteriorly to the pons. These two arteries supply the meninges, dura mater of the posterior cranial fossa, cervical part of the spinal cord, brain stem, cerebellum and spinal ganglions, etc.⁴⁻⁶ Some significant anatomical structures close to the transverse processes of the atlas are the internal jugular vein, the styloid processes, and the cranial nerves X, XI, and XII.1,7

There are some other variations of the atlas in literature including incomplete unilateral or bilateral transverse foramen, complete or incomplete retroarticular foramen, accessory transverse foramina, and partial or total fusion of atlas with the occipital bone.^{1,5,8-11}

Case Report:

We detected a variation on atlas vertebra (Figure 2, 3, 4) in a routine laboratory demonstration. Anterior parts (costal elements) of foramen transversarium of the atlas were not developed bilaterally. The lengths of this variational atlas were measured with a standard calliper. The points determined for the measurements were set by mimicking the literature.³ The lengths of the vertebra are as follows in figure 3, figure 4, and table 1.

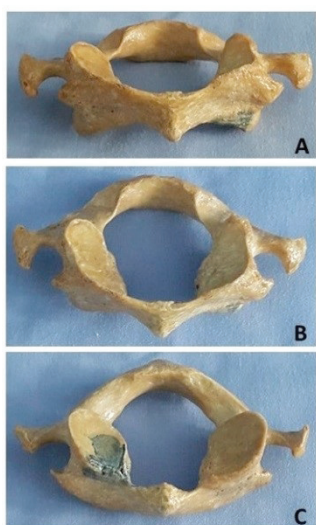


Figure 2: An atlas vertebra without costal elements
A: Anterior aspect B: Superior aspect C: inferior aspect

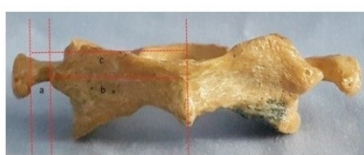


Figure 3

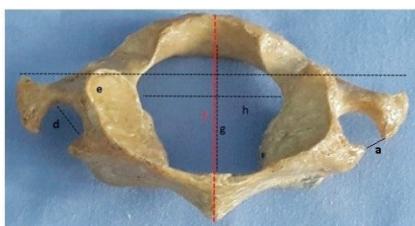


Figure 4

Table 1: Measured parameters			
Parameters	Figure (3 and 4)	Side	Distance (mm)
The distances of the anterior apertures of the transverse processes (between the lateral and medial edges of the apertures)	a	right	9,02
		left	7,16
The distances between the midline of the atlas and the medial edges of the apertures	b	right	33,09
		left	34,29
The distances between the midline of the atlas and the lateral edges of the apertures	c	right	40,12
		left	39,70
The maximal diameter of the transverse foramen	d	right	10,13
		left	9,02
The maximum width of the atlas	e		82,39
The external distance between the anterior and posterior tubercles of the atlas	f		48,51
The internal distance between the interior walls of anterior & posterior arches of the atlas	g		33,98
The latero-lateral distance of the vertebral foramen	h		30,76

* Except for the bilateral incomplete transverse processes, no other abnormality was detected.

Discussion:

The formation of the atlas in terms of its shape is affected by the head and neck posture.¹² The transverse process of the atlas is a crucial landmark in the neck operations.¹³ In literature, incomplete transverse foramen unilaterally or bilaterally are encountered.^{1, 8, 9}

In a study executed over 100 atlas vertebrae series of South Indian population, only two of the vertebrae had unilateral, and three had bilateral absence of costal element of the transverse processes.⁸ Another study of North Indian population reports that the absence of the costal element was found only in seven vertebrae among fifty atlas vertebrae.¹⁴

The embryological development is often suggested to be the aetiology of the variations.^{15,16} Especially the vertebral arteries filling more than half of the diameter of the foramen transversarium are postulated, because it is told that the tortuosity of the artery and bone erosion may change this diameter but this evidence is not enough for certain conclusion.^{2, 4, 5, 17-20}

The anatomical location of atlas and the structures in relation to it especially the vertebral Arteries enrich the symptoms due to pathologies of this region. For example the aetiology of Barre-Lieou syndrome, transient vertebrobasilar insufficiency and chronic upper cervical syndrome are related to development of atlas.²¹⁻²⁴

Besides one-fourth of the atlantoaxial complex injuries reported are told with damages to the atlas. Being rarely, the fractures of the transverse process may have vertebral arteries ruptured resulting in subarachnoid haemorrhages.²⁵⁻²⁷ Some other possible complications of vertebral artery injury are respiratory and cardiovascular impairments, the vertebrobasilar ischemia, diplopia, unconsciousness, vertigo, migraine, severe cerebrovascular accidents, and shoulder and neck pain.^{6, 28, 29} Therefore, in the cervical operations of the patients with incomplete transverse foramen, the surgeons should be careful more than usual to the defenceless vertebral arteries anteriorly in terms of preventing complications.^{8, 30}

To sum up, an incomplete transverse foramen of atlas vertebra should be paid attention by the surgeons of various disciplines like neurosurgery, orthopaedic surgery before operations in order not to injure some vital structures especially the vertebral arteries.

1. Standring S, (Editor-in-chief). Gray's anatomy: The anatomical basis of clinical practise. 40. edition. 2008. Elsevier Health Sciences. Churchill Livingstone.
2. Taitz C, H Nathan, and B Arensburg, Anatomical observations of the foramina transversaria. *Journal of Neurology, Neurosurgery & Psychiatry*, 1978. 41(2): p. 170-176.
3. Gupta C, et al, A quantitative analysis of atlas vertebrae and its abnormalities. *J Morphol Sci*, 2013. 30(2): p. 77-81.
4. El-Bary THA, M Dujovny, and JI Ausman. Microsurgical anatomy of the atlantal part of the vertebral artery. *Surgical neurology*, 1995. 44(4): p. 392-401.
5. Karau PB and P Odula, Some anatomical and morphometric observations in the transverse foramina of the atlas among Kenyans. *Anatomy Journal of Africa*, 2013. 2(1): p. 61-66.
6. Sengul G and H Kadioglu, Morphometric anatomy of the Atlas and Axis vertebrae. *Turkish neurosurgery*, 2006. 16(2): p. 69-76.
7. Seoane E and AL Rhoton. Compression of the internal jugular vein by the transverse process of the atlas as the cause of cerebellar hemorrhage after supratentorial craniotomy. *Surgical neurology*, 1999. 51(5): p. 500-505.
8. Sultana Q, et al, Variations of foramen transversarium in atlas vertebrae: A morphological study with its clinical significance. *Nitte University Journal of Health Science*, 2015. 5(2).
9. Vasudeva N and R Kumar, Absence of foramen transversarium in the human atlas vertebra: a case report. *Cells Tissues Organs*, 1995. 152(3): p. 230-233.
10. Tubbs RS, et al, Foramen arcuale: anatomical study and review of the literature. *Journal of Neurosurgery: Spine*, 2007. 6(1): p. 31-34.
11. Nayak S, VR Vollala, and D Raghunathan, Total fusion of atlas with occipital bone: a case report. *Neuroanatomy*, 2005. 4: p. 39-40.
12. Sandikçioğlu M, S Skov, and B Solow, Atlas morphology in relation to craniofacial morphology and head posture. *The European Journal of Orthodontics*, 1994. 16(2): p. 96-103.
13. Sheen T-S, et al, Usefulness of the C1 transverse process as a reference guide in the dissection of the upper lateral neck. *Otolaryngology-Head and Neck Surgery*, 2000. 122(2): p. 284-289.
14. Chauhan R, Khanna J, Absence of costal element of the foramen transversarium of atlas vertebrae. *Int J Res Med Sci*. 2013 May;1(2):66-68.
15. Wysocki J, et al, Anatomical variants of the cervical vertebrae and the first thoracic vertebra in man. *Folia Morphologica-Warszawa-English Edition*, 2003. 62(4): p. 357-364.
16. Bailey RW. The cervical spine. 1974: Lea & Febiger.
17. Agrawal D et al, Variations in foramen transversarium: an osteological study in eastern India. *Int J Cur Res*, 2012. 4: p. 120-22.
18. Hadley L, Tortuosity and deflection of the vertebral artery. *The American journal of roentgenology, radium therapy, and nuclear medicine*, 1958. 80(2): p. 306.
19. Hyypää S, E Laasonen, and V. Halonen, Erosion of cervical vertebrae caused by elongated and tortuous vertebral arteries. *Neuroradiology*, 1974. 7(1): p. 49-51.
20. Foramen SOAT, Accessory transverse foramina in the cervical spine: incidence, embryological basis, morphology and surgical importance. *Turkish neurosurgery*, 2011. 21(3): p. 384-387.
21. Buna M, et al, Ponticles of the atlas: a review and clinical perspective. *Journal of Manipulative and Physiological Therapeutics*, 1984. 7(4): p. 261-266.
22. Lamberty B and S Živanovi, The retro-articular vertebral artery ring of the atlas and its significance. *Cells Tissues Organs*, 1973. 85(1): p. 113-122.
23. Mitchell J, The incidence and dimensions of the retroarticular canal of the atlas vertebra. *Cells Tissues Organs*, 1998. 163(2): p. 113-120.
24. Taitz C and H Nathan, Some observations on the posterior and lateral bridge of the atlas. *Cells Tissues Organs*, 1986. 127(3): p. 212-217.
25. Levine A and C Edwards, Treatment of injuries in the C1-C2 complex. *The Orthopedic clinics of North America*, 1986. 17(1): p. 31.
26. Gehweiler Jr JA, et al, Fractures of the atlas vertebra. *Skeletal Radiology*, 1976. 1(2): p. 97-102.
27. Johnson C et al, A biomechanical study of the human vertebral artery with implications for fatal arterial injury. *Forensic science international*, 2000. 109(3): p. 169-182.
28. Krishnamurthy A, et al, Arcuate foramen of atlas: incidence, phylogenetic and clinical significance. *Rom J Morphol Embryol*, 2007. 48(3): p. 263-6.
29. Kavakli A, et al, Variants and deformities of atlas vertebrae in Eastern Anatolian people. *Saudi medical journal*, 2004. 25(3): p. 322-325.
30. Ebraheim NA, et al, The quantitative anatomy of the vertebral artery groove of the atlas and its relation to the posterior atlantoaxial approach. *Spine*, 1998. 23(3): p. 320-323.

REFERENCES

Sakarya Med J
2018;8(2):442-446

BAYLAN et al.
Absence of Costal Element of The Foramen
Transversarium of Atlas Vertebrae: A Case Report