

■ Original Article

Prevention of lung injury by iloprost following hind limb ischemia and reperfusion model in rats

Sıçanlarda alt ekstremite iskemi reperfüzyon hasarını takiben gelişen akciğer hasarının iloprost ile önlenmesi

Atike Tekeli KUNT^{1*}, Selim ISBİR², Ali CIVELEK³, Serdar AKGUN⁴, Arzu ERGEN⁵, Ozlem YAPICIER⁶, Aydin SAV⁷, Sinan ARSAN²

¹Ankara Numune Education and Research Hospital, Department of Cardiovascular Surgery, Ankara/Turkey

²Marmara University Hospital, Department of Cardiovascular Surgery, Istanbul/Turkey

³VM Medicalpark Pendik Hospital, Department of Cardiovascular Surgery, Istanbul/Turkey

⁴Medicana Bahçelievler Hospital, Department of Cardiovascular Surgery, Istanbul/Turkey

⁵Istanbul University Aziz Sancar Experimental Medicine Research Institute, Department of Molecular Medicine, Istanbul/Turkey

⁶Bahcesehir University School of Medicine, Department of Pathology, Istanbul/Turkey

⁷Acibadem University School of Medicine, Department of Pathology, Istanbul/Turkey

ABSTRACT

Aim: The major part of tissue damage occurs upon reperfusion and is mediated by activated neutrophils that release oxygen free radicals. Following hind-limb ischemia/reperfusion, lung injury due to neutrophil infiltration and oxygen free radicals has been demonstrated. Previous studies have shown that this injury can be prevented pharmacologically. Iloprost is a long acting stable analog of prostacyclin. The aim of this study is to test the effect of iloprost in prevention of lung injury due to lower limb ischemia/reperfusion.

Material and Methods: Through a midline laparotomy infrarenal abdominal aorta was approached and cross-clamped in 20 male Sprague-Dawley rats for 2 hours. At the time of declamping Group I animals (n=8) received iloprost (0,1µg/kg/min) and Group II animals (n=8) received normal saline (0,1ml/kg/min) continuously for 4 hours. Third group was the sham group (n=4). The lung tissue assays were performed for measurement of lipid peroxidation end product malondealdehyde and also total glutathione. Lung tissues were also examined histopathologically under light microscopy.

Results: The malondealdehyde levels in the iloprost group were significantly lower than the control group (p<0,05). The glutathione levels did not show any difference between the iloprost and the control groups (p>0,05). Histopathological examination revealed that the structure of the lung tissue was preserved in the iloprost group whereas lung tissue of the control group had evidence of injury.

Conclusion: Our results suggest that iloprost reduces the production of oxygen free radicals and prevents lung injury due to lower limb ischemia reperfusion.

Keywords: ischemia, reperfusion, iloprost

Corresponding Author*: Atike Tekeli Kunt, Ankara Numune Education and Research Hospital, Department of Cardiovascular Surgery, Ankara, Turkey.

E-Mail: atikemd@gmail.com

Received 19.02.2018 accepted 27.05.2018

Doi: 10.18663/tjcl.396679

ÖZ

Amaç: İskemi ve bunu takip eden reperfüzyon dönemi sonrasında ortaya çıkan doku hasarı büyük ölçüde reperfüzyon sırasında gerçekleşir. Aktive olmuş nötrofillerden salınan serbest oksijen radikalleri bu hasarda önemli rol oynarlar. Alt ekstremitte iskemi-reperfüzyonu sonrasında görülen akciğer hasarında nötrofil infiltrasyonunun ve serbest oksijen radikallerinin önemi gösterilmiştir. Bu hasarı farmakolojik olarak önlemek için birçok çalışma yapılmıştır. İloprost, uzun etkili bir prostasiklin analogudur. Çalışmanın amacı, alt ekstremitte iskemi reperfüzyonu sonrası ortaya çıkan akciğer hasarını önlemedeki iloprostun etkisini araştırmaktır.

Gereç ve Yöntemler: Çalışmada 20 adet Spraque-Dawley cinsi erkek sıçan kullanıldı. Orta hattan yapılan laparotomi ile abdominal aortaya ulaşıldı. Grup I (n=8) ve Grup II (n=8) de bulunan deneklerin infrarenal aortalarına 2 saat boyunca kross klemp uygulandı. Klemp kaldırıldığı sırada Grup I'de bulunan deneklere 0,1 g/kg/dk dozunda iloprost ve Grup II'de bulunan deneklere 0,1ml/kg/dk serum fizyolojik sürekli infüzyon şeklinde 4 saat boyunca verildi. Grup III(n=4) sham grubu olarak belirlendi. Denekler 4. saatin sonunda kurban edilerek akciğer dokuları çıkarıldı ve biyokimyasal ve histopatolojik inceleme yapıldı.

Bulgular: İloprost verilen grupta malonaldehide seviyeleri kontrol grubuna göre istatistiksel olarak anlamlı derecede düşük bulundu ($p<0.05$). Glutasyon düzeylerinde ise kontrol ve iloprost grupları arasında anlamlı fark bulunmadı ($p>0.05$). Histopatolojik incelemede, iloprost verilen grupta akciğer dokusunun korunmuş olduğu gözlenirken kontrol grubunda akciğer doku harabiyeti tespit edilmiştir.

Sonuç: Sonuçlarımız alt ekstremitte iskemi-reperfüzyonu sonrasında ortaya çıkan akciğer hasarının önlenmesinde iloprostun serbest oksijen radikal oluşumunu azaltarak etkili olduğunu göstermektedir.

Anahtar kelimeler: iskemi, reperfüzyon, iloprost

Introduction

Ischemia/ reperfusion (I/R) injury is still a major problem for cardiovascular surgeons dealing especially with aortic surgery. The main damage occurs during reperfusion period that is reperfusion initiates both local and systemic damage through inflammatory mediators and reactive oxygen substances mainly released from polymorphonuclear leukocytes [1,2]. These products that are released during reperfusion may lead to severe complications and even death due to systemic inflammatory response syndrome and multiorgan failure [3]. Remote organ damage after I/R is also a dreadful problem and mainly the lungs, heart, liver and kidneys are the affected organs [4]. The main mechanism of lung injury following lower extremity I/R is unknown however many mechanisms are suggested to explain this condition. Some of these mechanisms are; activation of proinflammatory cytokines (IL-8, IL-6, TNF), platelet activating factor (PAF), leukotriens, eicosanoids, locally released proteases from neutrophils, chemoattraction of neutrophils and release of oxygen radicals [5-9]. These substances are suggested to result in endothelial damage of lung capillary arteries and cause increased microvascular permeability [10,11].

It is well known that the main factors in the development of I/R injury are increased levels of free oxygen radicals and neutrophil infiltration, thus, many invivo and invitro studies are performed

to attenuate I/R through methods inhibiting or preventing neutrophil infiltration or free radicals. Leukopenia, monoclonal antibodies against leucocyte adhesion molecules such as CD11/CD18, cytokines, platelet activating factor antagonists, free radical scavengers, nitric oxide donors and prostoglandin analogues are the agents used to prevent I/R injury [5-8, 12].

Iloprost is a synthetic analogue of prostacyclin (PGI₂). It is synthesized primarily by endothelial cells and has vasodilatory, immunomodulatory and antithrombotic actions. It reduces the levels of circulatory tumor necrosis factor- α , Interleukin-1 and Interleukin-6 [5]. Iloprost is therefore a widely used drug especially in patients with peripheral arterial disease [6].

This study was planned to analyze the effect of Iloprost pretreatment on the prevention of lung injury induced by abdominal aorta I/R.

Material and Methods

This study was approved by the Institution of Animal Care Use Committee at Marmara University, Istanbul, Turkey and complied with the Guide for the Care and Use of Laboratory Animals. Twenty Sprague-Dawley rats weighing 300-350g were randomized into 3 groups. The animals were initially anesthetized with intraperitoneal ketamine hydrochloride (Ketalar; Pfizer, Ortakoy, Istanbul, Turkey) 100mg/kg bodyweight. The abdomen was then explored through a midline incision after shaving and disinfection. In the sham group, only laparotomy was performed.

In the control and the study groups, I/R was induced by clamping the aorta with atraumatic vascular clamp infrarenally for 2 hours, followed by 4 hours of reperfusion. Cessation of arterial flow was confirmed by means of the absence of an audible continuous-wave Doppler signal. Control group animals received saline solution intravenously at a dose of 0.1ml/kg/min through inferior vena cava catheterization and study group animals received Iloprost at a dose of 0.1ml/kg/min intravenously during reperfusion. At the end of these procedures, the animals were sacrificed with lethal injection of sodium thiopental (Penthotal sodium, Abbot, Italy). Immediately after sacrifice, through midline sternotomy, the lungs of the animals were extracted and washed with 0.9% saline solution for both histopathological and biochemical analysis.

Histopathological examination:

Tissue samples were fixed in 10% formalin and embedded in paraffin with routine follow-up procedure; 4-5µm sections were cut from paraffin blocks and stained with hematoxylin and eosin (H&E) for light microscope examination (X200, Olympus BH-2, Olympus Optical CO, Ltd, Tokyo, Japan). All samples were evaluated by the same histopathologist, blinded to the study for edema, alveolar structural disturbance and infiltration by inflammatory cells. (Table 1).

Table 1. Histopathological scoring system.

Grade	Description
0	Normal histologic appearance
1	Vascular congestion
2	Vascular congestion and interstitial edema
3	Alveolar structural disturbance and infiltration of inflammatory cells
4	Massive alveolar structural disturbance and infiltration of inflammatory cells

Biochemical analysis:

Lung tissues were frozen immediately in liquid nitrogen and stored at -80°C until measurements were started. Twenty-micron-thick sections were prepared and dried under vacuum overnight (at 20°C). Freeze-dried sections were stored at -20°C until biochemical assays were performed. Determination of malondealdehyde (MDA) and total Glutathione (GSH) levels were performed by enzyme-linked immunosorbant assay (ELISA). MDA concentration was expressed as nmol/gr tissue and concentrations of total GSH were expressed as µmol/gr protein.

Statistical analysis:

Statistical analysis were performed using Statistical Package for the Social Sciences 10.0. (SPSS, Chicago IL, USA) Values were

expressed as mean±SD. One- way ANOVA, Kruskal Wallis and Dunn’s multiple comparison tests were used for tissue MDA and total GSH measurements and histopathological scores. Statistical significance was set up at p-values of less than 0.05.

Results

Histopathological results:

The sham group exhibited normal lung architecture and arrangement. The histological structure of alveoli and interstitial tissue were intact without any infiltration of inflammatory cells (Figure 1). In the control group, the alveolar structure was completely destroyed with thickened and fused alveolar septa. The alveoli showed severe interstitial edema, intraalveolar fibrin deposits, prominent leukocyte infiltration and intraalveolar hemorrhage that indicated a high degree of lung injury as outlined in Table 2 (Figure 2). Light microscopic examination of the study group that received Iloprost at a dose of 0.1ml/kg/min intravenously during reperfusion demonstrated a less intraalveolar hemorrhage, less edema and inflammation revealing a decreasing pathological score (Table2, Figures 3).

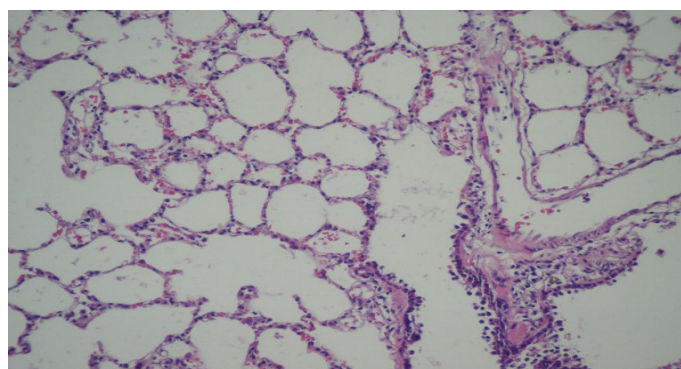


Figure 1. Light microscopic photomicrograph of the sham group with normal lung tissue (H&E, x200).

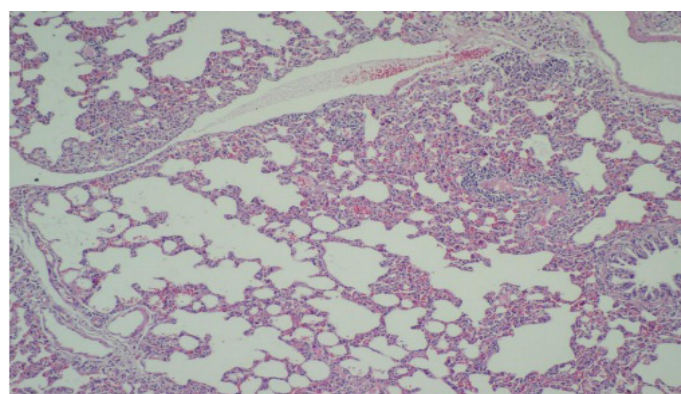


Figure 2. Light microscopic photomicrograph of control rat lung tissue showing destroyed alveolar architecture with massive infiltration of inflammatory cells (H&E, x100).

Table 2. Results of histopathological examination.

Groups	n	Histopathological grades				
		0	1	2	3	4
Iloprost Group	8	3	3	1	1	0
Control Group	8	0	0	0	2	6
Sham Group	4	3	1	0	0	0

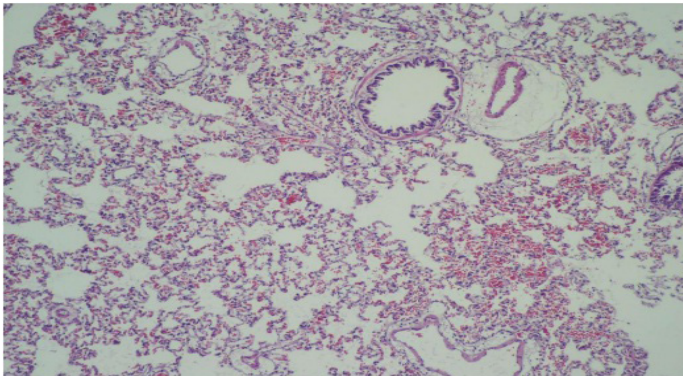


Figure 3. Light microscopic photomicrograph of lung tissue from Iloprost group showing nearly normal alveolar architecture, with slight less leukocytic infiltration (H&E, x100).

Biochemical results:

The mean MDA levels in the study group were similar to those in the sham group (0.273 ± 0.048 nmol/gr tissue and 0.287 ± 0.058 nmol/gr tissue respectively ($p > 0.05$)). However, the MDA levels were significantly higher in the control group than the study and sham groups (0.968 ± 0.177 nmol/gr tissue, $p < 0.05$) (Figure 6). The mean total GSH level in the study group was 44.846 ± 3.010 μ mol/gr protein, in sham group; 43.855 ± 2.186 μ mol/gr protein and in the control group; 46.546 ± 2.231 μ mol/gr protein with no statistically significant differences ($p > 0.05$).

Discussion

The present study demonstrated that Iloprost at a dose of 0.1ml/kg/min administered intravenously during reperfusion attenuates lung injury that occurred after bilateral lower extremity I/R in a rat model.

Ischemia-reperfusion injury involves a sequence of events leading to cellular damage [13]. The main problem in I/R injury is the oxygen free radicals that are released during reperfusion period [14]. It is well known that the main sources of these oxygen radicals are the activated neutrophils. Activated neutrophils lead to endothelial cell damage in lungs and free radicals are released [15]. Pulmonary vasoconstriction, hypertension, and increased pulmonary vascular permeability are common results of impaired endothelial cell function [7]. Our results showed that Iloprost administered animals had less intraalveolar

hemorrhage, less edema and inflammation compared to the control group revealing a decreasing pathological score. We used MDA, an end product of lipid peroxidation, to analyse the severity of lipid peroxidation in this present study. The lower levels of MDA in the study and sham groups compared with the control group correlate well with the pathological findings that are decreased neutrophilic infiltration and less percentage of alveolar structural damage. Quantitatively both histopathological and biochemical results revealed a significant difference between control and study groups.

In the present study we also analysed the levels of total GSH. It is known that GSH acts as a protective system against oxidative stress. We found no statistically significant difference regarding the total GSH levels between the control and study groups. This result may suggest that Iloprost shows its intracellular protective effect different from the GSH system.

Much recent attention has been focused on the protective effects of Iloprost in I/R. Although there are many studies in the literature that showed its protective effects in I/R injury in different organs, the precise mechanism of action is not completely understood [16-17]. Iloprost is an analogue of Prostaglandin I₂ and has vasodilator, antiaggregant and cytoprotective effects. It inhibits thrombocyte aggregation and destructs leukocyte and endothelial communication. It also decreases the synthesis of adhesion molecules and collectively it increases microcirculation and by this increased tissue perfusion it results in an endothelial- protective effect [18]. Thus its cite of intracellular protection action may be through this pathway other than GSH system.

Conclusion

Our results suggest that Iloprost ameliorates the lung injury associated with I/R of the lower extremity. Iloprost also exerts an inhibitory effect on the neutrophils that cause remote organ damage. Its clinical effects in this manner should be warranted by randomized clinical studies.

Declaration of conflict of interest

The authors received no financial support for the research and/or authorship of this article. There is no conflict of interest.

References

1. Klausner JM, Paterson IS, Valeri R, Hechtman HB. Limb ischemia induced increase in permeability is mediated by leukocytes and leukotrienes. *Ann Surg* 1988; 208: 755-60.
2. Klausner JM, Paterson IS, Kozbik L, Valeri R, Shepro D, Hetchtman HB. Oxygen free radicals mediate ischemia-induced lung injury. *Surgery* 1989; 105: 192-99.



3. Gyurkovics E, Aranyi P, Stagnol R et al. Postconditioning of the lower limb protection against reperfusion syndrome. *J Surg Res* 2011; 169: 139-47.
4. Akgun S, Tekeli A, Isbir SC et al. FK506 to prevent lung injury after hindlimb ischemia and reperfusion in a rat model: an electron microscopic study. *Surg Today* 2004; 34: 678-84.
5. Groeneveld AB, Raijmakers PG, Rauwerda JA, Hack CE. The inflammatory response to vascular surgery associated ischemia and reperfusion in man: effect of postoperative pulmonary function. *Eur J Endovasc Surg* 1997; 14: 351-59.
6. Gaines GC, Welborn MB, Moldawer LL, Huber TS, Harward TR, Seeger JM. Attenuation of skeletal muscle ischemia-reperfusion by tumor necrosis factor. *J Vasc Surg* 1999; 29: 370-76.
7. Bengisun U, Köksoy C, Bengisun JS, Bayraktaroglu G, Camur A, Aras N. Ischemia and reperfusion of pulmonary hypertension and leukosequestration following lower limb ischemia. *Prost Leuko Essen Fatty Acids* 1997; 56: 117-20.
8. Isbir CS, Akgün S, Ak K et al. Akut alt ekstremite iskemi/reperfüzyon hasarının akciğer serbest oksijen radikalleri üzerine olan etkisi. *TGKDCCD* 2000; 8: 629-31.
9. Rocker MG. Ischemia/reperfusion, inflammatory responses and acute lung injury. *Thorax* 1997; 52: 841-42.
10. Raijmakers PGHM, Groeneveld ABJ, Rauwerda JA, Teule GJJ, Hack CE. Acute lung injury after aortic surgery: the relation between lung and leg microvascular permeability to indium-labelled transferrin and circulating mediators. *Thorax* 1997; 52: 866-71.
11. Grant SM, Goa KL. Iloprost. A review of its pharmacodynamic and pharmacokinetic properties, and therapeutic potential in peripheral vascular disease, myocardial ischaemia and extracorporeal circulation procedures. *Drugs* 1992; 43: 889-924.
12. Wang L, Jin YZ, Zhao QH et al. Hemodynamic and gas exchange effects of inhaled iloprost in patients with COPD and pulmonary hypertension. *Int J Chron Obstruct Pulmon Dis*. 2017; 12: 3353-60.
13. Pantazi E, Bejaoui M, Folch-Puy E, Adam R, Roselló-Catafau J. Advances in treatment strategies for ischemia reperfusion injury. *Expert Opin Pharmacother*. 2016; 17: 169-79.
14. Bhattacharyya, A., Chattopadhyay, R., Mitra, S., Crowe, S.E., Oxidative stress: an essential factor in the pathogenesis of gastrointestinal mucosal diseases. *Physiol. Rev.* 2014; 94: 329-54.
15. Messent M, Griffiths MJD, Evans TW. Pulmonary vascular reactivity and ischemia reperfusion injury in the rat. *Clin Sci* 1993; 85: 71-75.
16. M. Sacar, V. Ozcan, H. Aybek et al., Vitamin C and iloprost attenuate skeletal muscle injury caused by ischemia-reperfusion of the lower extremities. *TGKDCCD* 2005; 13: 374-8.
17. Aytacoglu BN, Sucu N, Tamer L et al., Iloprost for the attenuation of ischaemia/reperfusion injury in a distant organ. *Cell Biochem Func* 2006; 24: 341-46.
18. Tiryakioglu O, Erkoc K, Tunerir B, Uysal O, Altin HF, Gunes T, Aydin S. The effect of iloprost and N-acetylcysteine on skeletal muscle injury in an acute aortic ischemia-reperfusion model: an experimental study. *Biomed Res Int*. 2015; 2015: 453748.