



## ARAŞTIRMA / RESEARCH

# Correlation between decompression period and initial volume of large cystic lesions of the mandible: a retrospective CBCT study

Mandibuladaki geniş kistik lezyonların hacmi ile dekompresyon süreleri arasındaki korelasyon: retrospektif KIBT çalışması

Murat Ulu<sup>1</sup>, Seyfi Kelebek<sup>1</sup>, Fahrettin Kalabalık<sup>1</sup>, Hüseyin Akçay<sup>1</sup>

<sup>1</sup>İzmir Katip Çelebi Üniversitesi, Diş Hekimliği Fakültesi, Klinik Bilimler Bölümü, İzmir, Turkey

*Cukurova Medical Journal 2018;43(Suppl 1):254-261*

### Abstract

**Purpose:** The aim of this retrospective study was to evaluate the outcomes of the decompression of large cystic lesions of the mandible and to analyze the correlation between decompression period and the cone-beam computed tomography (CBCT) volume of initial lesions.

**Materials and Methods:** The retrospective study included 13 patients who underwent decompression due to single cystic lesions. All the cystic lesions were localized in the mandible, between the anterior region and the ramus region. All the lesions recovered completely via decompression alone. Volume of the lesions was measured with CBCT and decompression was conducted with a customized acrylic resin stent inserted in the cystic cavity. Decompression period and initial CBCT volume were compared.

**Results:** Mean age of the patients was 39.85 years, mean decompression periods was 12.38 months, mean follow-up period was 20.15 months, and mean initial CBCT volume was 7076.81 mm<sup>3</sup>. A positive correlation was found between the volume of the cystic lesions and the decompression period.

**Conclusion:** Decompression can provide useful outcomes in the treatment of large cystic lesions in compatible cases since it provides numerous advantages such as noninvasive surgery, low risk of morbidity and severe complications such as bone fracture and inferior alveolar nerve injury. However, in aggressive cystic lesions such as odontogenic keratocyst and ameloblastoma, subsequent definitive surgery following decompression is recommended.

**Key words:** Decompression, odontogenic cystic lesion, cone beam computed tomography, acrylic stent, marsupialization

### Öz

**Amaç:** Bu çalışmada mandibuladaki geniş kistik lezyonların dekompresyon sonuçlarının retrospektif olarak değerlendirilmesi, dekompresyon süreleri ile lezyonların konik ışınli bilgisayarlı tomografi (KIBT) ile ölçülen başlangıç hacimleri arasındaki korelasyonun analiz edilmesi amaçlanmıştır.

**Gereç ve Yöntem:** Bu retrospektif çalışma tek bir geniş kistik lezyon nedeniyle dekompresyon tedavisi uygulanan 13 hastadan oluşmaktadır. Tüm kistik lezyonlar anterior ile ramus mandibula arasında yer almaktadır. Tüm kistik lezyonlar sadece dekompresyon yöntemi ile tamamen iyileşmiştir. Lezyonların hacimleri KIBT ile ölçüldü. Dekompresyon, kişiye özel akrilikten imal edilen stentlerin kistik kaviteye yerleştirilmesi ile gerçekleştirildi. Dekompresyon periyodu ile başlangıç KIBT hacimleri karşılaştırıldı.

**Bulgular:** Ortalama yaş 39.85 yıl, ortalama dekompresyon süresi 12.38 ay, ortalama takip süresi 20.15 ay ve ortalama başlangıç KIBT hacmi 7076.81 mm<sup>3</sup> idi. Kistik lezyon hacmi ile dekompresyon periyodu arasında pozitif korelasyon olduğu bulundu.

**Sonuç:** Dekompresyon yöntemi uyumlu hastalarda geniş kistik lezyonların tedavisinde faydalı sonuçlar sağlayabilir, non-invaziv cerrahi, kemik kırığı ve inferior alveolar sinir yaralanması gibi ciddi komplikasyon ve morbidite risklerinin azaltılması gibi çok sayıda avantaj sağlar. Ancak odontojenik keratokist ve ameloblastoma gibi agresif kistik lezyonlarda dekompresyonu takiben cerrahi tavsiye edilmektedir.

**Anahtar kelimeler:** Dekompresyon, odontojenik kistik lezyon, konik ışınli bilgisayarlı tomografi, akrilik stent, marsupiyalizasyon

## INTRODUCTION

A cystic lesion is a pathologic cavity that involves fluid or a semisolid material and is predominantly lined by epithelium<sup>1,2</sup>. Odontogenic cysts originate from epithelial cells of the dental follicle or from the rests of odontogenic epithelium<sup>3</sup>. Odontogenic cysts are mostly treated by enucleation, curettage, resection and marsupialization. Moreover, decompression and marsupialization are well-accepted techniques for the treatment of large odontogenic cysts and tumors such as radicular cysts (RC), dentigerous cysts (DC), odontogenic keratocyst (OKC) and ameloblastomas (AB)<sup>2,4,5</sup>. The decompression of odontogenic cystic lesions has been widely accepted as a more conservative treatment which requires a much smaller window by creating an opening into the cystic cavity and by suturing a device (tube, drain or stent) to its periphery<sup>6-8</sup>. Moreover, decompression can release the intramural pressure, favor the formation of new bone tissue from the periphery, and also develop fewer complications than enucleation, curettage, and resection. However, patients treated with decompression require more frequent follow-up<sup>9-11</sup>.

Many practitioners prefer decompression for large cysts to avoid the risk of inferior alveolar nerve (IAN) injury, maxillary sinus and nasal cavity injuries, and pathologic bone fractures and also to preserve pulp vitality. In addition, decompression has been shown to provide several advantages including spontaneous tooth eruption, avoidance of the need for bone grafting for large defects due to bony filling of the residual cavity, and lower morbidity following final surgery as a result of shrinking away from vital structures<sup>10,12</sup>.

The aim of this retrospective study was to evaluate the outcomes of the decompression of large cystic lesions of the mandible after long-term follow-up periods and to analyze the correlation between decompression period and the CBCT volume of initial lesions.

## MATERIALS AND METHODS

### Study design and patients

The retrospective study included 13 patients who underwent decompression for the treatment of large odontogenic cysts or cyst-like tumors of the mandible at Izmir Katip Celebi University

Department of Oral and Maxillofacial Surgery between 2013 and 2016. An informed consent was obtained from each patient before surgery. Decompression was performed via intraoral approach in all patients. The 13 patients included 6 (46.2%) males and 7 (53.8%) females with an age range of 15-54 years. Patients that recovered completely and required no secondary surgery except for simple curettage were included in the study. None of the patients had systemic diseases or conditions that affected bone metabolism and none of them was using medications that could have interfered with bone turnover.

Each patient had only one single cystic lesion. All the thirteen cystic lesions were localized in the mandible, between the anterior region and the ramus region. All the patients recovered completely via decompression alone and were followed-up for more than 12 months over the period between 2013 and 2016. Five patients (1 male and 4 females) had OKC localized in the mandibular molar, angle, and ramus region, 7 (4 males and 3 female) patients had RCs localized in the mandibular anterior and molar regions, 1 male patient had a DC localized in the mandibular molar and angle region (Table 1).

Initial diagnosis was established based on the clinical and panoramic radiographic evaluations (Figure 1). Lesion size, adjacency of the lesion with the inferior alveolar nerve and teeth, structural integrity of the cystic area (bone perforations, bone thickness), and the localization of unerupted teeth were evaluated by CBCT prior to the initial decompression surgery (Figure 2).

### Decompression technique

The decompression procedure was initiated by creating an opening on the most expanded region of the cystic lesion, followed by an incisional biopsy under local anesthesia for histopathological evaluation. The opening was maintained by introducing a short customized acrylic resin stent into the cystic cavity from the peripheral opening of the window and stainless steel wire clasps were used to undercut the periphery of the adjacent dental crowns (Figure 3). The shape of the stent was adjusted after each follow-up in order to allow bone formation within the cystic cavity. Each patient was instructed on how to rinse the cavity with copious amounts of chlorhexidine gluconate 0.1 % after every food intake. Each patient was examined every

three months and panoramic radiography was performed to follow the course of the treatment and to evaluate the amount of shrinkage. The treatment

was terminated when the cystic lesions were undetectable on the radiographs and the bone filling of the cavities reached the ridge level (Figure 1).

**Table 1. General data about patients and lesion types**

#	Age/ Gender	Location	Radiographic character	Decompression duration (month)	Initial CBCT volume (mm <sup>3</sup> )	Type Cystic Lesion	Follow-up period (month)
1	35/ M	Mandible, Ang-Ram	Multi.	7 M	3799.28	OKC	19 M
2	44/ F	Mandible, Ang-Ram	Uni.	8 M	4242.90	OKC	14 M
3	15/ F	Mandible, Ang-Ram	Uni.	6 M	4881.34	OKC	13 M
4	39/ M	Mandible, Ant-Mol	Uni.	13 M	6873.03	RC	17 M
5	43/ F	Mandible, Symphysis- Mol	Multi.	15 M	8510.03	RC	21 M
6	45/ F	Mandible, Mol-Ang- Ram	Multi.	13 M	8312.13	OKC	33 M
7	28/ M	Mandible, Symphysis	Uni.	14 M	8121.56	RC	22 M
8	50/ M	Mandible, Mol-Ang	Multi.	18 M	12471.29	DC	25 M
9	38/ F	Mandible, Mol-Ang- Ram	Multi.	16 M	9042.25	RC	21 M
10	42/ F	Mandible Mol-Ang- Ram	Uni	14 M	7043.45	OKC	19 M
11	49/ M	Mandible Mol-Ang	Multi	14 M	6605.67	RC	18 M
12	54/ M	Mandible Ang-Ram	Uni	11 M	6058.85	RC	21 M
13	36/ F	Mandible Ang-Ram	Uni	12 M	6036.75	RC	19 M

RC: radicular cysts; DC: dentigerous cysts; OKC: odontogenic keratocyst

**Table 2. Vitality of teeth in relation to lesions**

Patients	Related impacted teeth (tooth number)	Adjacent teeth number/ vitality
1	No	37/ vital
2	Yes (38)	37/ vital
3	Yes (38)	37/ vital
4	No	43,32/ devital, 41,42,31,33 /vital
5	No	33, 34, 35, 36, 37/ vital
6	No	37/ vital
7	No	43, 44, 45/vital, 42, 41, 31,32,33/ devital
8	Yes (48)	45, 46, 47 / vital
9	Yes (48)	47/vital
10	No	34,35,36 /vital 37/devital
11	No	44,45/vital 46,47/devital
12	No	47/vital
13	Yes(38)	37/vital

**Table 3. Relationship between initial volume of cystic cavity and decompression period**

		Decompression	CBCT
Decompression	Pearson Correlation	1	.903**
	Sig. (2-tailed)		.000
	N	13	13
CBCT	Pearson Correlation	.903**	1
	Sig. (2-tailed)	.000	13
	N	13	

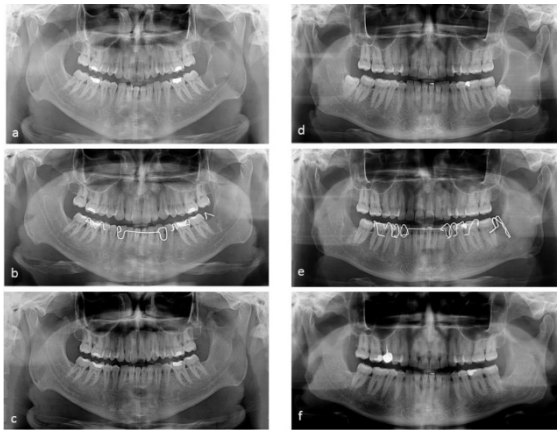
A strong relationship was found between decompression period and initial volume of cystic cavity ( $r=0.903$ ;  $p<0.001$ ). Two variables increase and decrease together.

**Initial CBCT measurement**

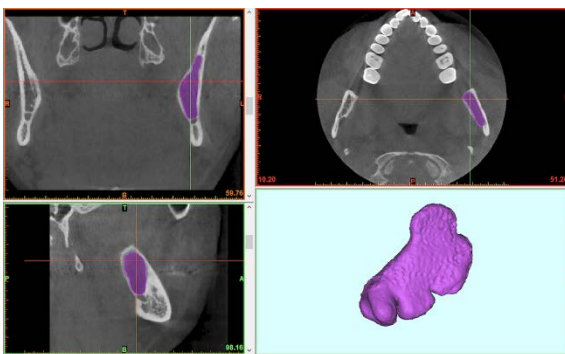
All the CBCT images were obtained by using a NewTom 5G (QR Verona, Verona, Italy) CBCT

device operating at 60–110 kVp, 1–20 mA, 0.2 mm slice thickness and 0.2 mm voxel size. The CBCT images were exported in the Digital Imaging and Communications in Medicine (DICOM) format and

imported in Mimics software version 16.0 (Materialize Medical, Leuven, Belgium). In a secluded room with dim light, volumetric measurement was performed by an oral radiologist experienced in Mimics software. The threshold was defined manually to include the whole lesion and to remove any artifact and background. Editing masks and segmentations of the lesions were performed manually. After the editing of the masks, volumetric measurement of the lesions was performed by the software. All the measurements were performed by the same radiologist to prevent inter-observer variability.



**Figure 1.** a&d: Initial panoramic view of the patients, b&e: follow-up view of the patients with marsupialization acrylic stent, c&f: final view of the decompression period. The cystic cavities were filled with bone at the end of decompression.



**Figure 2.** CBCT image and volumetric measurement of the initial volume of the cystic cavity

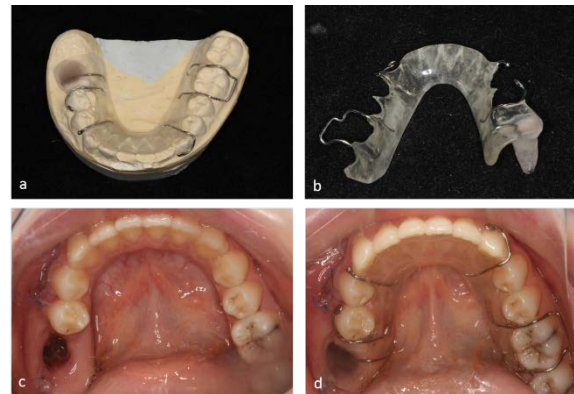
### Statistical analysis

Normality of the data was assessed using Shapiro-Wilk test with Q-Q graphics. The relationship

between decompression period and initial volume of cystic cavity was analyzed by Pearson Correlation Analysis. A  $p$  value of  $<0.05$  was considered significant.

### RESULTS

Decompression led to complete recovery in all the patients. Table 1 presents the descriptives of the patients. All the cystic lesions were localized in the mandible, between the anterior region and the ramus region. The lesions comprised 5 OKC, 7 RC and 1 DC. All the patients were followed up regularly every three months, with a mean follow-up of 20.15 (range, 13-33) months.



**Figure 3.** Customized acrylic resin stent with a wire was prepared and inserted in the cystic cavity.

Five patients were present with impacted third molars associated with cystic lesions, all of which were extracted after decompression. Moreover, the pulp vitality of the adjacent teeth was mostly positive, particularly in the cystic lesions localized in the posterior region. All the teeth were vital in 9 patients, whereas 4 patients had both vital and nonvital teeth (Table 2). Mean decompression period was 12.38 (range, 6-18) months and mean initial CBCT volume was 7076.81 (range, 3799.28-12471.29)  $\text{mm}^3$  (Table 1).

The statistics revealed that as the initial CBCT volume of the cystic lesions increased, the decompression period increased. Moreover, a significant correlation was found between the initial CBCT volume and the decompression period in all the patients except for patient #3, which was due to rapid bone formation. Relationship between initial volume of cystic cavity and decompression period was presented in Table 3.

## DISCUSSION

Although several treatment options have been defined for large mandibular cystic lesions in the literature, there is still no consensus on a standard treatment modality<sup>13</sup>. All the treatment methods defined in the literature aim to remove the lesions as completely as possible to avoid complications. Large cystic and cyst-like lesions can be treated with decompression alone, marsupialization, enucleation, resection, and a combination of any of these techniques<sup>14,15</sup>. Odontogenic cystic lesions are generally treated by decompression or marsupialization alone. However, aggressive lesions such as OKC and AB can infiltrate diffusely into bone and bone remnants, thereby causing relapse of the disease<sup>6,13,16</sup>. These aggressive lesions usually require extensive surgeries such as enucleation and resection for the prevention of relapse<sup>16</sup>. Moreover, these surgeries include either lavage of the lumen with Carnoy solution before or after removal and curettage of the bony wall, or radical resection<sup>17</sup>. However, these methods might be radical and harmful since they may induce damage to adjacent vital structures such as IAN and maxillary sinus and may also cause spontaneous bone fracture and difficulty of prosthetic rehabilitation. In our study, seven cases of RC, five cases of OKC and one case of DC were successfully treated with decompression and no recurrence was observed.

Decompression is a conservative and noninvasive method which can be easily tolerated by the patients<sup>18</sup>. In this technique, first, the more expanded region of the lesion is detected. Then an opening is created in the periphery of the cystic lesion and a biopsy specimen is obtained under local anesthesia for histopathologic examination. On the other hand, several devices and techniques have been identified to sustain this opening after decompression, including nasopharyngeal tube, customized acrylic stent, and drain or iodoform gauze impregnated with bacitracin ointment<sup>11,19,20</sup>.

The iodoform gauze provides favorable outcomes since it maintains the cavity filled and also blocks food debris from being trapped inside. The amount of iodoform gauze can be decreased gradually to allow more controlled reduction of the cystic cavity. However, the gauze requires frequent changes (every 7-10 days) to prevent a filthy smell and possible infection in the depth of the lesion. Inserting tube or drain into the opening of the wall

of the lesion could be easier to keep the cystic cavity from further expansion and the bony defect is left unfilled to leave room for spontaneous regeneration of bone to occur<sup>21</sup>. The tube and the drain do not require changing at regular intervals and eliminate the necessity for frequent visits to clinics. However, both of these methods require suturing to the surrounding mucosal window and thus might move into the cavity and require repetitive interventions. Furthermore, these methods can also cause bad smells that disturb the patient and may result in infection due to the difficulty of cleaning. On the other hand, the customized acrylic stent with wire claps can be easily removed and the care of the stent and the irrigation of the cystic cavity provide long-term satisfactory outcomes<sup>19,20</sup>. Moreover, the long part of the stent fits into the cystic cavity and thus can easily be shortened when spontaneous bone filling occurs in the periphery of the lesion. In our study, all the patients tolerated the acrylic stent easily and had no problems or infections.

Decompression has several disadvantages that arise from biopsy sampling and patient cooperation. During the biopsy sampling, only a small superficial section of the lesion is sampled and thus the deeper parts of the lesion cannot be explored completely. As a result, the initial diagnosis that is made at the beginning of the decompression procedure might be affected or even change after this period. Schlieve et al. reported that the post-decompression histopathologic examination at the time of definitive surgical procedure was consistent with the preoperative biopsy diagnosis in 91% (10 out of 11) of OKC, 67% (2 out of 3) of glandular odontogenic cysts, 75% (3 out of 4) of DCs, and 100% (7 out of 7) of cystic ABs<sup>22</sup>. Throughout the entire decompression procedure, patient compatibility is required to achieve regular irrigation of the cavity and to prevent the accumulation of food debris into the cavity. However, the procedure can be terminated, the acrylic stent can be removed, and the cyst can be enucleated at any time during the procedure if the patient is not willing to proceed. Despite all these factors, decompression of large cystic lesions can avoid the risk of inferior alveolar nerve (IAN) injury, maxillary sinus and nasal cavity injuries, pathologic bone fractures, and infection and also can preserve pulp vitality by decreasing the lesion size. On the other hand, decompression has been shown to provide several advantages including spontaneous tooth eruption, avoidance of the need for bone grafting for large defects due to bony

filling of the residual cavity, and lower morbidity following final surgery as a result of shrinking away from vital structures<sup>10,12</sup>. In our patients, no complications occurred during the treatment procedure and the advantages of decompression were clearly observed.

Literature indicates that there is no consensus on an ideal decompression period, which has been reported to range between 2 and 80 months<sup>2,11</sup>. Marker et al. reported that the mean decompression period was 12 months in the patients with OKC and the cysts were reduced by  $\geq 50\%$ -60% before enucleation<sup>12</sup>. Brøndum and Jensen reported a mean decompression period of 10 (range, 1-14) months in 44 patients with OKC<sup>10</sup>. Pogrel reported a mean reduction of 65% (range, 5-91%) with a mean decompression period of 8.4 (range, 6-12) months and Enislidis et al. reported a mean reduction of 81% with a mean decompression period of 17.5 months<sup>19,23</sup>. Anavi et al. reported that the lesions were reduced by 79.3% after decompression and the mean decompression period was 9.2 months. The authors also suggested that if the primary treatment of large mandibular lesions is decompression alone, the decompression period should be prolonged to up to 22 months<sup>2</sup>. Lizio et al. reported a mean reduction rate of 49.86% with a mean decompression period of 5.7 months<sup>24</sup>. Asutay et al. reported a mean reduction rate of 48.28% (46.72% for OKC, 54.13% for DC and 44.50% for AB) over a period of 6 months<sup>24</sup>. In our study, decompression period ranged between 6 and 18 months with a mean decompression period of 12.38 months. The decompression period of a 16-year-old patient was 6 months, which was significantly lower than the mean decompression period reported for adults in the literature. This may be explained by the higher osteogenic activity in young patients. On the other hand, there is a controversy about the effect of patient age on the percentage of the reduction of the lesion. Although some researchers found no correlation between age and the rate or speed of shrinkage<sup>14,25,26</sup>, some others suggested that there is a correlation between age and the rate of the shrinkage<sup>2,18,27</sup>.

Two-dimensional radiographs such as orthopantomogram and posterior-anterior and lateral radiographs are used in routine clinical practice and are useful for the initial examination of cystic lesions<sup>11,19,28</sup>. However, these techniques cannot be utilized to measure the volume of the

whole cystic lesion and to define the borders of the cystic lesion and the adjacent vital structures. In addition, 2-dimensional radiographs are not reliable for the planning of the treatment of large lesions. However, CBCT can define precise and reliable borders as well as the volumetric dimensions of the lesions and can also visualize tooth displacement and the relations among the cystic cavity, vital organs, and the anatomic structures<sup>14,24,29</sup>. The accurate volume of the lesions can be measured by using special software, the measurements of which are reproducible, reliable and lead to lower postoperative complications after high-risk surgical treatments<sup>14,29</sup>.

Our study was limited in several ways. First, no additional CBCT images were obtained after the decompression period for evaluating the precise volumetric change of the lesions. Second, the effect of patient age on the rate of reduction of the lesion was not evaluated due to the small sample size and the absence of an equal age distribution.

In conclusion, decompression is a useful technique for large cystic lesions in compatible cases since it provides numerous advantages such as noninvasive surgery and low risk of morbidity and severe complications such as bone fracture and IAN injury. Moreover, decompression serves as a primary treatment for large cystic lesions, leading to a high rate of reduction in the cystic cavity and providing immediate information about the type of the cyst. However, in aggressive cystic lesions such as OKC and AB, subsequent definitive surgery following decompression is recommended.

## REFERENCES

1. Ghanem A, Gad H. The influences of the patient's age, size and type of the primary lesions on the rate of shrinkage after marsupialization of odontogenic cysts. *Egyptian Dental Journal*. 2015;61:5241-49.
2. Anavi Y, Gal G, Miron H, Calderon S, Allon DM. Decompression of odontogenic cystic lesions: clinical long-term study of 73 cases. *Oral Surg Oral Med Oral Pathol Oral Radiol Endod*. 2011;112:164-9.
3. Guler N, Comunoglu N, Cabbar F. Ki-67 and MCM2 in dental follicle and odontogenic cysts: The effects of inflammation on proliferative markers. *Sci World J*. 2012;2012:946060.
4. Kolokythas A, Fernandes RP, Pazoki A, Ord RA. Odontogenic keratocyst: to decompress or not to decompress? A comparative study of decompression and enucleation versus resection/peripheral

- ostectomy. *J Oral Maxillofac Surg.* 2007;65:640-4.
5. Meshram M, Sagarka L, Dhuvad J, Anclia S, Vyas S, Shah H. Conservative management of unicystic ameloblastoma in young patients: A prospective single-center trial and review of literature. *J Maxillofac Oral Surg.* 2017;16:333-41.
  6. Pogrel MA. Treatment of keratocysts: the case for decompression and marsupialization. *J Oral Maxillofac Surg.* 2005;63:1667-73.
  7. Kolokythas A, Schlieve T, Miloro M. Simple method for securing a decompression tube for odontogenic cysts and tumors: a technical note. *J Oral Maxillofac Surg.* 2011;69:2392-5.
  8. Catunda IS, Catunda RB, Vasconcelos B, de Oliveira HF. Decompression device for cavitary bone lesions using Luer syringe. *J Oral Maxillofac Surg.* 2013;71:723-5.
  9. Meiselman F. Surgical management of the odontogenic keratocyst: Conservative approach. *J Oral Maxillofac Surg.* 1994;52:960-3.
  10. Brøndum N, Jensen VJ. Recurrence of keratocysts and decompression treatment: A long-term follow-up of forty-four cases. *Oral Surg Oral Med Oral Pathol.* 1991;72:265-9.
  11. Nakamura N, Mitsuyasu T, Mitsuyasu Y, Taketomi T, Higuchi Y, Ohishi M. Marsupialization for odontogenic keratocysts: Long-term follow-up analysis of the effects and changes in growth characteristics. *Oral Surg Oral Med Oral Pathol Oral Radiol Endod.* 2002;94:543-53.
  12. Marker P, Brøndum N, Clausen PP, Bastian HL. Treatment of large odontogenic keratocysts by decompression and later cystectomy: A long-term follow-up and a histologic study of 23 cases. *Oral Surg Oral Med Oral Pathol Oral Radiol Endod.* 1996;82:122-31.
  13. Abdullah WA. Surgical treatment of keratocystic odontogenic tumour: a review article. *Saudi Dent J.* 2011;23:615.
  14. Lizio G, Sterrantino AF, Ragazzini S, Marchetti C. Volume reduction of cystic lesions after surgical decompression: A computerised three-dimensional computed tomographic evaluation. *Clin Oral Investig.* 2013;17:1701-8.
  15. Wakolbinger R, Beck-Mannagetta J. Long-term results after treatment of extensive odontogenic cysts of the jaws: A review. *Clin Oral Investig.* 2016;20:15-22.
  16. Acar AH, Yolcu Ü, Erdem NF, Asutay F. Is conservative surgical treatment sufficient to treat unicystic mural ameloblastoma in infant? *J Craniofac Surg.* 2015;26:e297-9.
  17. Blanas N, Freund B, Schwartz M, Furst IM. Systematic review of the treatment and prognosis of the odontogenic keratocyst. *Oral Surg Oral Med Oral Pathol Oral Radiol Endod.* 2000;90:553-8.
  18. Park HS, Song IS, Seo BM, Lee JH, Kim MJ. The effectiveness of decompression for patients with dentigerous cysts, keratocystic odontogenic tumors, and unicystic ameloblastoma. *J Korean Assoc Oral Maxillofac Surg.* 2014;40:260-5.
  19. Enislidis G, Fock N, Sulzbacher I, Ewers R. Conservative treatment of large cystic lesions of the mandible: a prospective study of the effect of decompression. *Br J Oral Maxillofac Surg.* 2004;42:546-50.
  20. Kaplan I, Gal G, Anavi Y, Manor R, Calderon S. Glandular odontogenic cyst: treatment and recurrence. *J Oral Maxillofac Surg.* 2005;63:435-41.
  21. Chiapasco M, Rossi A, Motta JJ, Crescentini M. Spontaneous bone regeneration after enucleation of large mandibular cyst: a radiographic computed analysis of 27 consecutive cases. *J Oral Maxillofac Surg.* 2000;58:942-8.
  22. Schlieve T, Miloro M, Kolokythas A. Does decompression of odontogenic cysts and cystlike lesions change the histologic diagnosis? *J Oral Maxillofac Surg.* 2014;72:1094-105.
  23. Pogrel MA, Jordan RC. Marsupialization as a definitive treatment for the odontogenic keratocyst. *J Oral Maxillofac Surg.* 2004;62:651-5.
  24. Asutay F, Atalay Y, Turamanlar O, Horata E, Burdurlu MÇ. Three-dimensional volumetric assessment of the effect of decompression on large mandibular odontogenic cystic lesions. *J Oral Maxillofac Surg.* 2016;74:1159-66.
  25. Gao L, Wang XL, Li SM, Liu CY, Chen C, Li JW et al: Decompression as a treatment for odontogenic cystic lesions of the jaw. *J Oral Maxillofac Surg.* 2014;72:327-33.
  26. Kubota Y, Imajo I, Itonaga R, Takenoshita Y. Effects of the patient's age and the size of the primary lesion on the speed of shrinkage after marsupialisation of keratocystic odontogenic tumours, dentigerous cysts, and radicular cysts. *Br J Oral Maxillofac Surg.* 2013;51:358-62.
  27. Song IS, Park HS, Seo BM, Lee JH, Kim MJ. Effect of decompression on cystic lesions of the mandible: 3-Dimensional volumetric analysis. *Br J Oral Maxillofac Surg.* 2015;53:841-8.
  28. Yoshikawa Y, Nakajima T, Kaneshiro S, Sakaguchi M. Effective treatment of the postoperative maxillary cyst by marsupialization. *J Oral Maxillofac Surg.* 1982;40:487-91.
  29. Suomalainen A, Pakbaznejad Esmaceli E, Robinson S. Dentomaxillofacial imaging with panoramic views and cone beam CT. *Insights imaging.* 2015;6:1-16.