

Case Report

ACTINIC PURPURA IN A PATIENT IN THE INTENSIVE CARE UNIT: CASE REPORT

Aksoy B¹, Tatlıparmak A², Koç E³, Gökdemir G⁴, Karadayı N⁵

¹ Bahcesehir University, Faculty of Medicine, Department of Dermatology, Istanbul, Turkey; VM Medicalpark Hospital, Dermatology Clinic, Kocaeli, Turkey.

² Bahcesehir University, Faculty of Medicine, Department of Dermatology, Istanbul, Turkey; Fatih Medicalpark Hospital, Dermatology Clinic, Istanbul, Turkey

³ Bahcesehir University, Faculty of Medicine, Department of Dermatology, Istanbul, Turkey; Medicalpark Hospital, Dermatology Clinic, Ankara, Turkey.

⁴ Private Practice, Dermatology, Istanbul.

⁵ Kartal Education and research Hospital, Pathology Clinic, Istanbul

Corresponding author

Aksoy B

VM Medicalpark Hastanesi, Dermatoloji Kliniği, Ovacık mah, D-100 Karayolu Üstü, No: 36 Başiskele / Kocaeli, Turkey.

e-mail: bmaksoy@mynet.com

ABSTRACT

Actinic purpura is a dermatological disorder that is seen frequently in elderly as benign ecchymotic plaques with various sizes and localizations. A 92-year-old woman was consulted for purple lesions in the body while she was being treated in intensive care unit (ICU). The lesions were intermittent and improved spontaneously for three years. She had left-sided hemiplegia sequel, asthma and newly developed right sided hemiplegia. Dermatological examination revealed ecchymotic plaques with 3-10 cm diameter in forehead, eyelids, neck, chest and distal upper extremities. Histopathological examination of a lesional biopsy revealed epidermal atrophy, widespread solar elastosis in the dermis and focal hemorrhagic areas. The impairment of general condition of the patient continued and the patient lost his life as a result of complications at the 12th day of ICU. Widespread actinic purpura that is misdiagnosed as physical assault can be seen infrequently at the admission to ICU. The presence of actinic purpura is accepted as a poor prognostic sign in the hospitalized patients.

Key words: Actinic, purpura, senile, intensive care unit

ÖZET

Aktinik purpura çeşitli büyüklük ve lokalizasyonlarda benign ekimotik plaklar olarak yaşlılarda sık olarak görülen dermatolojik bir hastalıktır. 92 yaşındaki bir kadın yoğun bakım ünitesinde yatarken vücudundaki mor lezyonları nedeniyle konsülte edildi. Lezyonlar üç yıldır aralıklı olarak tekrar ediyor ve kendiliğinden iyileşiyordu. Hastanın sol hemiplji sekerli, astımı ve yeni gelişen sağ hemiplejisi vardı. Dermatolojik muayenede alın, göz kapakları, boyun, göğüs ve distal üst ekstremitelerde 3-10 cm çaplarında ekimotik plaklar mevcuttu. Bir lezyondan alınan biyopsinin histopatolojik incelemesi epidermal atrodi, dermişte yaygın solar elastoz ve fokal hemoraji alanlarını gösterdi. Hastanın genel durumundaki bozukluk devam etti ve yoğun bakım ünitesindeki 12. gününde hayatını kaybetti. Fiziksel travma olarak yanlış tanı alabilen yaygın aktinik purpura yoğun bakım ünitelerinden sıkça görülebilir. Aktinik purpuranın mevcudiyeti hospitalize hastalarda kötü prognostik belirti olarak kabul edilir.

Anahtar kelimeler: Aktinik, purpura, senil, yoğun bakım ünitesi

INTRODUCTION

Actinic purpura is a common (12%) dermatological disease with a benign nature, characterized by ecchymotic plaques with varying diameter and

localization following minor-trauma.^{1,2} It is mostly used synonymously with senil purpura. The relative reduction of skin microvasculature with age and thickened

dermal microvascular basal membrane layer ultimately leads to an increase in

permeability in skin microvessels and development of post-traumatic purpura.²

CASE REPORT

A 92-year-old female patient was consulted to dermatology by the intensive care unit for the evaluation of purple lesions on the body. These lesions were accepted as traumatic assault in the intensive care unit. After a detailed story, it was learned that these complaints had been present intermittently for three years and spontaneously healing. Her medical history included left sequel hemiplegia, asthma, newly developed right hemiplegia. There was no property in her family history. On dermatologic examination, there were

ecchymotic plaques on the forehead, eyelids, chest V region, distal upper extremities with diameters ranging from 3 cm to 10 cm (Figure 1). In the laboratory tests performed to exclude bleeding diathesis, INR was 1.36, prothrombin time was 14.8 sec, Hb was 11.7 g / L and platelets were 171.000 / μ L. Histopathological examination of the punch biopsy from the lesions revealed atrophy of the epidermis, diffuse solar elastosis and focal hemorrhagic areas in the dermis (Figure 2).

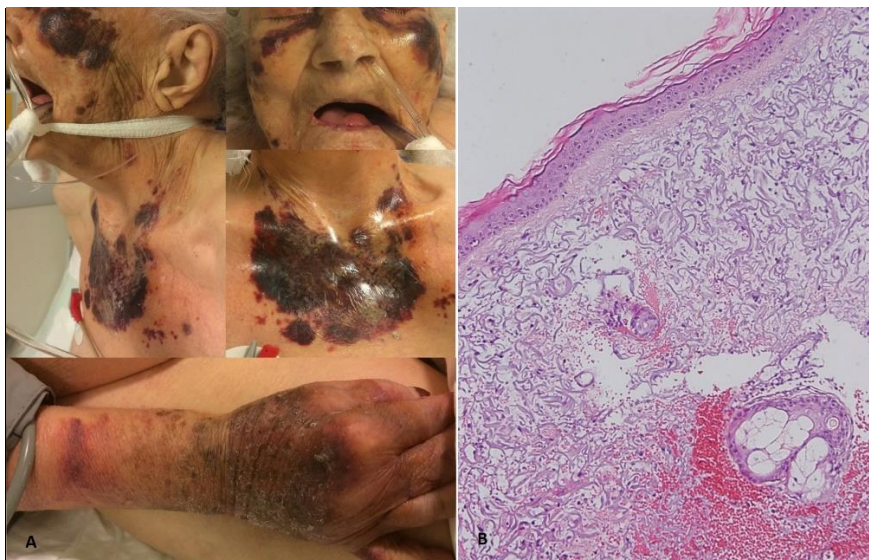


Figure 1. A) Widespread purpuric lesions in the photoaged face, neck, chest, and forearm , **B)** Atrophy of epidermis, diffuse solar elastosis and areas of focal hemorrhage in dermis (Hematoxylin & Eosin, X200).

All these clinical and histopathological findings were considered to be in accordance with a diagnosis of senile / actinic purpura. The patient died during the

follow-up at the intensive care unit 12th day as a result of her primary neurological disorder (cerebrovascular event) and complications.

DISCUSSION

The most important differential diagnoses in the presence of purpura in a critically ill patient include purpura fulminans, thrombotic thrombocytopenic purpura, kumadin or heparin necrosis.³⁻⁵ Actinic purpura confused with traumatic assault may be seen very rarely in the admission to the intensive care unit. Actinic purpura was considered primarily in the differential diagnosis because skin findings of our case were confined to photoaging areas, but it was thought that aspirin-induced skin necrosis or purpura fulminans could be other possibilities in a critically ill patient. Skin biopsy and laboratory examinations confirmed that the skin findings of our case were due to actinic / senile purpura.

In a study of hospitalized 1125 elderly patients, it was reported that senile purpura prevalence was 5%. The presence of senile purpura is increasing with age and more common in men. In this study, patients with senile purpura were reported to have been in the hospital for longer periods and had more mortality rate in the hospital. As a result, it has been suggested that senile purpura may be a poor prognostic factor in hospitalized patients.⁶ Our case with widespread senile purpura had poor general condition in intensive care unit course and eventually died.

CONCLUSION

Actinic purpura confused with traumatic assault may be seen very rarely in the admission to the intensive care unit and may cause difficulties in the differential

diagnosis. Actinic purpura presence in hospitalized patients may be a poor prognostic factor.

Acknowledgment

We would like to thank Muhanne followed and treated the case in the Bereketoğlu and his entire team who have intensive care unit.

REFERENCES

1. Reszke R, Pełka D, Walasek A, Machaj Z, Reich A. Skin disorders in elderly subjects. *Int J Dermatol* 2015; 54: e332-8.
2. Borroni RG, Grassi S, Concardi M, Agozzino M, Caspani C, Giordano C, et al. Involvement of dermal microvascular basement membrane in senile purpura: quantitative immunohistochemical study. *J Eur Acad Dermatol Venereol* 2016; 30: e63-e65.
3. Murad AA, Jeffers M, Tobin AM, Connolly M. Purpura fulminans in a patient with mixed connective tissue disease. *BMJ Case Rep* 2013; 2013: bcr2012007947.
4. Zou X, Wu T, Zhang X, Qu A, Tian S. Thrombotic thrombocytopenic purpura (TPP) successfully rescued by plasma exchange in the ICU: A report of two cases. *Exp Ther Med* 2016; 12: 329-332.
5. Adya KA, Inamadar AC, Palit A. Anticoagulants in dermatology. *Indian J Dermatol Venereol Leprol* 2016; 82: 626-640.
6. Wong HY. Hypothesis: Senile purpura is a prognostic feature in elderly patients. *Age and Aging* 1988; 17: 422-424.