

# Treatment of Hepatitis C Virus with Peginterferon and Ribavirin May Trigger Atrioventricular Nodal Reentrant Tachycardia in An Intensive Care Unit Patient



Mustafa Yıldız<sup>1</sup>, Ahmet Çağrı Aykan<sup>2</sup>, Banu Şahin Yıldız<sup>3</sup>, Gönenc Kocabay<sup>1</sup>

<sup>1</sup> Kartal Koşuyolu High Specialization Training and Research Hospital, Clinic of Cardiology, İstanbul, Turkey

<sup>2</sup> Ahi Evren Chest Cardiovascular Surgery Training and Research Hospital, Clinic of Cardiology, Trabzon, Turkey

<sup>3</sup> Dr. Lütfi Kırdar Kartal Training and Research Hospital, Clinic of Cardiology, İstanbul, Turkey

## ABSTRACT

The treatment of hepatitis C virus (HCV) with peginterferon (Peg-IFN)  $\alpha$ 2b and ribavirin is more effective than with conventional interferon and ribavirin. Despite the important effects of Peg-IFN and ribavirin therapy, many side effects, such as fever, fatigue, anxiety, irritability, neutropenia and thrombocytopenia, may be observed. In addition, cardiac arrhythmias and syncope are rare consequences of Peg-IFN therapy. In this study, we report an intensive care unit patient who developed atrioventricular nodal reentrant tachycardia (AVNRT), which is the most common type of reentrant supraventricular tachycardia, and presyncopal attack during Peg-IFN and ribavirin therapy.

**Key Words:** Hepatitis C virus; peginterferon; ribavirin; atrioventricular nodal reentrant tachycardia

## Yoğun Bakım Hastasında Hepatit C Virüsünün Peg-İnterferon ve Ribavirin ile Tedavisi Atrioventriküler Nodal Reenteran Taşikardiye Neden Olabilir

### ÖZET

Hepatit C virüsü (HCV) tedavisinde peginterferon (Peg-IFN) $\alpha$ 2b ve ribavirin tedavisi konvansiyonel interferon ve ribavirin tedavisinden daha etkilidir. Peg-IFN ve ribavirin tedavisinin önemli etkilerinin yanında ateş, halsizlik, heyecan, huzursuzluk, nötropeni ve trombositopeni gibi bir çok yan etki görülebilir. Ayrıca kardiyak aritmiler ve senkop gibi nadir olaylar da Peg-IFN tedavisine bağlı gelişebilir. Bizler bu çalışmada Peg-IFN ve ribavirin tedavisi sırasında presenkop atağı ve reenteran taşikardilerin en sık formu olan atrioventriküler nodal reenteran taşikardi gelişen bir yoğun bakım hastasını sunuyoruz.

**Anahtar Kelimeler:** Hepatit C virüsü; Peg-interferon; ribavirin; atrioventriküler nodal reenteran taşikardi

## INTRODUCTION

Hepatitis C virus (HCV) infection is often asymptomatic, but chronic infections can lead to liver scarring and ultimately cirrhosis that is generally apparent after many years. The current treatment of HCV is a combination of peginterferon  $\alpha$ 2b (Peg-IFN) and ribavirin for 24 or 48 weeks<sup>(1)</sup>. The treatment of HCV with Peg-IFN and ribavirin is more effective than with conventional interferon and ribavirin<sup>(2)</sup>. Despite the important effects of Peg-IFN and ribavirin therapy, many side effects, such as fever, fatigue, anxiety, irritability, neutropenia and thrombocytopenia, have been reported<sup>(2)</sup>. In addition, cardiac arrhythmias and syncope are rare consequences of Peg-IFN therapy<sup>(3)</sup>. In this study, we report an intensive care unit patient who developed atrioventricular nodal reentrant tachycardia (AVNRT), which is the most common type of reentrant supraventricular tachycardia, and presyncopal attack during Peg-IFN and ribavirin therapy.

## CASE REPORT

A 46-year-old man developed palpitation and presyncopal attack within 10 weeks of starting Peg-IFN (150  $\mu$ g/week) and ribavirin (1200 mg/day) therapy for the treatment of chronic HCV. He had developed palpitation approximately 20 years ago and had not taken any medications.

## Correspondence

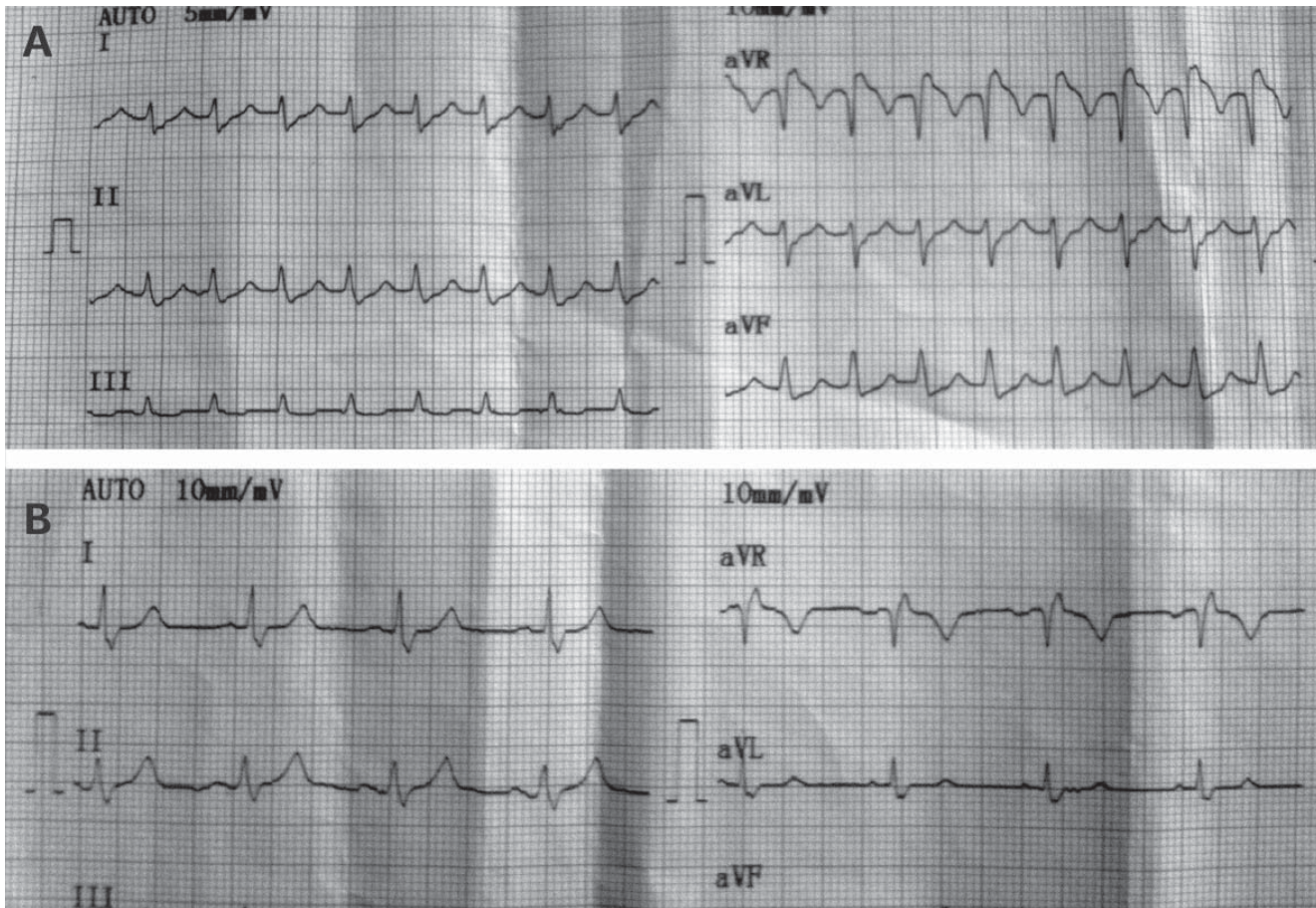
Mustafa Yıldız

E-mail: mustafayildiz@yahoo.com

Submitted: 02.12.2013

Accepted: 05.12.2013

@ Copyright 2016 by Koşuyolu Heart Journal.  
Available on-line at  
www.kosuyoluheartjournal.com



**Figure 1.** (A) The surface electrocardiogram revealed AVNRT, (B) tachycardia stopped after an intravenous administration of 5 mg metoprolol.

In the intensive care unit, surface electrocardiogram (ECG) and 24-h Holter ECG revealed AVNRT (Figure 1A). Tachycardia stopped after intravenously administering 5 mg metoprolol (Figure 1B). Transthoracic echocardiography and thyroid hormone and other routine laboratory tests were normal. We offered electrophysiology study and catheter ablation therapy to the patient, but he refused them. After the AVNRT attack, the Peg-IFN dose was decreased (120 µg/week) and 50 mg/day metoprolol was initiated. After 10 weeks, AVNRT occurred again during infusion. The patient refused the ablation therapy again. Therefore, the metoprolol dose was increased to 100 mg/day. Close follow-up revealed neither palpitation nor presyncope, and HCV-RNA was undetectable at 24 and 48 weeks of treatment.

## DISCUSSION

The side effects of Peg-IFN and ribavirin combination therapy for HCV have been documented; however, cardiac arrhythmias are rarely reported<sup>(2)</sup>. Moreover, AVNRT is not associated with Peg-IFN therapy in the literature.

AVNRT is the most common regular supraventricular tachycardia observed in intensive care unit, originating above

the His bundle<sup>(4)</sup>. It occurs when a reentry circuit forms within or just next to the AV node. The circuit usually involves two anatomical pathways (dual AV nodal physiology): the fast and slow pathways, which are usually targeted for ablation<sup>(5)</sup>. The slow pathway is located inferior and slightly posterior to the AV node, often following the anterior margin of the coronary sinus. The fast pathway is usually located just superior and posterior to the AV node. The AVNRT therapy can be used for AV nodal slowing drugs, such as adenosine, beta-blockers, as in our case, or non-dihydropyridine calcium channel blockers. Furthermore, for cure, patients can undergo an electrophysiology study via a generally slow pathway ablation.

In this case, these drugs may cause atrial premature complexes during infusion, and the atrial premature complexes may in turn affect the dual pathway physiology. Finally, AVNRT may be triggered. To cure this rhythm, we offered the electrophysiology study and catheter ablation therapy to the patient, but he refused them. Therefore, we had to continue the medical therapy with beta-blockers.

**REFERENCES**

1. Wilkins T, Malcolm JK, Raina D, Schade RR. Hepatitis C: diagnosis and treatment. *Am Fam Physician* 2010;81:1351-7.
2. Okanoue T, Sakamoto S, Itoh Y, Minami M, Yasui K, Sakamoto M, et al. Side effects of high-dose interferon therapy for chronic hepatitis C. *J Hepatol* 1996;25:283-91.
3. El-Atrebi K, El-Bassyouni HT. Management of rare side effects of peginterferon and ribavirin therapy during hepatitis C treatment: a case report. *Cases J* 2009;2:7429.
4. Katritsis DG, Camm AJ. Atrioventricular nodal reentrant tachycardia. *Circulation* 2010;122:831-40.
5. Yıldız M, Aykan AC, Kahveci G, Demir S, Ozkan M. Transvenous radiofrequency ablation therapy as an effective and safe method for the treatment of the slow pathway of atrioventricular nodal re-entrant tachycardia. *Koşuyolu Heart J* 2011;14:51-5.