

Hemoplasmosis (*Mycoplasma* sp.) in a captive non domestic cat (*Panthero leo*) with renal failure

Serkal Gazyagci¹, Bugrahan Bekir Yagci¹, Zeynep Pekcan², Aycan Nuriye Gazyagci³, Erdal Kara¹

¹Department of Internal Disease, University of Kirikkale, Faculty of Veterinary Medicine, 71452 Kirikkale, Turkey.

²Department of Surgery, University of Kirikkale, Faculty of Veterinary Medicine, 71452 Kirikkale, Turkey.

³Department of Parasitology, University of Kirikkale, Faculty of Veterinary Medicine, 71452 Kirikkale, Turkey.

Received: 07.11.2018

Accepted: 15.11.2018

ABSTRACT

A two-year old lioness (*Panthero leo*) was referred to our clinic with nasal and oral bleeding, vomiting and anemia. As being informed by the owner; we learned that the lion had a history of anorexia, nasal discharge, fatigue, dehydration and apathy just one month prior to admitting the clinic. At the laboratory examination Urea, Creatinine and RBC (red blood cell) were higher than normal. Coronavirus, Feline Leukemia Virus, Feline Immunodeficiency Virus (Rapid FIV/Ab FeLV Ag Test Kit, Bionote®) agents were checked with commercial immunochromatographic rapid test kit and found as negative. *Haemobartonella* sp was found by blood smear. Enrofloxacin (Baytril-K % 5, Bayer®) 10 mg/kg dose for 10 days once a day and vitamin K and supportive fluid were given for treatment. All clinical signs and abnormal blood values returned to normal levels after 17 days. This report indicated that *Haemobartonella* sp is important agent also for wild cats and all cats should be controlled for this to infection even if suffered from renal failure.

Key words: Lion, *Haemobartonella* sp, Enrofloxacin, Treatment.

INTRODUCTION

Haemobartonella felis (*Mycoplasma haemofelis*) is a causative gram negative bacteria and epicellular on erythrocytes, known as the feline infectious anemia, infecting wild cats. The organisms are nearly 0,5 µm in diameter and rod, ring or coccoid shaped structures in the blood smear, chain form is rare. Based on the studies; *Mycoplasma haemofelis* (Neimark et al., 2001) *Candidatus M. Haemominitum* (Foley and Pedersen, 2001) *Candidatus M. turicensis* (Willi et al., 2005) were isolated from the domestic cats. Blood sucking arthropods are main source of transmission of infection between cats. Fleas and ticks play a major

role for transmission (Willi et al., 2006). Direct transmission is also important between cats due to hemoplasma DNA is monitored in saliva and feces as reported by some of authors (Willi et al., 2007). It has been hypothesized that vertical transmission is possible between cats but no evidence exists as experimentally until now (Harvey and Gaskin 1977).

Clinical signs are several, dependent on the factors the host susceptibility, hemoplasma species involved even in acute infections or not. Clinical status ranges from the asymptomatic to life threatening crises (Willi et al., 2007). Within the attachment of etiological agent leading to damage to RBC surface within anemia and

hemolysis observed (Messick, 2004). Depression, rapid weight loss, anorexia, lethargy, loss of appetite, variable fever, anemia, splenomegaly and icterus might be observed as clinical manifestations (Haefner et al., 2003; Tasker and Lappin, 2002; Ural et al., 2009). Blood smear examination (such as acridine orange, May–Gruenwald–Giemsa, Wright–Leishman, and Wright–Giemsa), PCR analysis and Serology are used for detecting hemobartonellosis (Ural et al., 2008; Tasker and Lappin, 2002). *Hemobartonella felis* is commonly associated with FeLV (Feline Leukemia Virus), FIV (Feline Immunodeficiency Virus), or FIP (Feline Infectious Peritonitis) (Haefner et al., 2003). Doxycycline (10 mg/kg, daily, PO), enrofloxacin (5 mg/kg daily, PO), marbofloxacin (2 mg/kg, daily, PO) have been used for treatment and shown to reduce blood organism load (Willi et al., 2007).

CASE

A two-year old female lion (*Panthero leo*) was presented to our clinic with nasal and oral bleeding weighing as 155 kg (Figure 1), vomiting (Figure 2) and anemia. As being informed by the owner; the lion had a history of anorexia, nasal discharge, fatigue, dehydration, apathy existed about one month. At the physical examination: mucous membranes color had been altered from white to yellow. Anesthetic agents were administered i.m. three times during hospitalization of lioness (xylazine and ketamine). Blood was collected following anesthesia. Blood sample was drawn from the saphenous vein into tubes coated with ethylene diamine tetra acetic acid (EDTA) and serum tube. A fresh blood smear was made immediately after blood collection and stained with Wright–Giemsa. Complete blood counts were performed immediately. A combined test kit for FIV antibodies and FeLV antigen was used. Serum biochemistry values were detected.

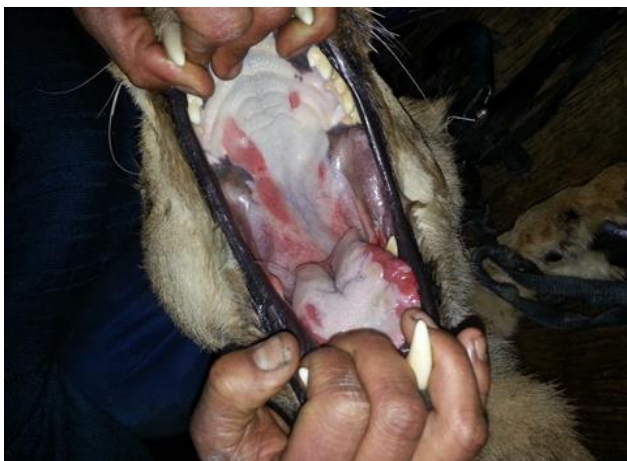

Figure 1: Mucosal ulcers and erosions in the mouth of lion

White blood cell counts revealed 21.780 cells/ μl (mean 11.8×10^3 cells/ μl). Hematocrits; 51.99% ($x=34.4\%$), with an MCV of 41 fl ($x=51.6$ fl) (Table 1). The case was positive for *H. felis* by microscopic examination of freshly prepared Giemsa-stained blood smears (Figure 3). The lion in this study tested negative for FeLV and FIV and FIP. Blood urea (399 mg/dl) and creatine (21.9 mg/dl) levels were elevated (Table 2). No pathological findings were detected by urine examination.



Figure 1: Vomiting

Enrofloxacin (Baytril-K 5%, Bayer) was administered at a dose of 10 mg / kg for 10 days for treatment. During hospitalization, ulcerative centers inside the mouth were cleaned with glycerin iodine daily, while foot injuries were treated with daily dressing (Figure 4).

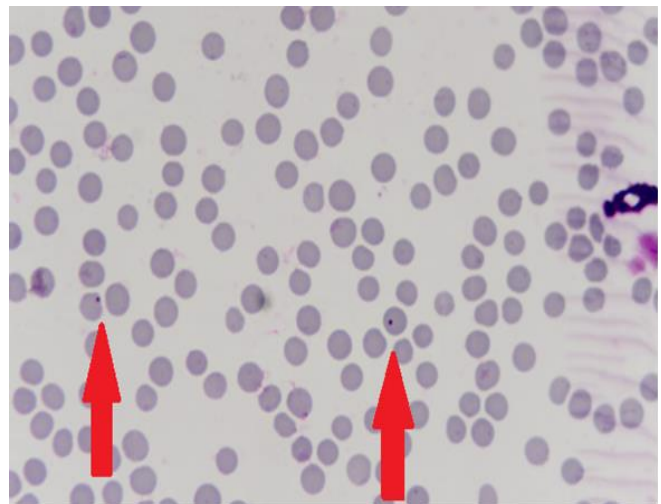


Figure 3: Viewing of *Haemobartonella* sp. under microscope.

For supportive treatment, Vitamin K (Libavit K 60 mg, Liba® IV) and fluid treatment (0,9% Saline IV–Dextran 40 IV) were administered and after 17-day hospitalization, the lion was discharged from the hospital. The blood creatinine level, which was 21.9 at the beginning of the treatment, decreased to 1.83 after 1 week of treatment. At the end of the 17-day period of treatment, lion's appetite returned to normal, vomiting stopped and physical movement recovered. In the follow-up, it was learned that the discharged lion

was able to continue his duty in circus performances sturdily.

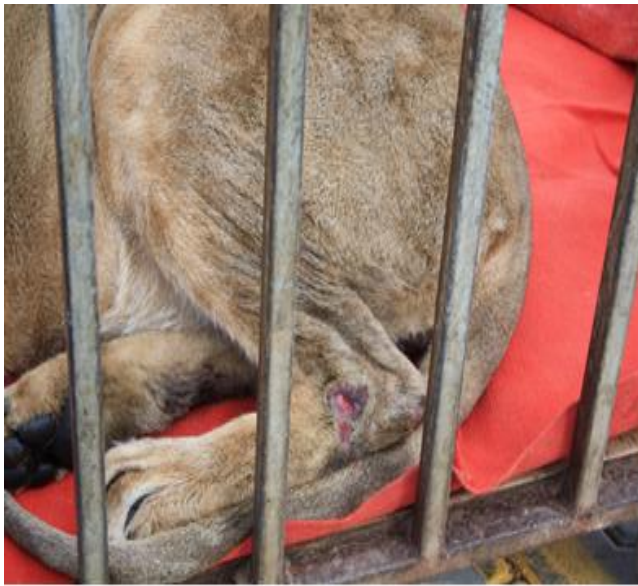

Figure 4: Dermal lesions

DISCUSSION

In wild felids, in free ranging animals have higher infection risk than in captive wild cat in a zoo environment (Willi et al., 2007). Infection might be transmitted between felids via blood-sucking arthropods, blood transfusion and iatrogenic mistakes (Willi et al., 2006). In this case, it was not possible to know the source of infection.

Parameters	First Estimate	Second Estimate	The Reference Range [13]
Hgb (g/dl)	19,4 (H)	12	8,9–14,6
HCT (%)	51,99	32,86	26,8–44,1
RBC(x10 ⁶ cells/ μ l)	12,68 (H)	7,89	5,0–8,4
MCV (fL)	41 (L)	42 (L)	48,0–56,7
MCH (pg /cell)	15,4 (L)	15,2 (L)	15,5–19,1
MCHC (g/dL)	37,3 (H)	36,5 (H)	30,4–35,7
WBC (x1000 C/ μ l)	21,78	30,12 (H)	7,2–25,6

Table 1: The data of cell blood of counting.

The hemabartonellosis mechanism underlying renal failure have not been understood. However to it has been thought that renal failure induces the metabolic reactive, produce oxidative stress and cause reactive hemabartonella sp. infection as latent. Willi et al. (2007) has reported that a dosage above 5 mg /kg of enrofloxacin is not recommend due to risk of retinal

degeneration and blindness. In this case high dose was (10 mg/kg, daily, i.m) administered for 10 days but complication or side effect was not observed.

To the previous study that *Candidatus M. haemominutum* is prevalent among pet cat population in Turkey (Ural et al., 2008). To the present study that this case was not performed by polymerase chain reaction assay just cytological examination was performed with stained smear referral demonstrated (Romanowsky) microscopic evidence of hemobartonellosis so substitute could not detected of Mycoplasma (*Haemobartonella* sp.) (Tasker and Lappin, 2002).

Parameters	First Estimate	Second Estimate	The Reference Range [14]
Glucose (mg/dl)	134	187 (H)	122,3 \pm (21,3)
Urea (mg/dl)	399 (H)	188,6	64,8 \pm (12,4)
Cholesterol (mg/dl)	176	120	165,5 \pm (27,4)
Creatinine (mg/dl)	21,9 (H)	1,83	2,97 \pm (0,42)
K (mval/l)	5,44 (H)	4,13	3,74 \pm (0,26)

Table 2: The data of blood biochemistry.

CONCLUSION

This is the first case in a wild cat in Turkey with hemabartonellosis and renal failure in a 2 year lioness. This case indicates that captured non domestic cats at a risk of hemabartonellosis and caution should be taken even if they have renal failure.

Conflict of Interest: No conflict of interest was declared by the authors.

Financial Disclosure: The authors declared that this study has received no financial support.

REFERENCES

Foley JE, Pedersen NC. *Candidatus Mycoplasma haemominutum*, a low-virulence epierythrocytic parasite of cats. *Int J Syst Evol Microbiol.* 2001; 51: 815-817.

Haefner M, Burke TJ, Kitchell BE, Lamont LA, Schaeffer DJ, Behr M, Messick JB. Identification of *Haemobartonella felis* (*Mycoplasma Haemofelis*) in captive nondomestic cats. *J Zoo and Wildlife Med.* 2003; 34(2): 139-143.

- Harvey JW, Gaskin JM. Experimental feline haemobartonellosis. *J Am Anim Hosp Assoc.* 1977; 13: 28-38.
- Larsson MHMA, Flores AS, Fedullo JDL, Teixeira RHF, Mirandola RMS, Ito FH, Pessoa RB, Itikawa PH. Biochemical parameters of wild felids (*Panthera leo* and *Panthera tigris altaica*) kept in captivity. *J Semina Ciencias Agrarias* 2017; 38(2): 791-800.
- Maas M, Keet DF, Nielan M. Hematologic and serum chemistry reference intervals for free-ranging lions (*Panthera leo*). *Research in Veterinary Science.* 2013; 95: 266-268.
- Messick JB. Hemotropic mycoplasmas (hemoplasmas): a review and new insights into pathogenic potential. *Vet Clin Pathol.* 2004; 33: 2-13.
- Neimark H, Johansson KE, Rikihisa Y, Tully JG. Proposal to transfer some members of the genera *Haemobartonella* and *Eperythrozoon* to the genus *Mycoplasma* with descriptions of Candidatus *Mycoplasma haemofelis*, Candidatus *Mycoplasma haemomuris* Candidatus *Mycoplasma haemosuis* and Candidatus *Mycoplasma wenyonii*. *Int J Syst Evol Microbiol.* 2001; 51: 891-899.
- Tasker S, Lappin MR. *Haemobartonella felis*: recent development in diagnosis and treatment. *J Feline Med Surg.* 2002; 4: 3-11.
- Tasker S, Lappin MR. *Haemobartonella felis*: recent developments in diagnosis and treatment. *J Feline Med. Surg.* 2002; 4(1): 3-11.
- Ural K, Kurtdele A, Ulutas B. Prevalence of hemoplasma infection in pet cats from 4 different provinces in Turkey. *Revue de Medecine Veterinaire.* 2009; 160(5): 226-30.
- Ural K, Süer C, Vatanserver Z, Kar S, Eker K, Cingi CC. Candidatus *Mycoplasma Haemominutum*” infection in a cat in Antalya. *Firat Universitesi Sağlık Bilimleri Dergisi.* 2008; 22(1): 27-30.
- Willi B, Boretti FS, Baumgartner C, Tasker S, Wenger B, Cattori V, Meli ML, Reusch CE, Lutz H, Hofmann-Lehmann R. Prevalence risk factor analysis, and follow-up of infections caused by three feline hemoplasma species in cats in Switzerland. *J Clin Microbiol.* 2006; 44: 961-969.
- Willi B, Boretti FS, Cattori V, Tasker S, Meli ML, Reusch C, Lutz H, Hofmann-Lehmann R. Identification, molecular characterization, and experimental transmission of a new hemoplasma isolate from a cat with hemolytic anemia in Switzerland. *J Clin Microbiol.* 2005; 43: 2581-2585.
- Willi B, Filoni C, Catao-Dias JL, Cattori V, Meli ML, Vargas A, Martinez F, Roelke ME, Rysler-Degiorgis MP, Leutenegger CM, Lutz H, Hoffman-Lehman R. Worldwide occurrence of feline hemoplasma infections in wild felid species. *J Clin Microbiol.* 2007; 45: 1159-1166.