

The role of MR Myelogram in the diagnosis of traumatic pseudomeningocele

Hanifi Bayaroğulları^a, Nesrin Atci^{a,*}, Murat Altaş^b, Mustafa Aras^b, Raif Özden^c

^aDepartment of Radiology, Mustafa Kemal University School of Medicine, Hatay, Turkey

^bDepartment of Neurosurgery, Mustafa Kemal University School of Medicine, Hatay, Turkey

^cDepartment of Orthopedics, Mustafa Kemal University School of Medicine, Hatay, Turkey

Abstract. Traumatic pseudomeningocele is a valuable indicator of nerve root injury. Secondary to trauma, the traction forces firstly tear meninges and later if the traction forces are great enough, nerve root avulsions occur. In this article, we aimed to show pseudomeningoceles localized at the level of brachial and lumbar plexus secondary to nerve root injury.

We retrospectively reviewed the patients who admitted to our hospital between 2009 and 2011 due to various accidents. After clinical and radiological examinations, spinal root injuries were detected in six patients at different levels.

Brachial plexopathy was detected in four patients and lumbosacral plexopathy was detected in two patients.

Pseudomeningocele is a valuable indicator of nerve root injury. It occurs after dural torn like pouch. MR and MR myelography is the best imaging modality to indicate its' pouch and cerebrospinal fluid (CSF) within it. MR and MR myelography are best effective imaging modalities to indicate the pseudomeningoceles due to nerve root injury.

Key words: Brachial plexopathy, lomber plexopathy, magnetic resonance myelography, pseudomeningocele

1. Introduction

Pseudomeningoceles can present postoperatively or after trauma. Traumatic intraspinal pseudomeningoceles have been described rarely in previous cases, including one due to direct trauma and others due to a plexus avulsion injury. Rarely, they cause symptoms from spinal cord herniation or mass effect from extra- or intraspinal extension. The pseudomeningocele is usually associated with a nerve root avulsion. Pseudomeningocele is an indicator of nerve root avulsion or nerve root injury. Traumatic nerve root avulsions, especially

in lumbosacral segment, present with pseudomeningoceles at the time of initial imaging. Magnetic resonance (MR) myelography is a non-invasive technique that can provide anatomic information about the subarachnoid space and pseudomeningoceles. In this article, we aimed to show that MR and MR myelography are the best effective imaging modalities to indicate the pseudomeningoceles due to nerve root injury.

2. Patients and Method

We retrospectively reviewed the patients who were admitted to our hospital between 2009 and 2011 due to various accidents. After clinical and radiological examinations, spinal root injuries were detected in six patients at different levels. Four patients were male and two patients were female. The age of patients were ranged from 6 to 47 years (mean age, 28). MR unite with a 1.5-Tesla property (Achieva; Philips Healthcare, The Netherlands) was used each patient for routine MR and MR myelography scans for the investigation of nerve root avulsion and pseudomeningocele.

*Correspondence: Nesrin Atci, M.D.

Department of Radiology, Tayfur Ata Sökmen Medical Faculty, Mustafa Kemal University, 31700, Hatay, Turkey

Phone: +903262291000

Fax: +903262455654

Mobile Phone: +905052526497

E-mail: nesrinatci@gmail.com

Received: 24.10.2012

Accepted: 03.03.2013

3. Results

Brachial plexopathy was detected in four patients and lumbosacral plexopathy was detected in two patients. In case 1, T2-weighted fast spin-echo pulse sequence and MR myelography showed C7 nerve root avulsion and pseudomeningocele on the left C7 nerve root

extending through the neural foramina and paravertebral spaces between scalene muscles (Figure 1a-c). There was nerve root avulsion, pseudomeningocele on the right C6, C7, and C8 nerve root in case 2 (Figure 2a-c) on the C5 and C6 nerve root in case 5 and on the right C6, bilateral C7 nerve root in case 6.

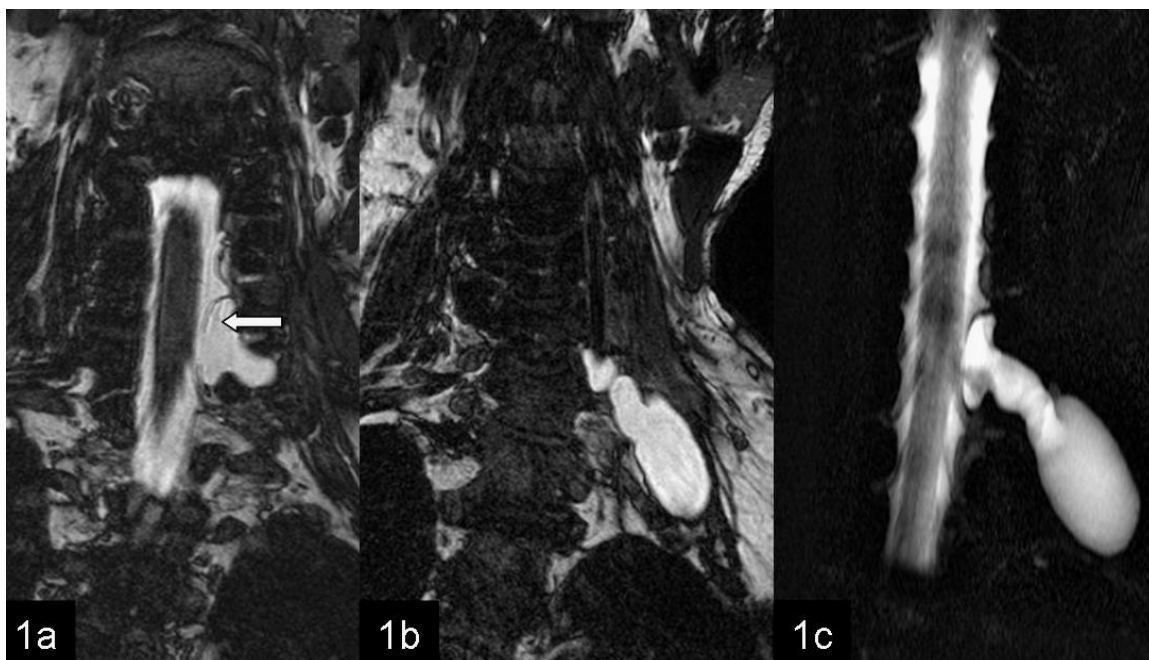


Fig. 1 a-c: 1a-b Coronal T2-weighted fast spin-echo MRI. 1a- Dural tears (arrow) and intraspinal-foraminal part of Pseudomeningocele. 1b- Paravertebral part of pseudomeningocele. 1c-Magnetic resonance myelography images of pseudomeningocele.

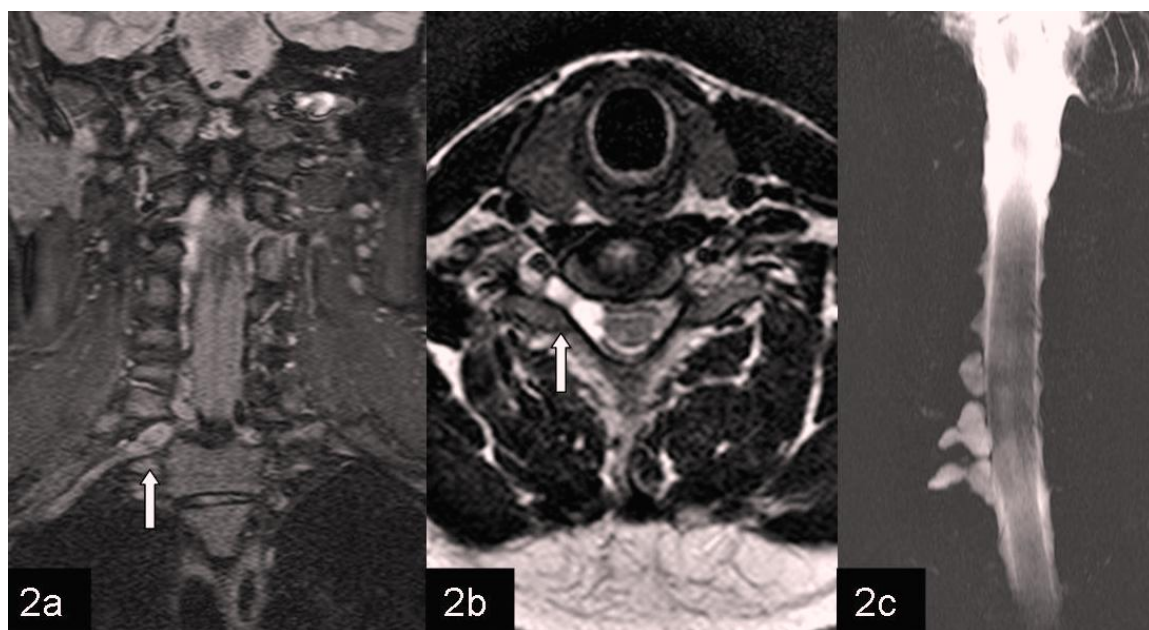


Fig. 2 a-c: Coronal and axial T2-weighted fast spin-echo MRI and MR myelography. 2a-b. C8 right foraminal part of pseudomeningocele and nerve sheets dilatation (arrow). 2c. MR myelography images of pseudomeningocele.

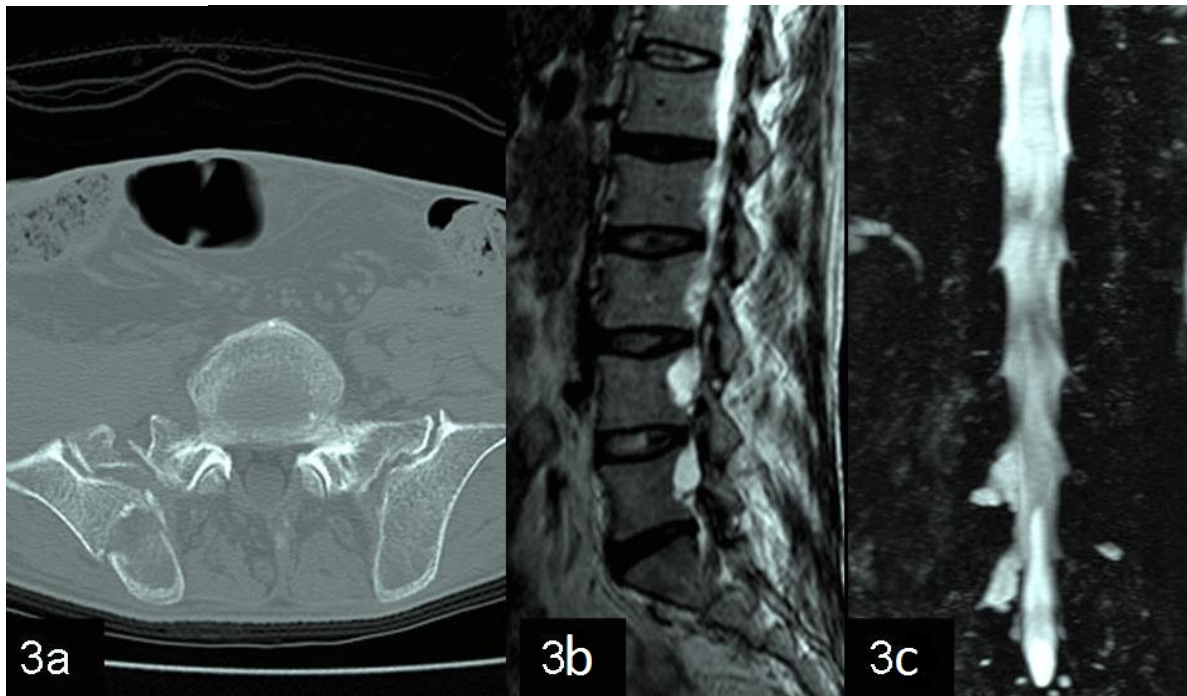


Fig. 3 a-c: 3a. Axial CT scan and 3b-c. Coronal T2-weighted fast spin-echo MRI and MR myelography. 3a. Right iliac and sacral fractures. 3b. Scalloping posterior vertebral body contour due to pseudomeningocele. 3c. MR myelography images of pseudomeningocele.

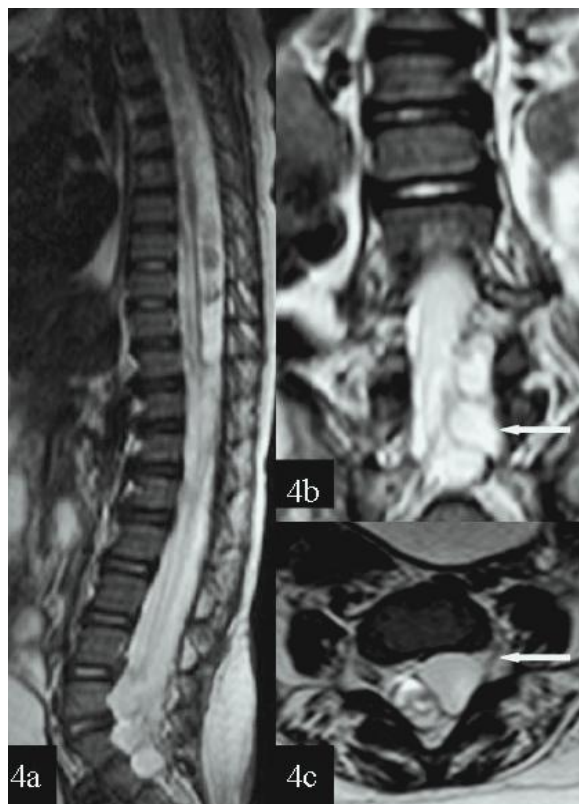


Fig. 4 a-c: Sagittal, coronal, and axial T2-weighted spin-echo MRI. 4a. Thoracolumbar myelopathy, 4b-c. Nerve root avulsion and intraspinal pseudomeningocele on the left lumbosacral nerve root.

The nerve root avulsion and pseudomeningocele was observed on the right L4 and L5 level in case 3 (Figure 3a-c). Thoracolumbar myelopathy, nerve root avulsion and pseudomeningocele on the left lumbosacral nerve root was detected in case 4 (Figure 4a-c). There was pelvic fracture in case 3 and case 4.

4. Discussion

Traumatic tears into the dura mater formed as a result of injury or avulsion nerve root (1,2). Traumatic brachial plexopathy is more common than thoracic and lumbosacral plexopathy (3). Avulsion of the lumbosacral nerve roots is seen more rarely than avulsion of the brachial nerve root. Because lumbosacral nerve roots are protected against extreme stretching by the pelvis and lumbar spine. Since 1960, a few cases of the traumatic avulsion of the lumbosacral nerve roots have been reported (4-7).

Brachial plexopathy (C5-T1 spinal segment), lumbar plexopathy (L1-L4 spinal segment) and sacral plexopathy (L5-S3 spinal segment) cause weakness, sensory loss, and loss of tendon reflexes. Traumatic injury to a peripheral nerve may range from disruption of axonal conduction with preservation of anatomical continuity to severe nerve disruptions (8). The most common cause of brachial and lumbar plexopathy is traffic accident. Especially, other traumatic causes

include accidents at work, sports injuries, incised wounds, gunshot wounds, and patient malpositioning during surgery (9-12). Five of our cases were injured in traffic accident and one was in work accident. The other cause for brachial plexopathy, birth palsy that affected upper brachial plexus (Erb-Duchenne palsy) and lower brachial plexus (Klumpke palsy) is the other traumatic plexopathy. C5-C6 spinal nerve injury, at shoulder muscles and biceps, C7 spinal nerve injury, at some of the wrist muscles, C8-T1 spinal nerves lead to paralysis of the forearm flexor and the intrinsic muscles of the hand. Injuries to the stellate ganglion or cervical sympathetic trunk cause Horner syndrome.

It is very important to differentiate the preganglionic injuries from postganglionic lesions for determining the management of brachial plexus injury (13). Preganglionic injuries are restored with nerve transfers. Postganglionic lesions are repaired with nerve grafting or followed up conservatively. Secondary to traumatic injury, the other sign than pre and postganglionic nerve root injury and avulsion are pseudomeningoceles, posttraumatic neuromas, hematomas, and fibrosis.

A traumatic meningocele is not pathognomonic but a valuable sign of a preganglionic avulsion injury. A pseudomeningocele is usually associated with a nerve root avulsion, but a nerve root avulsion can occur without formation of a pseudomeningocele. Nerve root avulsions and pseudomeningoceles were observed in all of our cases. Traumatic nerve root avulsions, especially in lumbosacral segment present with pseudomeningoceles at the time of initial imaging (14,15). MR imaging is rarely performed immediately after injury, because of traumatic matters.

Pseudomeningocele formation occurs after dural torn, later CSF leaks into the adjacent tissue, and within several days, the tear close with leaving a pouch-like extension. Pseudomeningoceles seem to have gradual enlargement due to CSF pulsations. Meningoceles may expand by a ball-valve mechanism and become clinically significant. Eventually, exploration and decompression are needed (16-18). There was significant Pseudomeningocele in all of our cases. Pseudomeningocele of the case 4 presented in the intra-spinal area but others presented in the intra and extra-spinal areas

MR myelography is a non-invasive technique that can provide anatomic information about the subarachnoid space. Major advantages of MR myelography over conventional radiographic myelography include its lack of ionizing

radiation, non-invasive nature, and lack of need for intrathecal contrast material. MR myelography is better than CT myelography in the detection of pseudomeningoceles, because some of the pseudomeningoceles have little or no communication with the dural sac, therefore contrast agent will not fill it (19-21).

5. Conclusion

Pseudomeningocele is a valuable indicator of nerve root injury. It occurs after dural torn like pouch. MR and MR myelography is the best imaging modality to indicate its' pouch and CSF within it.

References

1. Walter LO, Donald WC, Isabelle B, Jacques R. Spine and spinal cord trauma. In: Manelfe C, ed. *Imaging of the Spine and Spinal Cord*. New York: Raven Press, 1992, pp 407-444.
2. Dubendorf P Spinal cord injury pathophysiology. *Crit Care Nurs Q* 1999; 22:31-35.
3. Delmas PF, Roger B, Travers V, Laval-Jeantet M, Sedel L. Modern technics for studying injuries of the lumbo-ischiatic plexus. Apropos of a new case *J Radiol* 1986; 67:115-118.
4. Finney LA, Wulfman WA. Traumatic intradural lumbar nerve root avulsion with associated traction injury to the common peroneal nerve. *Am J Roentgenol* 1960; 84:952-957.
5. Goodell CL. Neurological deficits associated with pelvic fractures. *J Neurosurg* 1966; 24:837-842.
6. DaSilva VR, Al-Gahtany M, Midha R, Sarma D, Cooper P. Upper thoracic spinal cord herniation after traumatic nerve root avulsion. *J Neurosurg: Spine* 2003; 99:306-309.
7. Yokota H, Yokoyama K, Noguchi H, Uchiyama Y. Spinal cord herniation into associated pseudomeningocele after brachial plexus avulsion injury: case report. *Neurosurgery* 2007; 60:E205.
8. Sunderland S. A classification of peripheral nerve injuries producing loss of function. *Brain* 1951; 74:491-516.
9. Nagano A Treatment of brachial plexus injury. *J Orthop Sci* 1998; 3:71-80.
10. Millesi H Brachial plexus injuries. In: Jupiter JB, ed. *Flynn's hand surgery*. 4th ed. Baltimore, Md: Williams & Wilkins, 1991, pp 457-463.
11. Gutowski KA, Orenstein HH. Restoration of elbow flexion after brachial plexus injury: the role of nerve and muscle transfers. *Plast Reconstr Surg* 2000; 106:1348-1357.
12. Terzis JK, Vekris MD, Soucacos PN. Outcomes of brachial plexus reconstruction in 204 patients with devastating paralysis. *Plast Reconstr Surg* 1999; 104:1221-1240.
13. Gupta RK, Mehta VS, Banerji AK, Jain RK. MR evaluation of brachial plexus injuries. *Neuroradiology* 1989; 31:377-381.
14. Maillard JC, Zouaoui A, Bencherif B, Bouayed N, Chedid G, Marsault C. Imaging in the exploration of lumbosacral plexus avulsion. *J Neuroradiol* 1992; 19:38-48.

15. Hans FJ, Reinges MH, Krings T. Lumbar nerve root avulsion following trauma: balanced fast field-echo MRI. *Neuroradiology* 2004; 46:144-147.
16. Rankine JJ. Adult traumatic brachial plexus injury. *Clin Radiol* 2004; 59:767-774.
17. Sachdev VP, Huang YP, Shah CP, Malis LI. Posttraumatic pseudomeningocele (enlarging fracture ?) in a vertebral body. *J Neurosurg* 1981; 54:545-549.
18. Petras AF, Sobel DF, Mani JR, Lucas PR. CT-myelography in cervical nerve root avulsion. *J Comput Assist Tomogr* 1985; 9:275-279.
19. Figueroa RE, Stone JA. MR imaging of degenerative spine disease: MR myelography and imaging of the posterior spinal elements. In: Castillo M., ed. *Spinal imaging, state of art*. Philadelphia: Hanley & Belfus, 2001, pp 105-122.
20. Bowen BC, Seidenwurm DJ. For the Expert Panel on Neurologic Imaging. Plexopathy. *AJNR Am J Neuroradiol* 2008; 29:400-402.
21. Smith AB, Gupta N, Strober J, Chin C. Magnetic resonance neurography in children with birth-related brachial plexus injury. *Pediatr Radiol* 2008; 38:159-163.