

# US and CT findings of Hibernoma in an unusual location

Alpaslan Yavuz<sup>a,\*</sup>, Aydın Bora<sup>a</sup>, Mehmet Beyazal<sup>a</sup>, Cemil Göya<sup>b</sup>

<sup>a</sup>Department of Radiology, Yuzuncu Yil University, Van, Turkey

<sup>b</sup>Department of Radiology, Dicle University, Diyarbakır, Turkey

**Abstract.** Hibernomas are asymptomatic, slow-growing tumors occurring in the anatomical sites where of brown fatty tissue was found in fetal life such as inter-scapular region or thigh. Retroperitoneal localization is an unusual site for this tumor and only few cases have been published in the literature. These tumors are benign in nature without any recurrence after total excision or evidence of metastasis. The purpose of this presentation is to demonstrate the US and CT findings of retroperitoneal hibernoma with the review of the literature.

Key words: Hibernoma, brown fat tissue, retroperitoneal space

## 1. Introduction

Hibernoma is a rare benign soft tissue tumor composed of the remnants of fetal brown fat. The tumor of brown fat was first described by Merkel in 1905 and was named as pseudolipoma (1). In 1914, Grey et al. (2) demonstrated that, these tumors were histologically similar to the brown fat of hibernating animals; therefore he called these benign neoplasms as hibernoma. Brown adipose tissue is believed to have a role in thermoregulation and is first recognized in human fetuses at the 21<sup>st</sup> week of gestation. Brown fat is present in the human fetus and newborn, gradually decreases in mass with age. Only small amounts persist in adult age era. In humans, residual brown fat is sited in the interscapular region, the neck, axillary and the mediastinal areas which are the most common sites of hibernomas to occur as might be expected (3-5). They have also been reported in sites including the scalp, buttock, popliteal fossa and scrotum, and intracranial, intraspinal and periureteral regions (3-10). Contrary to other fatty tumors types which usually occur within the 4<sup>th</sup> and the 7<sup>th</sup> decade, the peak age for hibernoma is the 3<sup>rd</sup>

decade with a mean age of 38 years (11). Review of the up-to-date literature shows a slight, but not significant, predominance of males over females (11). Retroperitoneal localization is an unusual site for this tumor and only few cases have been published in the literature (12,13).

## 2. Case report

A 13-year-old male was admitted to our clinic with 1 month history of periumbilical abdominal pain, sudden weight loss (6 kg in 1 month) and increased sweating. There was no past history of remarkable abdominal disorder or surgery. In physical examination, there was no significant finding except mild discomfort of periumbilical region while palpation. There was no significant finding in plain abdominal radiography. Abdominal ultrasonography (US) revealed a 60 x 57 x 39 mm, well-circumferenced, heterogeneous preaortic mass encasing celiac truncus (Figure 1). Posterior borders of pancreas and left lobe of the liver could not be evaluated clearly from the mass. The lesion was compressing aorta and splenic vein minimally. Power Doppler US revealed that; the proximal segment of superior mesenteric artery (SMA) was adjacent with the mass and there was no finding to dedicate in favor of stenosis of SMA or celiac artery (Figure 2). In helical computed tomography (CT) examination, lesion was heterogeneous, mildly hyperdense with well-defined borders (Figure 3). In both CT and US, there was no clear fatty plain between the mass and the pancreatic corpus. Because of the relationship with the main arterial

\*Correspondence: Dr. Alpaslan Yavuz  
Yuzuncu Yil University Radiology Department  
Adress: Ercis Yolu; Van /TURKEY  
Tel: 00 90 532 3424959  
E-mail: alp\_yavuz@hotmail.com  
Received: 27.05.2013  
Accepted: 10.07.2013

vessels, the mass was not totally resected, partial resection could be performed. Brown fat tissue adipocytes with centrally localized nucleus were seen and hibernoma was revealed as final histopathologic diagnosis.

### 3. Discussion

Hibernomas are asymptomatic, slow-growing tumors occur in the anatomical sites where brown fatty tissue was found during fetal life such as inter-scapular region or thigh. Retroperitoneal localization is extremely rare. Microscopically, the tumor is characterized by multivacuolated cells with eccentric nuclei and granular eosinophilic cytoplasm, univacuolated cells with peripheral nuclei, and smaller round cells with granular cytoplasm. The hypervascularity and the presence of cells with eosinophilic granular

cytoplasm full of mitochondria give hibernomas their brown color (3).

The radiologic features of hibernomas are still not pathognomonic; thus, CT and Magnetic resonance imaging MRI are not specific and vary with the nature and amount of lipid component. Non-contrast CT usually demonstrates a well demarcated soft tissue mass of predominantly low attenuation which is close but not identical to subcutaneous fat. On the other hand, more heterogeneous patterns can be encountered as well as in our case. Both US and contrast-medium administrated CT revealed that, hibernomas commonly present with well-demarcated borders and no evident fat content may be evaluated. In addition; hibernomas have rich internal vasculature and enhance with i.v. contrast administration; diffuse contrast medium uptakes

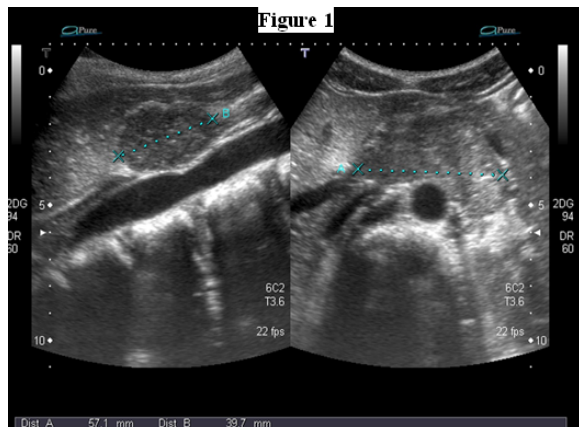


Fig. 1. Sagittal and axial US scan revealed heterogeneous mass with the size of 60 x 57 x 39 mm located preaortic region.

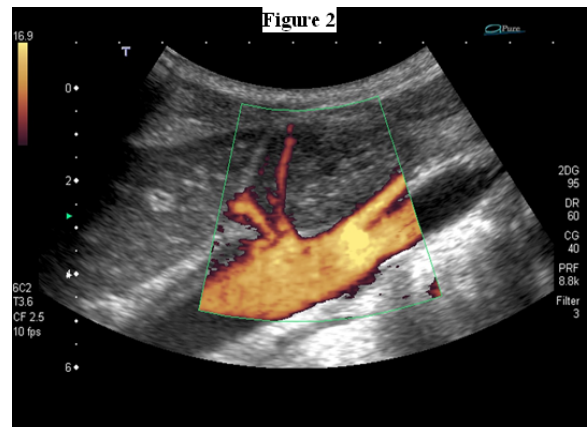


Fig. 2. Power Doppler US demonstrated the celiac trunk passing through the mass and SMA is adjacent to inferior border of the tumor.

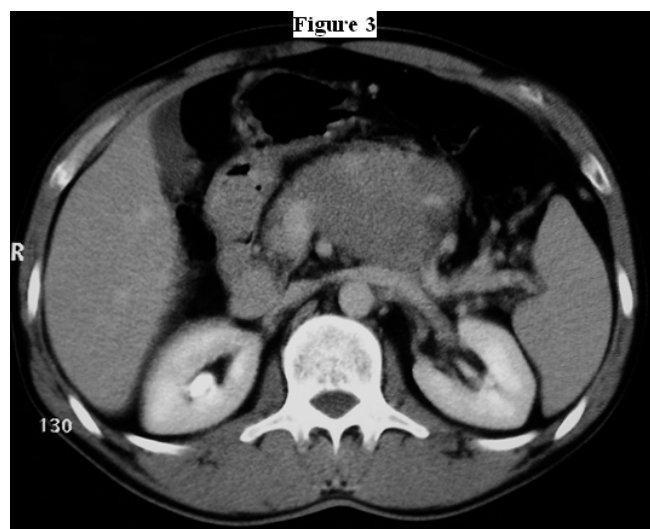


Fig. 3. Abdominal CT revealed preaortic soft tissue retroperitoneal mass encasing celiac trunk and proximal branches.

and septal contrast enhancement patterns have been reported in the literature (14,15). Hypervascular nature of the tumor also leads the angiographic examination to become favorable for diagnosis, however it can misdirect clinicians into suspecting a malignant process (16).

Hibernomas usually have been described as well delineated or encapsulated (17). However, infiltration of adjacent structures may be present (18). Lowry and Halmos describe a case of hibernoma that infiltrated particularly striated muscle and was removed incompletely; postoperative irradiation was administered (19). Enterline et al. (20) described a tumor located in the retropharynx; the mass surrounded parathyroid tissue and also isolated a small area of the thyroid gland but was not deeply invasive. Another two cases of recurrent hibernoma, referred by Enterline et al, had 'strips reminiscent of liposarcoma or polymorphocellular sarcoma' within the tumors. Only one case of hibernoma was described as pseudoencapsulated and histologically resembling an anaplastic sarcoma with features of Brown adipose tissue that was also noted on ultrastructural examination (21). This tumor was located in the interscapular region and recurred 4 weeks following the resection, with extensive involvement of the interscapular area, including the interfascicular planes of the trapezius muscle. No recurrence was observed during 2 years follow up and after radiotherapy with adjuvant chemotherapy. In our patient, proximal segment of celiac truncus was fully encased by retroperitoneal hibernoma. SMA was crossing the inferior border of the mass tangentially. The color and power Doppler US revealed that, in both arteries (celiac and SMA), the blood flow pattern was normal, no findings of stenosis, even vascular wall irregularity were not existed. In the management of treatment, incomplete resection could be performed to avoid the injury of celiac artery and post-operative irradiation was administered.

In conclusion, hibernoma should be included in the differential diagnosis of retroperitoneal soft tissue tumors and although minority of retroperitoneal adipose tissue originated tumors show histological signs of benignity, retroperitoneal hibernomas are generally benign in nature. Only a few cases of metastasis, invasion or signs of recurrence after surgery were reported. Incompletely excision may result in recurrence and increased growth rates, even in tumors that appear to be histologically benign. Therefore, total surgical excision is the remarkable choice for treatment (18,22).

## References

1. Merkel H. Ubereinpseudolipoma der Mama (elgenartigerFettzellen tumor). Beitr Pathol Anat Alleg Pathol 1906; 39: 152-157.
2. Grey L. Discussions. Bull Mem Soc Anat (Paris) 1914; 00: 111-112.
3. Murphey MD, Carroll JF, Flemming DJ, et al. From the archives of the AFIP: benign musculoskeletal lipomatous lesions. Radiographics 2004; 24: 1433-1466.
4. Drevelegas A, Pilavaki M, Chourmouzi D. Lipomatous tumors of soft tissue: MR appearance with histological correlation. Eur J Radiol 2004; 50: 257-267.
5. Bancroft LW, Kransdorf MJ, Peterson JJ, O'Connor MI. Benign fatty tumors:classification clinical course imaging appearance and treatment. Skeletal Radiol 2006; 35: 719-733.
6. Stephen AH, Sanjay RP, John WB. Hibernoma of the pericardium presenting as pericardial effusion in a child. Ped Pathol 1990; 10: 575-580.
7. Fletcher CDM, Cole RS, Gower RL, Heyderman E. Hibernoma of the spermatic cord: the first reported case. Br J Urol 1986; 58: 99-100.
8. Gulmez I, Dogan A, Balkanlı S, et al. The first case of periureterichibernoma. Scand J Urol Nephrol 1996; 31: 203-204.
9. Muszynski CA, Robertson DP, Goodman JC, Baskin DS. Scalp hibernoma: Case report and literature review. Surg Neurol 1994; 42: 343-345.
10. Chitoku S, Kawai S, Watebe Y, et al. Intradural spinal hibernoma: Case report. Surg Neurol 1998; 49: 509-513.
11. Furlong MA, Fanburg-Smith JC, Miettinen M. The morphologic spectrum of hibernoma: a clinicopathologic study of 170 cases. Am J Surg Pathol 2001; 25: 809-814.
12. Cantisani V, Mortelet KJ, Glickman JN, et al. Large retroperitoneal hibernoma in an adult male: CT imaging findings with pathologic correlation. Abdom Imaging 2003; 28: 721-724.
13. Yohannan J, Feng T, Allaf ME. Retroperitoneal hibernoma in a 28-year-old man. Urology 2011; 78: 320-321.
14. Dursun M, Agayev A, Bakir B, et al. CT and MR characteristics of hibernoma: six cases. Clin Imaging 2008; 32: 42-47.
15. Alvine G, Rosenthal H, Murphey M, Huntrakoon M. Hibernoma. Skeletal Radiol 1996; 25: 493-496.
16. Rigor VU, Goldstone SE, Jones J, et al. Hibernoma: a case report and discussion of a rare tumor. Cancer 1986; 57: 2207-2211.
17. Gaffney EF, Hargreaves HK, Semple E, Vellios F. Hibernoma: distinctive light and electron microscopic features and relationship to Brown adipose tissue. Hum Pathol 1983; 14: 677-687.
18. Lele MS, Chundru S, Chaljub G, Adegboyega P, Haque AK. Hibernoma.A Report of 2 Unusual Cases with a Review of the Literature. Arch Pathol Lab Med 2002; 126: 975-978.
19. Lowry WSB, Halmos PB. Malignant tumor of Brown fat in a patient with Turner's Synrome. Br Med J 1967; 4: 720-721.
20. Enterline HT, Lowry LD, Richman AV. Does malignant hibernoma exist? Am J Surg Pathol 1979; 3: 265-271.

21. Teplitz C, Farrugia R, Glicksman AS. Malignant hibernoma does exist (abstract). *Lab Invest* 1980; 42: 154-155.
22. Kallas KM, Vaughan L, Haghghi P, Resnick D. Hibernoma of the left axilla; a case report and review of MR imaging. *Skeletal Radiol* 2003; 32: 290-294.