

Removal of a supernumerary tooth displaced into the infratemporal fossa during extraction

Accidental displacement of an impacted tooth into the infratemporal fossa (ITF) is a rare but serious complication because of the vulnerability of the surrounding anatomical structures. Here we present the case of a 40-year-old man who reported pain on the right side of his face. Panoramic radiography and cone-beam computed tomography revealed an impacted third molar and a supernumerary tooth positioned immediately below it. Under local anesthesia, the third molar was easily extracted; however, the supernumerary tooth was inadvertently displaced into the ITF. The position of the tooth was confirmed by radiographic examination, and it was immediately removed intraorally by expanding the flap and carefully dissecting the soft tissues. Clinical aspects of this rare complication were evaluated, with special emphasis on the reliability of imaging modalities and surgical techniques.

Keywords: *Infratemporal fossa, supernumerary, cone beam computed tomography, accidental displacement, complication*

Türker Yücesoy¹,
Hakan Ocak²,
Nilay Er³,
Alper Alkan¹

Introduction

Removal of an impacted maxillary third molar or supernumerary tooth is a routine procedure in the daily clinical practice of oral and maxillofacial surgery. Maxillary tuberosity and root fracture, maxillary sinus perforation, prolapse of the buccal fat pad are common complications of this procedure (1, 2). However; displacement of an entire tooth into the anatomical spaces such as infratemporal fossa (ITF) is a serious but rarely reported occurrence (3).

Infratemporal fossa contains lateral and medial pterygoid muscles, the branches of the mandibular nerve, the otic ganglion, the chorda tympani, the maxillary artery, and the pterygoid venous plexus and it is also bounded in front by the posterior surface of the maxilla, behind by the styloid process, above by the infratemporal surface of the greater wing of the sphenoid, medially by the lateral pterygoid plate, and laterally by the ramus of the mandible (4). Because of the vulnerable nature of neighboring anatomical structures, patients are at risk of having a post-operative infection, limitation of mouth opening, prolonged pain and foreign-body reaction (1, 4-6). Even ligation of the internal maxillary artery and blood transfusion may become necessary in the case of abundant bleeding (1).

Radiographic examination is crucial to determine the exact location of displaced tooth. Diagnostic potential of conventional techniques such as occlusal, panoramic or occipitomenal radiographers are limited even when they are used simultaneously (7). The introduction of cone-beam computed tomography (CBCT) in the field of oral and maxillofacial surgery dramatically increased the quality of medical care in such conditions, as it is now possible to obtain high-resolution images of the relevant anatomy from multiple planar orientations. Analysis of CBCT images allows pin-

¹Department of Oral and Maxillofacial Surgery, Bezmialem Vakıf University, Faculty of Dentistry, İstanbul, Turkey

²Department of Oral and Maxillofacial Surgery, Private Dental Hospital, Kayseri, Turkey

³Department of Oral and Maxillofacial Surgery, Trakya University, Faculty of Dentistry, Edirne, Turkey

Corresponding Author: Türker Yücesoy
E-mail: dt.yucesoy@hotmail.com

Received: 11 July 2017

Revised: 23 August 2017

Accepted: 20 September 2017

DOI: 10.26650/eor.2018.31977

pointing the location of the displaced tooth, in exchange for relatively low levels of ionizing radiation when compared to medical CT, which is also capable of providing similar diagnostic information (3).

The aim of this article is to report the displacement and immediate removal of a supernumerary maxillary tooth into ITF with special emphasis being on the surgical procedures and the reliability of imaging modalities.

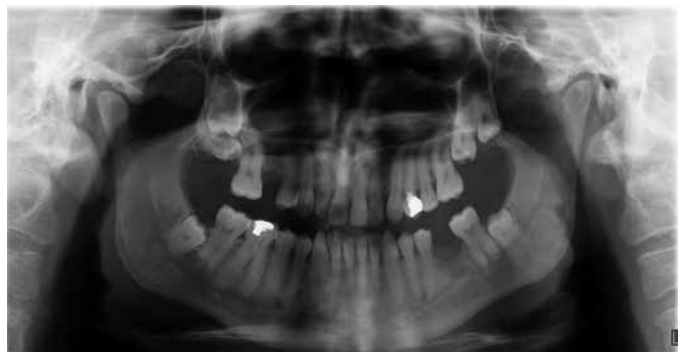

Figure 1. Pre-operative panoramic radiograph showing impacted third molar and supernumerary teeth.

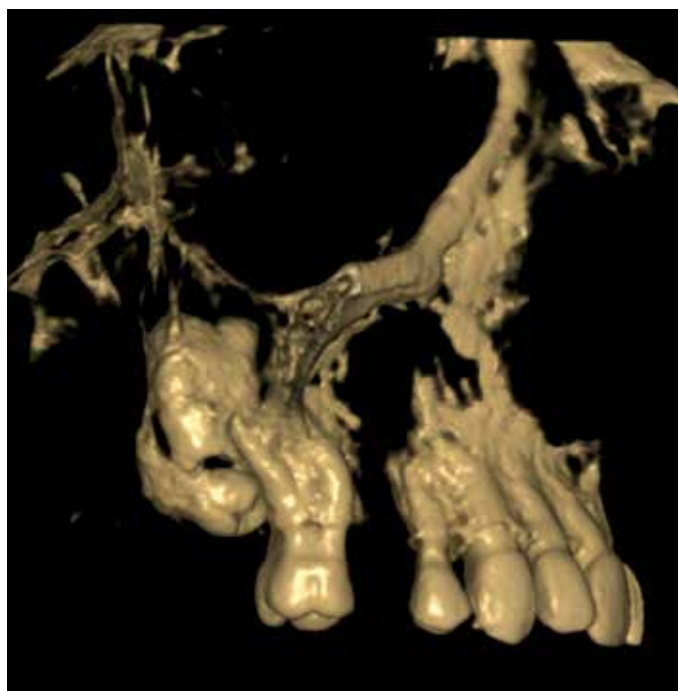

Figure 2. Pre-operative three dimensional reconstruction with volume rendering algorithm.

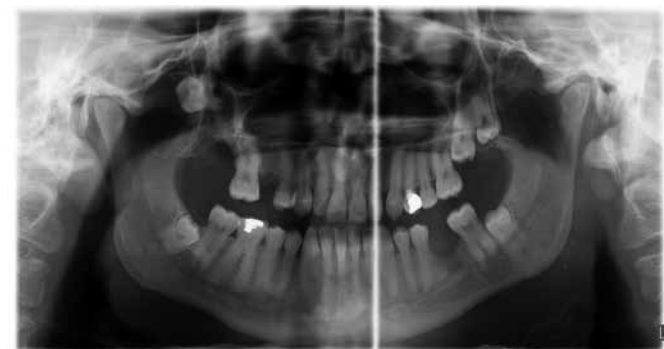


Figure 3. Panoramic radiograph of the displaced tooth taken during the surgery.

Case report

In May 2012, a 40-year-old male applied as a self-referred patient complaining of having persistent pain for the last three months at the right side of his face. His medical history was non-contributory. There was no visible swelling, tenderness or pus discharge. Skin color and temperature were normal. In the intraoral examination of the relevant region, oral hygiene level was good and oral mucosa was in normal color. The patient stated that his maxillary right first molar tooth had been extracted more than five years ago without any problem. The second molar was found to be in good condition, but no third molar could be observed.

Digital panoramic radiography (PANO) was selected as the initial radiographic modality (OP200D digital, Kavo Instrumentarium Dental, Charlotte, NC, USA) by using the following imaging parameters: 66-85 kVp, 10-16 mA, 14.1 exposure time. An impacted third molar tooth in the horizontal position was observed immediately below the level of alveolar crest, along with an impacted supernumerary tooth which was located more superiorly in the vertical orientation. To overcome the effects of superimposition on the diagnostic process, CBCT imaging was ordered as the advanced imaging modality. Newtom 5G CBCT device (QR, Verona, Italy) was used to acquire tomographic data with 0.25 mm isotropic voxel size setting. Images were displayed on 32 inches liquid crystal display screen with a resolution of 1280 × 1024 pixels and examined in the NNT viewer (Version 3.0, Verona, Italy) installed in a Dell Precision T5400 workstation (Dell, Round Rock, TX, USA). Multiplanar reconstructions from the axial and coronal planes confirmed that the patient had an impacted third molar with curved roots and supernumerary tooth located superiorly to the third molar (Figure 1, 2).

Based on the findings of radiographic examination that corroborate clinical complaints, simultaneous surgical extraction of the impacted third molar and the supernumerary tooth was planned. Maxillary third molar was extracted without any problems under local anesthesia with 4% articaine with epinephrine 1:200.000 (Ultracain DS, Sanofi Aventis, İstanbul, Turkey) via the intraoral approach. The crown of the supernumerary tooth then became immediately visible. After removing some bone, a Bein elevator was used to move the tooth in the craniocaudal direction. Although the crown of the supernumerary tooth has emerged out of the crestal bone; it was not possible to keep a tight grip with the extraction forceps. Therefore, a hemostatic clamp was used to further move the tooth vertically. However, when the clamp was released to replace it with the extraction forceps, the tooth immediately disappeared deeper into the soft tissues. Visual inspection was not possible at that time because of the prolapsed buccal fat pad and hemorrhage. To determine the position of the tooth, another set of PANO (Figure 3) and CBCT imaging (Figure 4a, b) was obtained which clearly showed that the tooth has been displaced into the ITF and positioned medially to coronoid notch between the lateral wall of the maxillary sinus and the zygomatic arch (Figure 5).

The patient was clearly informed about the situation and he approved to undergo surgical exploration under local anesthesia. The blood clot was removed and the incision was

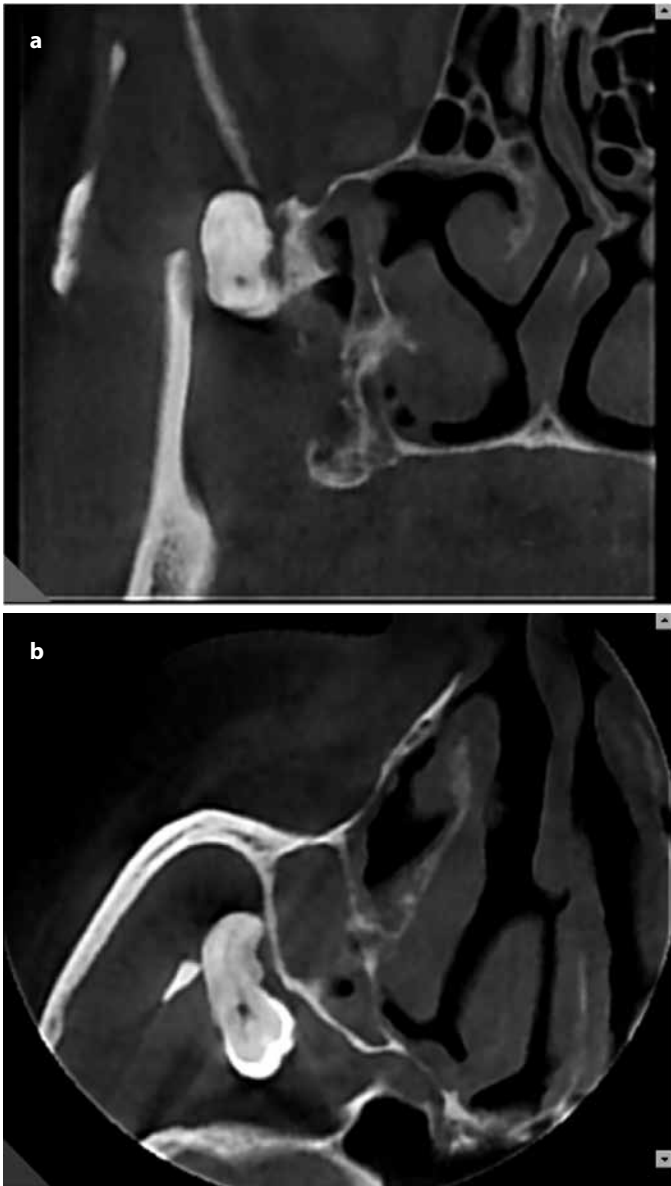


Figure 4. a, b. (a) Coronal view of displaced tooth in cone beam computed tomography. Note the displaced tooth between lateral superior wall of maxilla and coronoid process of mandible. (b) Axial view of displaced tooth in cone beam computed tomography.

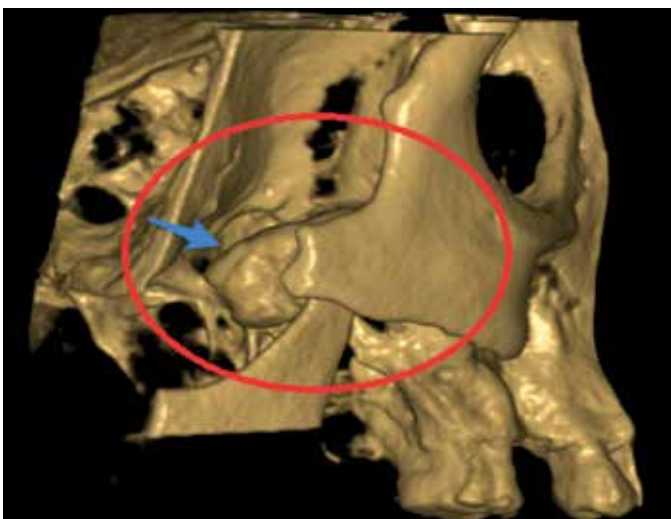


Figure 5. Three dimensional reconstruction by using volume rendering algorithm based on cone beam computed tomography data taken during the surgery. Blue arrow indicated the displaced tooth which was located medially to the coronoid notch of the mandible.

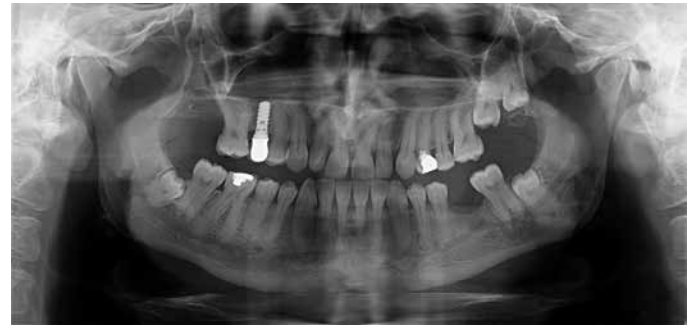

Figure 6. Panoramic radiography taken two years after the surgical removal of the displaced tooth.

extended to reveal the maxilla in the superior and posterior directions. A metal tongue depressor was used to protect and retract the buccal fat pad and muscles from the surgical site. Bone was removed from the maxillary tuberosity to increase visibility after carefully measuring the distance between the alveolar crest and the displaced tooth in CBCT. The crown of the supernumerary tooth was located and it was removed immediately. The surgical site was checked for signs of excessive hemorrhage, maxillary sinus perforation or any related complications. As none was found, oxidized regenerated cellulose was used as the hemostatic agent (Surgicel Nu-Knit, Johnson and Johnson Medical, Arlington, TX, USA) was inserted into the cavity. Primary wound closure was achieved by using a 3-0 vicryl polyglactin resorbable suture (Ethicon, Inc, Somerville, NJ, USA). 1000 mg amoxicillin combined with 250 mg clavulanate (Augmentin, GlaxoSmithKline, Brentford, UK) per oral twice daily for five days and 25 mg dextketoprofen-trometamol (Arveles, IEUlagay-Menarini Group, Italy) per oral twice daily for five days were prescribed for infection control and pain management, respectively. Healing was uneventful at one week control and the patient claimed that his initial symptoms have been resolved. Two years of the follow-up period was completed with no complication (Figure 6).

Discussion

Possible complications of maxillary impacted molar surgery include the displacement of the tooth into anatomical spaces (6) such as maxillary sinus, infratemporal fossa, buccal, lateral pharyngeal, and pterygomandibular spaces (7-14). The maxillary sinus is the most frequent space into which the maxillary third molars are dislocated but the displacement of a tooth into the ITF is a rare occurrence (4).

Displacement of maxillary teeth has been associated with lack of knowledge of the basic principles of surgical technique, lack of anatomical knowledge, inadequate flap design and decreased visibility during surgical extraction, incorrect extraction technique, distopalatal angulated tooth, tooth crown in the more superior level of the adjacent molar root apexes, limited bone volume distal to the teeth (7, 15). Applying excessive force when using the elevator may fracture the thin cortical layer of the buccal wall, thereby leading to the displacement of the tooth into the anatomical spaces. Consistently, Orr (16) reported that the right maxillary tooth has displaced into the infratemporal fossa because of the inattentive use of the elevator. Although excessive force

has not been applied in the present case, the supernumerary tooth was located superiorly to the right maxillary third molar and the root apices were angulated, which might have led the tooth to be stuck between muscular attachments and mucoperiosteal flap during extraction. Extracting the supernumerary tooth by using standard forceps proved to be very difficult in the present case, as the tip of the instrument was too short. Therefore, the hemostatic clamp was used because of its seemingly ergonomic design. However, although being long enough, a firm grip could not be established by using that clamp, probably because of its thin profile.

PANO is the standard imaging modality for the surgical extraction of impacted third molars (17, 18). However, angulation of the third molar and the position of the root relative to the maxillary sinus on panoramic radiographs can be difficult to diagnose because of the superimpositions of the anatomical structures. CBCT is capable of presenting high-quality cross-sectional images from different planes that provide more reliable diagnostic information regarding the position of the maxillary third molars (19). On the other hand, clinicians should remember that CBCT still uses higher ionizing radiation doses than PANO, therefore, benefit/cost ratio should be carefully evaluated to adhere to the As Low As Reasonably Achievable (ALARA) principles (20, 21). In the present case, CBCT was used for planning as well as emergency purposes, which shows the versatility of this imaging modality.

The timing for surgery is critical in the removal of displaced teeth, as potential risks may increase over time. The most notable risks of the delayed surgery include infection, limitation of mouth opening, pain, and foreign-body reaction (1, 4-6). Winkler *et al.* (22) reported a patient in whom swelling, pain, and mouth opening impairment developed almost 7 years after the displacement of the right maxillary third molar into the infratemporal fossa. In addition, external root resorption and pulp necrosis were observed in the removed teeth which may be considered as signs of an ongoing odontogenic infection (4, 15). On the other hand, some authors (7, 8) suggested postponing the removal procedure until the tooth is immobilized by fibrous tissue formation, as any attempt made before the formation of the fibrous capsule may dislodge the tooth deeper towards the base of the skull. It is important to note that, however, articles in which the authors suggest to delay the procedure have been mostly published before the year of 2000, a time when oral and maxillofacial surgeons had limited or no access to computed tomography. Accordingly, in the present case, immediate removal was performed based on the accurate information obtained from CBCT.

The ITF is a relatively large anatomical space with confined borders. Accordingly, a variety of surgical techniques has been proposed over the years to gain access to the ITF, such as Gillies's technique, Hemicoronal or coronal approaches and modifications of Caldwell-Luc procedure (2, 15). However, leaving the fragment in the displaced place could be another option (23). Additionally, the endoscopic approach may provide a direct view of the ITF for avoiding complications. Battisti *et al.* (24) suggested the use of endoscopic devices. Authors mentioned that, as only one hand will be free to use, endoscopy may be perceived as uncomfortable at first, however, this can be overcome with practice.

All of the techniques mentioned above offer good surgical visibility that eliminates the need for extensive temporal dissection. However, no aggressive approach was considered in the present case as the tooth has become accessible after extending the flap and carefully retracting the mucosal tissues and buccal fat pad. Therefore, it can be stated that the large volume of ITF has a significant effect on the severity of the surgery as the tooth can be displaced anywhere within this space.

Conclusion

Whether supernumerary or not, displacement of a tooth into the ITF is a rare but serious complication of the surgical extraction procedures performed in the maxilla. Early removal of the displaced tooth is essential to prevent major life-threatening complications which may occur due to subsequent odontogenic infection. The use of advanced imaging modalities such as CBCT is recommended to determine the localization of the displaced tooth in three dimensions to prevent the aggressive exploration of the soft tissues and to considerably shorten the time needed for surgery.

Ethics Committee Approval: Not required.

Informed Consent: Patient provided written informed consent.

Peer-review: Externally peer-reviewed.

Author Contributions: TY and AA designed the study. TY generated the data. TY, HO, and NE gathered the data. TY, HO, NE, and AA analyzed the data. TY wrote the majority of the original draft. All authors approved the final version of paper.

Conflict of Interest: No conflict of interest was declared by the authors.

Financial Disclosure: No financial support was declared by the authors.

Türkçe Öz: Çekim Sırasında Infratemporal Locaya Kaçan Bir Artı Dişin Çıkartılması. Gömülü bir dişin infratemporal locaya (ITL) kaçması nadir görülen, ancak bu alanı çevreleyen anatomik yapıların hassasiyeti nedeniyle ciddi bir komplikasyondur. Bu olgu bildirisinin amacı yüzünün sağ tarafında ağrı şikâyeti nedeniyle başvuran 40 yaşında bir erkek hastayı sunmaktır. Alınan panoramik radyografi ve konik ışıklı bilgisayarlı tomografide gömülü bir üçüncü büyük azı dişi ve bu dişin hemen üzerinde konumlanmış bir artı diş olduğu belirlenmiştir. Hasta lokal anestezi altında opere edilmiştir. Gömülü üçüncü büyük azı dişi kolayca çıkarılmış, ancak artı diş çekim sırasında ITL'nin içerisine doğru yer değiştirmiştir. Dişin konumu radyografik muayene ile tespit edildikten sonra, flep genişletilerek ve yumuşak dokuları dikkatle diseke edilerek dişe ulaşılmış ve diş aynı seansta ağız içinden çıkarılmıştır. Nadir görülen bu komplikasyonun klinik özellikleri görüntüleme yöntemlerinin güvenilirliği ve cerrahi teknikler üzerinde durularak incelenmiştir. Anahtar kelimeler: Infratemporal loca, artı diş, konik ışıklı bilgisayarlı tomografi, yer değiştirme, komplikasyon

References

1. Gulbrandsen SR, Jackson IT, Turlington EG. Recovery of a maxillary third molar from the infratemporal space via a hemicoronal approach. *J Oral Maxillofac Surg* 1987; 45: 279-82. [CrossRef]

2. Dawson K, MacMillan A, Wiesenfeld D. Removal of a maxillary third molar from the infratemporal fossa by a temporal approach and the aid of image-intensifying cineradiography. *J Oral Maxillofac Surg* 1993; 51: 1395-7. [\[CrossRef\]](#)
3. Sverzut CE, Trivellato AE, Sverzut AT, de Matos FP, Kato RB. Removal of a maxillary third molar accidentally displaced into the infratemporal fossa via intraoral approach under local anesthesia: Report of a case. *J Oral Maxillofac Surg* 2009; 67: 1316-20. [\[CrossRef\]](#)
4. Dimitrakopoulos I, Papadaki M. Displacement of a maxillary third molar into the infratemporal fossa: Case report. *Quintessence Int* 2007; 38: 607-10.
5. Grandini SA, Barros V, Salata LA, Rosa AL, Soares UN. Complications in exodontia—accidental dislodgment to adjacent anatomical areas. *Braz Dent J* 1993; 3: 103-12.
6. Kocaelli H, Balcioglu H, Erdem T. Displacement of a maxillary third molar into the buccal space: Anatomical implications apropos of a case. *Int J Oral Maxillofac Surg* 2011; 40: 650-3. [\[CrossRef\]](#)
7. Patel M, Down K. Accidental displacement of impacted maxillary third molars. *Br Dent J* 1994; 177: 57-9. [\[CrossRef\]](#)
8. Sverzut CE, Trivellato AE, Lopes LMdF, Ferraz EP, Sverzut AT. Accidental displacement of impacted maxillary third molar: A case report. *Braz Dent J* 2005; 16: 167-70. [\[CrossRef\]](#)
9. Oberman M, Horowitz I, Ramon Y. Accidental displacement of impacted maxillary third molars. *Int J Oral Maxillofac Surg* 1986; 15: 756-8. [\[CrossRef\]](#)
10. Durmus E, Dolanmaz D, Kucukkolbsi H, Mutlu N. Accidental displacement of impacted maxillary and mandibular third molars. *Quintessence Int* 2004; 35: 375-7.
11. Gómez-Oliveira G, Arribas-García I, Álvarez-Flores M, Gregoire-Ferriol J, Martínez-Gimeno C. Delayed removal of a maxillary third molar from the infratemporal fossa. *Med Oral Patol Oral Cir Bucal* 2010; 15: e509-11. [\[CrossRef\]](#)
12. Selvi F, Cakarer S, Keskin C, Ozyuvaci H. Delayed removal of a maxillary third molar accidentally displaced into the infratemporal fossa. *J Craniofac Surg* 2011; 22: 1391-3. [\[CrossRef\]](#)
13. Bodner L, Joshua BZ, Puterman MB. Removal of a maxillary third molar from the infratemporal fossa. *J Med Cases* 2012; 3: 97-9. [\[CrossRef\]](#)
14. Özer N, Üçem F, Saruhanoğlu A, Yilmaz S, Tanyeri H. Removal of a maxillary third molar displaced into pterygopalatine fossa via intraoral approach. *Case Rep Dent* 2013; 2013: 392148. [\[CrossRef\]](#)
15. Lang J. *Clinical anatomy of the masticatory apparatus peripharyngeal spaces*. Thieme, 1995.
16. Orr DL. A technique for recovery of a third molar from the infratemporal fossa: Case report. *J Oral Maxillofac Surg* 1999; 57: 1459-61. [\[CrossRef\]](#)
17. Bouquet A, Coudert JL, Bourgeois D, Mazoyer J-F, Bossard D. Contributions of reformatted computed tomography and panoramic radiography in the localization of third molars relative to the maxillary sinus. *Oral Surg Oral Med Oral Pathol Oral Radiol Endod* 2004; 98: 342-7. [\[CrossRef\]](#)
18. Pourmand PP, Sigron GR, Mache B, Stadlinger B, Locher MC. The most common complications after wisdom-tooth removal: Part 2: A retrospective study of 1,562 cases in the maxilla. *Swiss Dent J* 2014; 124: 1047-61.
19. Jung YH, Cho BH. Assessment of maxillary third molars with panoramic radiography and cone-beam computed tomography. *Imaging Sci Dent* 2015; 45: 233-40. [\[CrossRef\]](#)
20. Pohlenz P, Blessmann M, Blake F, Heinrich S, Schmelzle R, Heiland M. Clinical indications and perspectives for intraoperative cone-beam computed tomography in oral and maxillofacial surgery. *Oral Surg Oral Med Oral Pathol Oral Radiol Endod* 2007; 103: 412-7. [\[CrossRef\]](#)
21. Dawood A, Brown J, Sauret-Jackson V, Purkayastha S. Optimization of cone beam ct exposure for pre-surgical evaluation of the implant site. *Dentomaxillofac Radiol* 2014; 41: 70-4. [\[CrossRef\]](#)
22. Winkler T, Von Wowern N, Odont L, Bittmann S. Retrieval of an upper third molar from the infratemporal space. *J Oral Surg* 1977; 35: 130-2.
23. Bozkurt P, Erdem E. Management of upper and lower molars that are displaced into the neighbouring spaces. *Br J Oral Maxillofac Surg* 2017; 55: e49-52. [\[CrossRef\]](#)
24. Battisti A, Priore P, Giovannetti F, Barbera G, D'Alessandro F, Valentini V. Rare complication in third maxillary molar extraction: Dislocation in infratemporal fossa. *J Craniofac Surg* 2017; 28: 1784-5. [\[CrossRef\]](#)