

# A rare and incidental finding during colonoscopy: solitary polypoid ganglioneuroma: A case report

## Kolonoskopide nadir ve insidental bulgu: soliter polipoid ganglionörom: Olgu sunumu

Elif Usturalı Keskin<sup>1</sup>, Tufan Yılmaz<sup>1</sup>, Gürol Şen<sup>2</sup>

<sup>1</sup> Mustafakemalpaşa State Hospital,  
Department of Pathology, Bursa, Turkey  
<sup>2</sup> Mustafakemalpaşa State Hospital,  
Department of General Surgery, Bursa,  
Turkey

ORCID ID of the author(s)

EUK: 0000-0003-0656-2576

TY: 0000-0001-9834-583X

GS: 0000-0002-8897-5616

### Abstract

Ganglioneuromas (GNs) are benign, slow growing and well differentiated neuroectodermal neoplasias. They are derived from developing neuronal cells of the sympathetic nervous system. They occur mostly in children and are located in the posterior mediastinum, retroperitoneum. We present a case of incidental solitary polypoid ganglioneuroma of the colon. A 70 year old woman underwent colonoscopy for colon cancer screening. She has no abdominal or intestinal symptoms. In hepatic flexure of the colon a spherical polypoid lesion that was 1.4 cm in diameter was detected endoscopically. Biopsy was taken from the polyp. The histopathology revealed a biphasic polypoid tumor with ganglion cells and schwannian stroma on hematoxylin and eosin stain. Final histopathological diagnosis was polypoid ganglioneuroma of the colon. Ganglioneuromatous polyposis and diffuse ganglioneuromatosis are associated with several systemic syndromes. Solitary GNs are generally asymptomatic. Treatment of GNs depends on their size, location, and clinical findings such as bleeding or obstruction. Prognosis is usually excellent. Polypectomy is curative for polypoid GN. However the patients with ganglioneuromatous polyposis and diffuse form may need colectomy.

**Keywords:** Endoscopy, Ganglioneuroma, Colon polyp, Polypoid ganglioneuroma

### Öz

Ganglionöromlar (GNs) benign, yavaş büyüyen ve iyi diferansiye nöroektodermal neoplazilerdir. Sempatik sinir sisteminde gelişen nöronal hücrelerden köken alırlar. Çoğunlukla çocuklarda ve posterior mediasten, retroperiton yerleşimlidir. Kolonun insidental soliter polipoid ganglionöromu olgusunu sunduk. 70 yaşında kadın hastaya kanser taraması için kolonoskopi uygulandı. Abdominal ya da intestinal semptomu yoktu. Kolonoskopide kolon hepatik fleksurada 1.4 cm çaplı yuvarlak polipoid lezyon saptandı. Polipten biyopsi alındı. Hematoksilen eozin boyalı histopatolojik kesitlerde ganglion hücreleri ve schwannian stromadan oluşan bifazik polipoid tümör izlendi. Ganglionöromatoz polipozis ve diffüz ganglionöromatozis çeşitli sistemik sendromlarla ilişkilidir. Soliter ganglionöromlar genellikle asemptomatiktir. Ganglionöromlarda tedavi boyut, lokalizasyon, kanama ve obstrüksiyon gibi klinik bulgulara bağlıdır. Prognoz genellikle mükemmeldir. Polipoid GN da tedavi polipektomidir. Ganglionöromatoz polipozis ve diffüz formlardaki hastalara kolektomi gerekebilir.

**Anahtar kelimeler:** Endoskopi, Ganglionörom, Kolon polip, Polipoid ganglionörom

## Introduction

Ganglioneuromas (GNs) are benign, slow growing and well differentiated neuroectodermal neoplasia that does not contain immature elements. They are derived from developing neuronal cells of the sympathetic nervous system [1].

GNs are rarely found gastrointestinal tract and uncommon in the colon. They occur mostly in children and are located in the posterior mediastinum, retroperitoneum [2]. A review of published cases revealed that GNs have a predilection for the head, neck and or adrenal glands [3].

In this study we present a case of incidental solitary polypoid ganglioneuroma of the colon.

## Case presentation

A 70 year old woman underwent colonoscopy for colon cancer screening. She has no abdominal or intestinal symptoms and family history. On laboratory test hemoglobin was 10.2 g/dL, hematocrit was 33.3%. In hepatic flexure of the colon a spherical polypoid lesion that was 1.4 cm in diameter was detected endoscopically (Figure 1). Biopsy was taken from the polyp. Multiple diverticula were also found in different segments of the colon. The histopathology revealed a biphasic polypoid tumor with ganglion cells and schwannian stroma on hematoxylin and eosin stain (Figure 2). The ganglion cells were mature with prominent nucleoli. Final histopathological diagnosis was polypoid ganglioneuroma of the colon. Polypectomy of the lesion was planned and the patient was referred to another center for polypectomy. Informed consent was obtained from the patient due to this case report.

Corresponding author / Sorumlu yazar:

Elif Usturalı Keskin

Address / Adres: Mustafakemalpaşa Devlet Hastanesi, Patoloji Anabilim Dalı, Bursa, Türkiye  
e-Mail: drelikkeskin@gmail.com

Informed Consent: The author stated that the written consent was obtained from the patient presented in the study.

Hasta Onamı: Yazar çalışmada sunulan hastadan yazılı onam alındığını ifade etmiştir.

Conflict of Interest: No conflict of interest was declared by the authors.

Çıkar Çatışması: Yazarlar çıkar çatışması bildirmemişlerdir.

Financial Disclosure: The authors declared that this study has received no financial support.

Finansal Destek: Yazarlar bu çalışma için finansal destek almadıklarını beyan etmişlerdir.

Received / Geliş tarihi: 25.12.2018

Accepted / Kabul tarihi: 21.02.2019

Published / Yayın tarihi: 22.02.2019

Copyright © 2019 The Author(s)

Published by JOSAM

This is an open access article distributed under the terms of the Creative Commons Attribution-Non Commercial-NoDerivatives License 4.0 (CC BY-NC-ND 4.0) where it is permissible to download, share, remix, transform, and buildup the work provided it is properly cited. The work cannot be used commercially without permission from the journal.



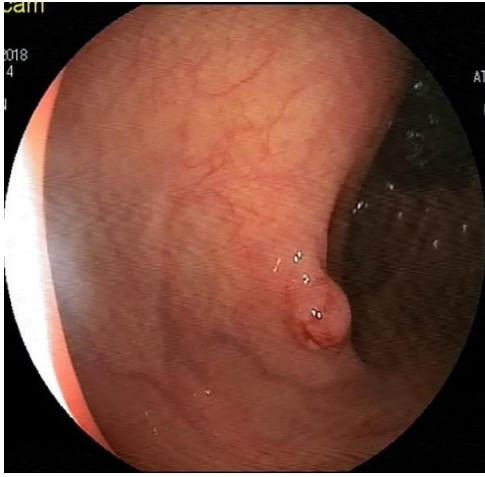


Figure 1: Endoscopic image of a sessile polyp with a diameter 1.4cm is observed in the colon

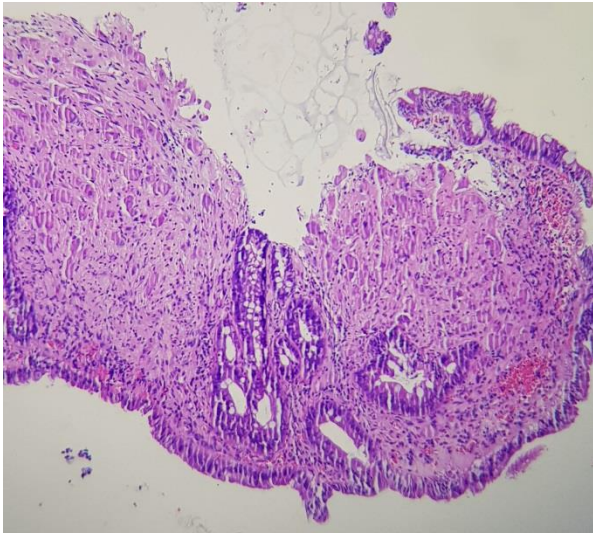


Figure 2: Hematoxylin and eosin stain of the ganglioneuroma. Ganglion cells and stromal cells are present in the lamina propria (magnification 4x)

## Discussion

GNs may arise anywhere along paravertebral sympathetic plexus. Common sites of origin are retroperitoneal, mediastinal, or cervical region [4]. GNs of the gastrointestinal tract are extremely rare [2]. They may confine to the mucosa and produce polypoid lesions [2].

Gastrointestinal GNs consist of 3 subgroups: 1) solitary polypoid GN, 2) ganglioneuromatous polyposis, 3) diffuse ganglioneuromatosis [5]. Polypoid GNs are often small and may be sessile or pedunculated [1]. Ganglioneuromatous polyposis usually has many polyps, often 20 or more [6]. Diffuse ganglioneuromatosis is nodular and diffuse tissue that is transmural or mucosal. These lesions cover the myenteric plexus and can be ranging up to 17cm [6]. Ganglioneuromatous polyposis and diffuse ganglioneuromatosis are associated with several systemic syndromes such as multiple endocrine neoplasia type IIB, neurofibromatosis type I, juvenile polyposis, tuberous sclerosis, and Cowden's syndrome [1,3]. Solitary GNs are generally asymptomatic [3]. The patients with ganglioneuromatous polyposis may have a family history of multiple intestinal polyps, adrenal myolipomas, and nodular goiter [2]. Our patient has no family or medical history.

Clinical presentation of GN is mostly asymptomatic [3]. They often lead to thickening of the bowel wall, submucosal nodularities and strictures. Patients can present with constipation,

obstruction, abdominal pain, weight loss, and bleeding [6]. Fifteen intestinal GNs cases were reported and only 4 cases presented with bleeding [6]. The patient in present case was asymptomatic but on laboratory tests blood counting was associated anemia. She was probably bleeding.

Although GNs usually develop in children they are often detected in adults because of slow growing [4]. They rarely observed over the age of 60 years [4]. Although mature GNs are generally hormonally inactive, they rarely produce catecholamine. The patients with hormone producing tumor may present with hypertension, diarrhea and flushing [4].

GNs are hamartomatous tumors derived from the autonomic nervous system. GNs are not differentiated from hyperplastic or adenomatous polyps endoscopically [1]. In these report a solitary polypoid GN was incidentally find out during endoscopy. Intestinal ganglioneuroma is always a microscopic diagnosis. The diagnosis can be made on routine hematoxylin and eosin stains. GNs are characterized by hyperplasia of ganglion cells, nerve fibers, and supporting cells of the enteric nervous system.

There is no specific treatment for GNs. It depends on their size, location, and clinical findings such as bleeding or obstruction [1]. Prognosis is usually excellent. Morbidity rate is very low in the mucosal variant [2]. A study of 28 patients with solitary GNs found that after 8 years follow up, none of the patients evolved complications [7]. Polypectomy is curative for polypoid GN. However the patients with ganglioneuromatous polyposis and diffuse form may need colectomy [1]. In our case polypectomy was planned.

Although there is no data on the association of polypoid GN and colon cancer, patients should be screened for associated genetic syndromes and for tumors in thyroid, colon, breast and uterus [6]. However some authors claim that it is unnecessary because of benign nature of polypoid GN [1].

## Conclusion

Solitary polypoid ganglioneuroma may lead to weight loss and bleeding, may be associated with systemic syndromes in multiple cases and should be kept in mind in the differential diagnosis of colon polyps.

## References

- Fiori E, Pozzessere C, Lamazza A, Leone G, Borrini F, Schillaci A, Mingazzini P. Endoscopic treatment of ganglioneuroma of the colon associated with a lipoma: a case report. *J Med Case Rep*. 2012 Sep 14;6:304. doi: 10.1186/1752-1947-6-304.
- Sayki Arslan M, Ekiz F, Yilmaz G, Coban S, Savas B, Ensari A, Ormeci N. Ganglioneuromatous polyposis of the colon in a patient with multiple adenomatous polyps. *Turk J Gastroenterol*. 2012;23(6):780-3.
- Ofori E, Ona M, Ramai D, Huang T, Xiao P, Reddy M. Colonic Ganglioneuroma: A Rare Finding during Colorectal Cancer Screening. *Case Rep Gastroenterol*. 2017 Aug 8;11(2):434-439. doi: 10.1159/000477716. eCollection 2017 May-Aug.
- Kumar S, Singh S, Chandna A. Organ Preservation in a Case of Retroperitoneal Ganglioneuroma: A Case Report and Review of Literature. *Case Rep Surg*. 2016;2016:6597374. doi: 10.1155/2016/6597374. Epub 2016 Sep 7.
- Matthews MA, Adler BH, Arnold MA, Kumar S, Carvalho R, Besner GE. Diffuse intestinal ganglioneuromatosis in a child. *J Pediatr Surg*. 2013 May;48(5):1129-33. doi: 10.1016/j.jpedsurg.2013.03.066.
- Abraham G, Prakash SR. Solitary Colonic Ganglioneuroma: A Rare Incidental Finding of Hematochezia. *Case Rep Gastrointest Med*. 2015;2015:794985. doi: 10.1155/2015/794985. Epub 2015 May 14.
- Shekitka KM, Sobin LH. Ganglioneuromas of the gastrointestinal tract. Relation to Von Recklinghausen disease and other multiple tumor syndromes. *Am J Surg Pathol*. 1994 Mar;18(3):250-7.