

# Dehydrated human amnion/chorion membrane allograft for preventing epidural fibrosis after laminectomy: an experimental rat model

Özhan Merzuk Uçkun<sup>1</sup>, Denizhan Divanhoğlu<sup>1</sup>, Rifat Akdağ<sup>2</sup>, Güner Menekşe<sup>3</sup>, Ali Dalgıç<sup>1</sup>, Ahmet Deniz Belen<sup>1</sup>

<sup>1</sup>Department of Neurosurgery, University of Health Sciences, Ankara Numune Training and Research Hospital, Ankara, Turkey

<sup>2</sup>Department of Neurosurgery, University of Health Sciences, Bursa Yüksek İhtisas Training and Research Hospital, Bursa, Turkey

<sup>3</sup>Department of Neurosurgery, University of Health Sciences, Ankara Training and Research Hospital, Ankara, Turkey

## ABSTRACT

**Objectives:** Post-laminectomy syndrome due to epidural fibrosis (EF) is a common cause of persistent low back pain after lumbar spinal surgery and is challenging for both surgeons and patients. The current experimental study aimed to investigate the effect of dehydrated human amnion/chorion membrane (dHACM) allograft for preventing EF formation following lumbar laminectomy.

**Methods:** Sixteen Sprague–Dawley rats equally divided into two groups underwent lumbar laminectomy. Group A, the control group, underwent lumbar laminectomy with standard closure. Group B, the experimental group, additionally received epidural dHACM allografts during the procedure. After 45 days of follow-up, the rats were sacrificed, and the harvested tissues were histopathologically evaluated for EF.

**Results:** Compared with Group A, Group B showed significantly less EF generation ( $p < 0.001$ ), implying that dHACM allografts effectively prevent EF.

**Conclusions:** This study demonstrated that dHACM can effectively reduce EF formation after spinal laminectomy in rats.

**Keywords:** Epidural fibrosis, laminectomy, amnion membrane allograft

Failed back surgery syndrome (FBSS) is characterized by refractory back pain with or without lower extremity involvement, occurring after 5%-40% of lumbar disc surgeries [1-3]. Many factors, including inadequate surgical decompression, recurrent disc herniation, epidural fibrosis (EF), and spinal instability, contribute to the risk of FBSS. Of these known factors, EF occurs in 24% of patients with lumbar disc herniation, making it the most common cause of post-laminectomy syndrome [4]. Currently, there exists no known method with proven efficacy for reducing EF

after its formation in such cases. Although wide epidural adhesions can be cleared and compressed nerve roots can be relaxed by a secondary surgery, adhesions may recur [5]. As a result, methods involving materials such as free and pedicled oiled grafts, synthetic membranes, fibrin foam, gelatin, and dextran sulfate blends (implants containing adcon-I materials) have been explored for preventing EF formation [6-9]. Human amniotic membrane (HAM) is one of promising materials for preventing EF. EF formation after lumbar laminectomy is a multistage process involving

Received: February 7, 2019; Accepted: March 20, 2019; Published Online: March 21, 2019



**How to cite this article:** Uçkun ÖM, Divanhoğlu D, Akdağ R, Menekşe G, Dalgıç A, Belen AD. Dehydrated human amnion/chorion membrane allograft for preventing epidural fibrosis after laminectomy: an experimental rat model. *Eur Res J* 2020;6(6):534-538. DOI: 10.18621/eurj.523854

**Address for correspondence:** Özhan Merzuk Uçkun, MD., University of Health Sciences, Ankara Numune Training and Research Hospital, Department of Neurosurgery, Ankara, Turkey. E-mail: ozhanmerzuk@gmail.com

©Copyright 2020 by The Association of Health Research & Strategy  
Available at <http://dergipark.org.tr/eurj>

the accumulation of extracellular matrix components such as collagen, fibronectin, and dermatan sulfate and the reduction of tissue cells [10]. HAM allografts may prevent this process by inhibiting vascularization and apoptosis in epithelial cells along with reducing inflammation [11, 12]. Various methods for processing HAM allografts have been developed, but their usage is associated with challenges such as damaged collagen construction, residual chemical agents, and blood-borne pathogen infections [13]. Recently, an allograft composed of dehydrated human amnion/chorion membrane (dHACM) (AmnioFix, MiMedx, Marietta, GA), which was processed gently for preserving the collagen matrix and its biological activities, was introduced in clinic practice [14]. The current study aimed to investigate if the dHACM is effective for preventing EF formation after experimental lumbar laminectomy.

## METHODS

Sixteen adult, male Sprague-Dawley rats weighing between 300 and 350 grams were included in the study. All animals were housed in a suitable animal-care facility under veterinary supervision. During the experiment, until sacrifice, all of the subjects were followed in a good state of health without any complications such as wound, infection, hematoma, and cerebrospinal fluid fistula development. All experiments were approved by the Animal Experiments Ethics Committee. Sixteen subjects were equally distributed into two groups: Group A, control group, underwent lumbar laminectomy and Group B, treatment group, received epidural dHACM allografts following lumbar laminectomy. Prior to surgery, general anesthesia with intraperitoneal 60-mg/kg ketamine hydrochloride (Ketalar; Eczacıbaşı, Turkey) and 5-mg/kg xylazine (Rompun; Bayer, Turkey) was administered.

### Surgical Technique

Thoracolumbar regions of the subjects were prepared, and the operation site was disinfected using iodine solution. A midline incision between T11 and sacrum was performed. Subsequent paraspinal muscle dissection was followed by T12 to L4 total laminectomies. Adequate care was taken during the entire procedure to protect the spinal cord.

For the subjects in Group A, a standard closure was performed using 0/3 silk sutures for the thoracolumbar fascia and 0/3 prolene for skin. For the subjects in Group B, epidural dHACM allografts were placed before performing the same standard closure.

All animals were housed in a stress-free animal-care facility at room temperature ( $25 \pm 1$  °C) with ad libitum access to food and water for 45 days until sacrifice using high dose ketamine hydrochloride.

### Histopathologic Evaluation

Obtained tissue blocks of muscle, bone, epidural space, and spinal cord structures were sampled and fixed in formalin for histological examination. These samples were then immersed in 10% EDTA for decalcification. To investigate the presence of scar tissue and for microscopic examination, the blocks were stained with hematoxylin-eosin (HE) and Masson's trichrome.

The grade of EF formation was evaluated by a blinded pathologist in accordance with the model recommended by He *et al.* [15] (Table 1). Fig. 1 shows thin fibrous attachments between the dura mater and scar tissue (grade 1). The samples shown in Figs. 2 and 3 demonstrate fibrosis of grade 2 and 3, respectively.

### Statistical Analysis

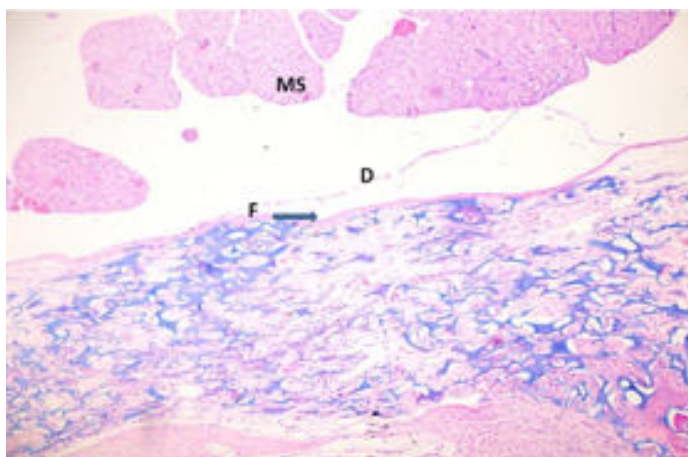
Data were presented as mean  $\pm$  standard deviation. Differences in histological findings among the two groups were evaluated using the Mann-Whitney U test. The level of statistical significance was set at  $p < 0.05$ .

## RESULTS

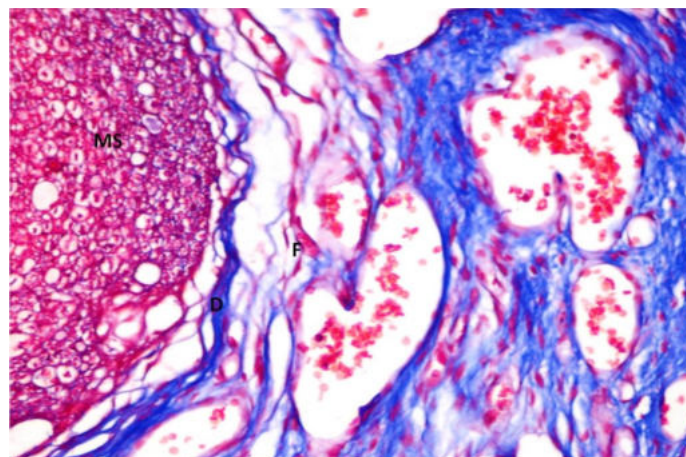
The mean histopathological grade of EF was 2.87

**Table 1. Grading extent of fibrous tissue**

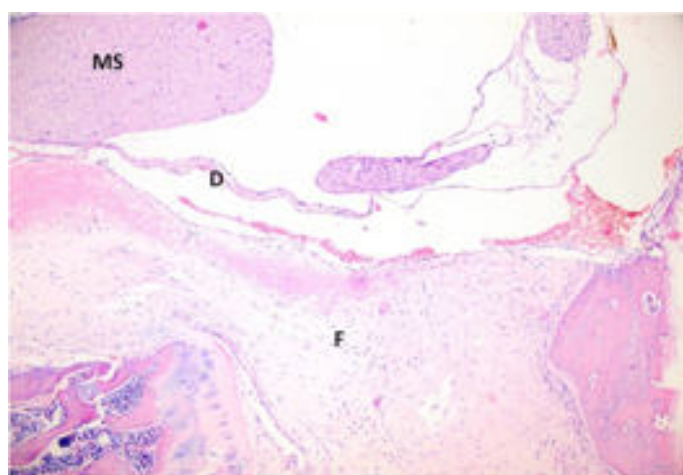
Grade 0	No fibrosis on the dura mater
Grade 1	Thin fibrous bands between the dura mater and scar tissue
Grade 2	Fibrosis forms over less than two thirds of the laminectomy defect
Grade 3	Fibrosis extends over two thirds of the laminectomy defect or to the nerve root



**Fig. 1.** An example of the thin fibrous attachments between the dura mater and scar tissue (grade 1). [HE ×100] MS: Medulla spinalis, D: Dura mater, F: Fibrosis



**Fig. 2.** An example of fibrosis covering less than 2/3 of the laminectomy defect (grade 2). [Masson's trichrome (MT), ×200]



**Fig. 3.** An example of fibrosis covering more than 2/3 of the laminectomy defect (grade 3). [HE, ×300]

**Table 2. Grades of epidural fibrosis among the groups**

	Specification	Mean ± SD	Median	Minimum–Maximum	p value
Group A	Control (laminectomy)	2.87 ± 0.35	3.00	(2.0-3.0)	< 0.001**
Group B	dHACM graft (Laminectomy + Graft)	1.62 ± 0.51	2.00	(1.0-2.0)	

SD = Standard deviation, dHACM = Dehydrated human amnion/chorion membrane, The Mann-Whitney U test was used to compare values between groups. \*\**p* < 0.01.

± 0.35 in Group A and 1.62 ± 0.34 in Group B (Table 2). The difference between the two groups was statistically significant (*p* < 0.001), indicating that EF formation was greater in the control group than in the dHACM allograft group. The dHACM graft was thus found to decrease EF formation significantly.

## DISCUSSION

Epidural fibrosis around nerve roots and the dura mater at the post-laminectomy site is an important cause of FBSS, which causes considerable morbidity in approximately 40% of patients that undergo spinal

surgery and has high health care costs. As EF cannot be effectively treated after its formation, the key is to prevent the migration of fibroblasts to the dura in the early recovery stage after spinal surgery. Thus, the placement of a physical barrier to restrict cell migration may be an effective approach for reducing the incidence of EF. Although various biological and synthetic materials have been tried to prevent EF, this issue has not been fully elucidated [5-9].

HAM dressings are reported to have beneficial effects on tissue reparation and regeneration due to their anti-inflammatory, re-epithelialization, anti-scarring, antibacterial, and analgesic activities. In addition to containing many growth factors, anti-vasculogenic factors, and anti-inflammatory cytokines, HAMs have low immunogenicity. HAMs have been extensively employed in medical fields such as ophthalmology and for treating conditions such as bone defects, skin burns, and bladder or oral cavity reconstruction [16, 17]. However, fresh amniotic membrane carries a risk of disease transmission. Thus, processing methods such as glycerol treatment, irradiation, lyophilization, or cryopreservation are required. However, these methods may damage collagen construction or leave

behind residual chemical agents. Therefore, processing methods that protect the biological efficacy of HAMs while providing safety are important [18]. Recently, a method involving mild cleansing and dehydration was used to protect and retain the biological activities of the natural amnion [14]. In this study, the potential of dHACM processed using this method to function as a barrier for preventing EF after laminectomy was assessed. Indeed, the findings of this study support that dHACM can significantly reduce EF formation.

Previous studies, mostly experimental, on the effects of HAM on EF formation following spinal surgery are summarized in Table 3 and favorable outcomes were noted [5, 19-21]. Till date, only one case series by Subach *et al.* [20] has reported the use of dHACM. They reported that dHACM during transforaminal lumbar interbody lumbar fusion (TLIF) can positively prevent EF formation and simplify dissection in secondary surgery.

### CONCLUSION

In conclusion, the present study found that

**Table 3. Previous studies investigating the effect of HAM on epidural fibrosis formation after spinal surgeries**

Authors (Year)	Study Design	Product Type	Study Subjects	Results
Tao <i>et al.</i> [5] (2009)	Animal model (dog)	FAM CAM AFF	24 dogs	CAM effectively reduced epidural fibrosis
Choi <i>et al.</i> [19] (2011)	Animal model (rat)	Irradiated FAM	20 rats	Irradiated FAM effectively reduced epidural fibrosis
Subach <i>et al.</i> [20] (2015)	Human case series	dHACM	5 patients	dHACM implant during TLIF had favorable results on epidural fibrosis formation
Kara <i>et al.</i> [21] (2015)	Animal model (rat)	Fresh HAM Human Amniotic fluid	27 rats	Fresh HAM and human amniotic fluid were found to have favorable results for preventing epidural fibrosis but not significantly

FAM = Freeze dried amniotic membrane, CAM = Cross-linked amniotic membrane, AFF = Autologous free fat, TLIF = Transforaminal lumbar interbody lumbar fusion, dHACM = Dehydrated human amnion/chorion membrane, HAM = Human amniotic membrane

dHACM can effectively reduce EF formation after spinal laminectomy. In our knowledge, this is the first study demonstrating reduction epidural fibrosis following laminectomy in a small animal study via dHACM graft. Further studies are needed to verify these findings. Future studies should also compare the efficacy and complications of different HAM types.

### Conflict of interest

The author disclosed no conflict of interest during the preparation or publication of this manuscript.

### Financing

The author disclosed that they did not receive any grant during conduction or writing of this study.

## REFERENCES

- Burton CV, Kirkaldy-Willis WH, Yong-Hing K, Heithoff KB. Causes of failure of surgery on the lumbar spine. *Clin Orthop Relat Res* 1981;191-9.
- Fager CA, Freidberg SR. Analysis of failures and poor results of lumbar spine surgery. *Spine (Phila Pa 1976)* 1980;5:87-94.
- North RB, Campbell JN, James CS, Conover-Walker MK, Wang H, Piantadosi S, et al. Failed back surgery syndrome: 5-year follow-up in 102 patients undergoing repeated operation. *Neurosurgery* 1991;28:685-90; discussion 690-81.
- Ross JS, Robertson JT, Frederickson RC, Petrie JL, Obuchowski N, Modic MT, et al. Association between peridural scar and recurrent radicular pain after lumbar discectomy: magnetic resonance evaluation. *ADCON-L European Study Group. Neurosurgery* 1996;38:855-61; discussion 861-53.
- Tao H, Fan H. Implantation of amniotic membrane to reduce postlaminectomy epidural adhesions. *Eur Spine J* 2009;18:1202-12.
- Einhaus SL, Robertson JT, Dohan FC, Jr, Wujek JR, Ahmad S. Reduction of peridural fibrosis after lumbar laminotomy and discectomy in dogs by a resorbable gel (ADCON-L). *Spine* 1997;22:1440-6; discussion 1446-7.
- Gill GG, Scheck M, Kelley ET, Rodrigo JJ. Pedicle fat grafts for the prevention of scar in low-back surgery. *Spine* 1985;10:662-7.
- Robertson JT, Meric AL, Dohan FC, Jr, Schweitzer JB, Wujek JR, Ahmad S. The reduction of postlaminectomy peridural fibrosis in rabbits by a carbohydrate polymer. *J Neurosurg* 1993;79:89-95.
- Wujek JR, Ahmad S, Harel A, Maier KH, Roufa D, Silver J. A carbohydrate polymer that effectively prevents epidural fibrosis at laminectomy sites in the rat. *Exp Neurol* 1991;114:237-45.
- Laurent GJ, Chambers RC, Hill MR, McAnulty RJ. Regulation of matrix turnover: fibroblasts, forces, factors and fibrosis. *Biochem Soc Trans* 2007;35:647-51.
- Boudreau N, Werb Z, Bissell MJ. Suppression of apoptosis by basement membrane requires three-dimensional tissue organization and withdrawal from the cell cycle. *Proc Natl Acad Sci U S A* 1996;93:3509-13.
- Dua HS, Azuara-Blanco A. Amniotic membrane transplantation. *Br J Ophthalmol* 1999;83:748-52.
- von Versen-Höynck F, Syring C, Bachmann S, Möller DE. The influence of different preservation and sterilisation steps on the histological properties of amnion allografts--light and scanning electron microscopic studies. *Cell Tissue Bank* 2004;5:45-56.
- Koob TJ, Rennert R, Zabek N, Masee M, Lim JJ, Temenoff JS, et al. Biological properties of dehydrated human amnion/chorion composite graft: implications for chronic wound healing. *Int Wound J* 2013;10:493-500.
- He Y, Revel M, Loty B. A quantitative model of post-laminectomy scar formation. Effects of a nonsteroidal anti-inflammatory drug. *Spine Phila Pa* 1976 1995;20:557-63; discussion 579-80.
- Sant'Anna LB, Brito FS, Barja PR, Nicodemo MC. Long-term effects of human amniotic membrane in a rat model of biliary fibrosis. *Braz J Med Biol Res* 2017;50:e5692.
- Dobran, M., D. Brancorsini, M. D. Costanza, V. Liverotti, F. Mancini, D. Nasi, M. Iacoangeli, and M. Scerrati: Epidural scarring after lumbar disc surgery: Equivalent scarring with/without free autologous fat grafts. *Surg Neurol Int* 2017;8:169.
- Adds PJ, Hunt CJ, Dart JK. Amniotic membrane grafts, "fresh" or frozen? A clinical and in vitro comparison. *Br J Ophthalmol* 2001;85:905-7.
- Choi HJ, Kim KB, Kwon YM. Effect of amniotic membrane to reduce postlaminectomy epidural adhesion on a rat model. *J Korean Neurosurg Soc* 2011;49:323-8.
- Subach BR, Copay AG. The use of a dehydrated amnion/chorion membrane allograft in patients who subsequently undergo reexploration after posterior lumbar instrumentation. *Adv Orthop* 2015;2015:501202.
- Kara D, Senol N, Kapucuoglu FN, Tureyen K. Effectiveness of human amniotic fluid and amniotic membrane in preventing spinal epidural fibrosis in an experimental rat model. *J Neurol Sci* 2015;32:293-302.



This is an open access article distributed under the terms of Creative Commons Attribution-NonCommercial-NoDerivatives 4.0 International License.