

Primary Extradural Extraosseous Ewing's Sarcoma of The Thoracic Spinal Canal: A Case Report

Alparslan Serarslan*, Bilge Gürsel, Deniz Meydan, İbrahim Kartal, Seda Gün, Meltem Ceyhan, Nilgün Özbek Okumuş

DOI: <https://doi.org/10.17944/mkutfd.329118>

Alparslan Serarslan*: Asst. Prof. Dr., Ondokuz Mayıs University Faculty of Medicine Department of Radiation Oncology, Samsun
Email: alparslanserarslan@hotmail.com
ORCID id: <https://orcid.org/0000-0001-5985-2484>

Bilge Gürsel: Assoc. Prof. Dr., Ondokuz Mayıs University Faculty of Medicine Department of Radiation Oncology, Samsun
Email: bgurssel@omu.edu.tr
ORCID id: <https://orcid.org/0000-0002-3109-7146>

Deniz Meydan: Assoc. Prof. Dr., Ondokuz Mayıs University Faculty of Medicine Department of Radiation Oncology, Samsun
Email: admeydan@omu.edu.tr
ORCID id: <https://orcid.org/0000-0003-3518-3567>

İbrahim Kartal: MD. Spec., Ondokuz Mayıs University Faculty of Medicine Department of Pediatrics, Samsun
Email: ibrahim_kartal28@hotmail.com
ORCID id: <https://orcid.org/0000-0002-2772-9956>

Seda Gün: Asst. Prof. Dr., Ondokuz Mayıs University Faculty of Medicine Department of Pathology, Samsun
Email: sakifgun@yahoo.com
ORCID id: <https://orcid.org/0000-0002-6652-4582>

Meltem Ceyhan: Assoc. Prof. Dr., Ondokuz Mayıs University Faculty of Medicine Department of Radiology, Samsun
Email: drmceyhan@hotmail.com
ORCID id: <https://orcid.org/0000-0002-0133-0234>

Nilgün Özbek Okumuş: Prof. Dr., Ondokuz Mayıs University Faculty of Medicine Department of Radiation Oncology, Samsun
Email: nozbeokumus@yahoo.com
ORCID id: <https://orcid.org/0000-0001-8338-3980>

Bildirimler/Acknowledgement

Yazarlar bu makale ile ilgili herhangi bir çıkar çatışması bildirmemişlerdir.
The authors declare that they have no conflict of interests regarding content of this article.
Yazarlar bu makale ile ilgili herhangi bir finansal destek bildirmemişlerdir.
The Authors report no financial support regarding content of this article.

Geliş/Received: 17.07.2017
Kabul/Accepted: 05.03.2019

e-ISSN: 2149-3103
Web: <http://dergipark.gov.tr/mkutfd>

Öz

Primer spinal ekstradural Ewing sarkomu

Ewing sarkom sıklıkla kemikte gelişir ve ekstradural spinal kanalda oldukça nadirdir. Burada, sağ alt ekstremitede güç kaybı şikâyeti ile başvuran 6 yaşında bir kız çocuğunun klinik seyri, tanısı ve tedavisini sunuyoruz. Manyetik rezonans görüntülemesinde T2'den T5'e kadar uzanan ekstradural spinal kanal tümörü mevcuttu. Laminektomi yapıldı. Histopatolojik, immünohistokimyasal ve moleküler sitogenetik incelemeler Ewing sarkom ile uyumluydu. Ameliyat sonrasında yapılan evreleme çalışmalarında herhangi bir malign odak saptanmadı. Postoperatif radyoterapi ve kemoterapi uygulandı. Bu çalışmada, spinal kanalın primer ekstradural ekstraosseöz Ewing sarkom, güncel literatür ışığında kısaca tartışılmıştır.

Anahtar kelimeler: Adjuvant radyoterapi, Ewing sarkom, ekstramedüller spinal kord kompresyonu, kemoterapi, spinal kanal.

Abstract

Primary spinal extradural Ewing's sarcoma

Ewing's sarcoma most commonly occurs in bone and only very rarely in the extradural spinal canal. Herein, we present the clinical course, diagnosis, and treatment of a 6-year-old girl admitted with a complaint of strength loss in her right lower extremity. Magnetic resonance imaging revealed an extradural spinal canal tumor extending from level T2 to T5; she underwent laminectomy. The histopathological, immunohistochemical, and molecular cytogenetic data were compatible with Ewing's sarcoma. We detected no malignant focus on postoperative staging work-up and prescribed postoperative radiotherapy and chemotherapy. A brief review of the literature on primary extradural extraosseous Ewing's sarcoma of the spinal canal is presented.

Keywords: Adjuvant radiotherapy, chemotherapy, Ewing's sarcoma, extramedullary spinal cord compression, spinal canal.

INTRODUCTION

Ewing's sarcoma (ES) is the most common malignant bone tumor in children under 10 years of age with an annual incidence of approximately three cases per million children. ES is divided into osseous and extraosseous subtypes, of which the former is more common (85% vs. 15%). Extraosseous Ewing's sarcoma (EES) commonly arises from the chest wall, paravertebral muscles, extremities, buttocks, and the retroperitoneal space, but only extremely rarely from the spinal extradural space (1, 2).

We present our case report to provide a better understanding of primary extradural EES.

CASE

A 6-year-old girl presented with a complaint of strength loss in her right lower extremity. Anamnesis revealed a 1-week history of back pain. On physical examination, the right thigh and leg muscle powers were at approximately level 3 of 5. Also, the ipsilateral deep tendon reflexes (DTRs) were increased and the Babinski sign was positive. Laboratory test data were within the normal ranges. Craniospinal magnetic resonance imaging (MRI) revealed a posteriorly located extradural/extramedullary soft-tissue lesion extending from level T2 to T5, with bilateral foraminal widening associated with spinal cord compression. The lesion was hypointense on T1, but hyperintense on T2-weighted images, compared with the spinal cord (Figure 1). We scheduled surgery. However, the left lower extremity weakness progressed rapidly to paraplegia. A repeat physical examination revealed that the powers of the muscles of both lower extremities were at level 1 and anesthesia had developed below the T4 dermatome. The bilateral

DTRs had increased and both Babinski signs were positive. We performed urgent T2–T5 laminectomy and gross/total resection. During surgery, an extradural tumor exhibiting bilateral foraminal widening was found on the posterior aspect of the spinal cord.

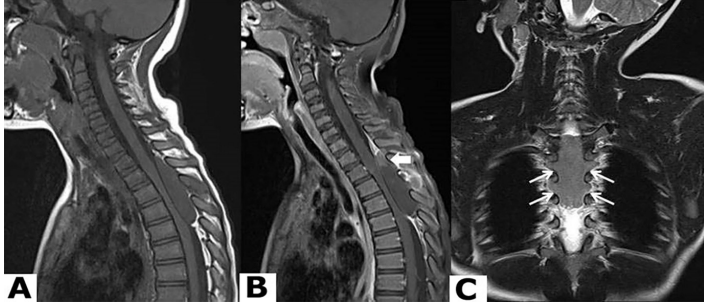


Figure 1. Cranio-spinal magnetic resonance imaging data. (A) A T1-weighted sagittal section. (B) A contrast-enhanced T1-weighted sagittal section. (C) A T2-weighted coronal section.

Histopathologically, hematoxylin/eosin staining revealed the proliferation of small, blue, variable round cells with hyperchromatic nuclei and scant cytoplasm. Immunohistochemically, the tumor cells were positive for CD99 and FLI-1, but negative for the leucocyte common antigen (LCA or CD45) and cytokeratin. The Ki-67 proliferation index was 20%. Based on these findings, we diagnosed EES (Figure 2). We performed molecular cytogenetic analysis using fluorescence in-situ hybridization (FISH) to assess EWS gene status. We found the translocation $t(11; 22)(q24; q12)$ in tumor cells.

Postoperatively, MRI revealed decompression of the spinal cord and no evidence of disease in the epidural space. However, the bilateral lower extremity weakness did not resolve, and paraplegia developed. On staging work-up, neither positron emission tomography nor computed tomography detected any malignant focus. Following surgery, we prescribed local radiotherapy (RT; 45 Gy in 25 fractions) and six courses of CEVAIE (carboplatin, 500 mg/m²; epirubicin, 150 mg/m²; vincristin, 1.5 mg/m²; actinomycin D, 1.5 mg/m²; ifosfamide, 3 g/m²; and etoposide, 150 mg/m²) chemotherapy (ChT) protocol. At the 12-month follow-up the patient showed no clinical or radiological evidence of recurrent or metastatic disease. Unfortunately, the paraplegia did not resolve.

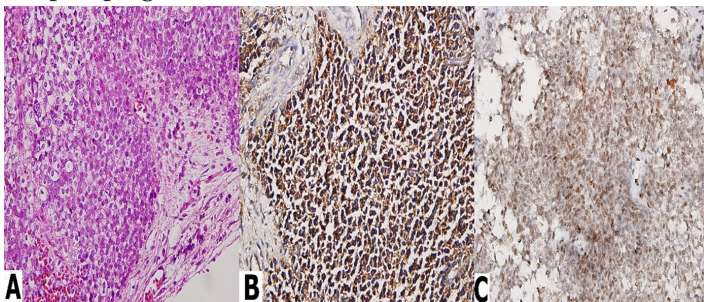


Figure 2. Microscopic images. (A) Hematoxylin-eosin staining ($\times 400$). (B) CD99 immunostaining ($\times 400$). (C) FLI-1 immunostaining ($\times 400$).

DISCUSSION

Primary spinal extradural EES is extremely rare. In the few case reports in the literature, the mean age at the time of EES diagnosis was 18.8–22.9 years and was more common in males (66%). The most common symptoms were non-specific, depending on the level of the tumor, and included back and/or radicular pain, paresis, sensory disturbance, and sphincter dysfunction. The mean time between the appearance of the first symptom and diagnosis was 4.5 months. Primary extradural EES of the spinal canal in the lumbar region was twice as common as EES in the cervical and thoracic regions (1, 3-5). MRI should be performed as soon as possible when a patient presents with neurological symptoms. However, the appearance on MRI of a primary spinal extradural EES is indistinguishable from those of other tumors (6). The gold standard diagnostic method is histopathology (1).

Histopathologically, EES is classified into the small-round-blue cell tumor group, reflecting the microscopic appearance of the tumor cells. It is essential to differentially diagnose EES from other small-blue-round cell tumors such as non-Hodgkin's lymphoma, synovial sarcoma, rhabdomyosarcoma, and small cell carcinoma of the lung (3, 7). The World Health Organization has assigned EES a grade of 4. The translocation $t(11; 22)(q24; q12)$ and CD99 expression are characteristic of ES, being evident in >90% of all cases. Thus, molecular cytogenetic and immunohistochemical studies are essential (2, 4, 5).

The primary treatment is surgery, which aims to both diagnose the disease and completely remove the tumor, with safe surgical margins (5, 8). In patients without neurological deficits, pre-operative biopsy followed by ChT increases the prospects of total excision because they cause the tumor to shrink (1, 2, 8). Postoperative ChT and RT have been reported to improve local control and survival even in those with poor prognostic factors (4, 7). The most commonly used chemotherapeutic agents are vincristine, doxorubicin, cyclophosphamide, ifosfamide, and actinomycin D. Local irradiation (3,000–5,600 cGy) has been suggested (5, 8).

The prognostic factors (good vs. poor, respectively) are age (young vs. old), tumor location (cervical vs. lumbosacral), resection type (complete = R0 resection vs. incomplete = R1/R2 resection), stage (non-metastatic vs. metastatic), serum lactate dehydrogenase level (non-elevated vs. elevated), surgery (yes vs. no), and ChT and RT (yes vs. no). Distant metastases develop in 38% of all patients, who can be divided into groups with central nervous system (CNS) involvement and extra-CNS groups. Extra-CNS metastases develop in >80% of all patients. The most common metastatic sites are the lungs and the skeletal system, in that order. The 5-year overall survival rate of patients with primary spinal EES is 0–37.5% (1-5, 8, 9).

In conclusion, primary spinal extradural EES is extremely rare in children. The symptoms and radiological findings are non-specific. Histopathological, immunohistochemical, and molecular cytogenetic analyses are the diagnostic gold standards. Neurological status (symptomatic vs. asymptomatic) is important when deciding how to sequence the treatment modalities. However, regardless of the sequencing chosen, all patients with primary spinal canal extradural EES should be treated with a combination of surgery, ChT, and RT.

References

- Holland MT, Flouty OE, Close LN, Reddy CG, Howard MA 3rd. A Unique Case of Primary Ewing's Sarcoma of the Cervical Spine in a 53-Year-Old Male: A Case Report and Review of the Literature. *Case Rep Med* 2015; 2015: 402313.
- Kannan KK, Sundarapandian RJ, Surulivel VJ. Unusual Presentation of a Primary Ewing's Sarcoma of the Spine with Paraplegia: A Case Report. *J Clin Diagn Res* 2015; 9: RD01-3.
- Yasuda T, Suzuki K, Kanamori M, Hori T, Huang D, Bridge J A, et al. Extraskelatal Ewing's sarcoma of the thoracic epidural space: case report and review of the literature. *Oncology reports* 2011; 26: 711-5.
- Saeedinia S, Nouri M, Alimohammadi M, Moradi H, Amirjamshidi A. Primary spinal extradural Ewing's sarcoma (primitive neuroectodermal tumor): Report of a case and meta-analysis of the reported cases in the literature. *Surg Neurol Int* 2012; 3: 55.
- Kazancı A, Gurcan O, Gurcay AG, Senturk S, Yıldırım AE, Kılıcaslan A, et al. Primary ewing sarcoma in spinal epidural space: report of three cases and review of the literature. *Journal of Neurological Sciences (Turkish)* 2015; 32: 250-61.
- Tsutsumi S, Yasumoto Y, Manabe A, Ogino I, Arai H, Ito M. Magnetic resonance imaging appearance of primary spinal extradural Ewing's sarcoma: case report and literature review. *Clin Neuroradiol* 2013; 23: 81-5.
- Sarı Neriman; Cetundag Mehmet F; İlhan İnci E. Treatment of Extraosseous Ewing Sarcoma in Children: Single Center Experience. *UHOD* 2009; 19: 147-52.
- Zhu Q, Zhang J, Xiao J. Primary dumbbell-shaped Ewing's sarcoma of the cervical vertebra in adults: Four case reports and literature review. *Oncol Lett* 2012; 3: 721-5.
- Giner J, Isla A, Cubedo R, Tejerina E. Primary Epidural Lumbar Ewing Sarcoma: Case Report and Review of the Literature. *Spine (Phila Pa 1976)* 2016; 41: E375-8.