

ORIGINAL
ARTICLE

- Mine Geçgelen Cesur¹**
Tuna Onal²
Mehmet Dincer Bilgin³
Fevziye Burcu Sirin⁴
Sevinc Inan⁵
Ergun Cem Koken³
Afra Alkan⁶
Gokhan Cesur⁷

¹Department of Orthodontics, Faculty of Dentistry, Adnan Menderes University, Aydın, Turkey.

²Department of Histology and Embryology, Faculty of Medicine, Celal Bayar University, Manisa, Turkey.

³Department of Biophysics, Faculty of Medicine, Adnan Menderes University, Aydın, Turkey.

⁴Department of Biochemistry, Faculty of Medicine, Suleyman Demirel University, Isparta, Turkey.

⁵Department of Histology and Embryology, Faculty of Medicine, İzmir Ekonomi University, İzmir, Turkey.

⁶Department of Biostatistics, Faculty of Medicine, Yıldırım Beyazıt University, Ankara, Turkey.

⁷Department of Physiology, Faculty of Medicine, Adnan Menderes University, Aydın, Turkey.

Corresponding Author:

Mine Geçgelen Cesur
 Adnan Menderes University, Faculty of Dentistry, Department of Orthodontics
 Aydın/Turkey
 Tel: +90 5447490199
 E-mail: minegecgelen@hotmail.com

Received: 09.01.2019

Acceptance: 11.03.2019

DOI: 10.18521/ktd.510808

Konuralp Medical Journal

e-ISSN 1309-3878

konuralptipdergi@duzce.edu.tr

konuralptipdergisi@gmail.com

www.konuralptipdergi.duzce.edu.tr

Histological and Biochemical Investigation of the Effects of Low Intensity Pulsed Ultrasound on Orthodontic Tooth Movement

ABSTRACT

Objective: The goal of our study is to assess the effects of low intensity pulsed ultrasound on orthodontic tooth movement in rats.

Methods: For this study, 40 adult male Wistar albino rats (12-weeks old age) were used from the Animal Laboratory at Adnan Menderes University. Rats were divided into four groups each of ten. Group 1 was the untreated as a control. In group 2, an orthodontic spring was used to move teeth. For groups 3 and 4, orthodontic treatment was combined with low intensity pulsed ultrasound at 16 J/cm² or 48 J/cm² for 14 days, respectively. Tooth movement was measured at the last day of treatment. Serum bone alkaline phosphatase (BALP) and C-telopeptide type I collagen (CTX-I) levels were analyzed biochemically. The number of osteoclasts, osteoblasts and inflammatory cells, capillary density and new bone formation was determined histologically. Receptor activator of nuclear factor-kappa B ligand (RANKL), osteoprotegerin (OPG), vascular endothelial growth factor (VEGF) and transforming growth factor- β (TGF- β) were assessed using immunohistochemical staining.

Results: BALP and CTX-I levels in group 4 were significantly higher compared to control ($p < 0.05$). Tooth movement and the number of osteoclasts, inflammatory cells and capillary density in group 4 were significantly greater than group 2 ($p < 0.05$). The intensity levels of RANKL and OPG in group 4 were significantly greater than group 2 ($p < 0.05$).

Conclusions: Ultrasound is a noninvasive application and promising therapy for accelerating bone remodelling during orthodontic tooth movement.

Keywords: Orthodontic Treatment, Low Intensity Pulsed Ultrasound, Tooth Movement

Düşük Şiddetli Darbeli Ultrasonun Ortodontik Diş Hareketi Üzerine Etkilerinin Histolojik ve Biyokimyasal Olarak İncelenmesi

ÖZET

Amaç: Çalışmamızın amacı düşük şiddetli darbeli ultrasonun ratlarda ortodontik diş hareketi üzerine etkilerini araştırmaktır.

Gereç ve Yöntem: Bu çalışmada Adnan Menderes Üniversitesi Hayvan Laboratuvarı'ndan 12 haftalık 40 yetişkin erkek Wistar albino rat kullanılmıştır. Ratlar her bir grupta on tane olmak üzere dört gruba ayrılmıştır. Grup 1, tedavi edilmemiş kontrol grubuydu. Grup 2'de dişleri hareket ettirmek için ortodontik spring kullanılmıştır. Grup 3 ve 4'te, ortodontik tedaviye ek olarak 14 gün boyunca 16 J/cm² veya 48 J/cm²'de düşük şiddetli darbeli ultrason uygulanmıştır. 14. günde diş hareket miktarı ölçülmüştür. Serum kemik alkalen fosfataz (BALP) ve C-telopeptid tip I kollajen (CTX-I) düzeyleri biyokimyasal olarak analiz edilmiştir. Histolojik olarak osteoklast, osteoblast ve inflamatuvar hücre sayısı, kılcal damar yoğunluğu ve yeni kemik oluşumu belirlenmiştir. Nükleer faktör-kappa B ligand (RANKL), osteoprotegerin (OPG), vasküler endotelial büyüme faktörü (VEGF) ve transforme edici büyüme faktörü- β (TGF- β) immünohistokimyasal boyama kullanılarak değerlendirilmiştir.

Bulgular: Grup 4'teki BALP ve CTX-I düzeyleri kontrol grubuna göre anlamlı olarak daha yüksekti ($p < 0.05$). Grup 4'ün diş hareket miktarı ve osteoklast, kılcal damar yoğunluğu ve inflamatuvar hücre sayısı grup 2'den anlamlı miktarda daha yüksekti ($p < 0.05$). Grup 4'ün RANKL ve OPG düzeyleri grup 2'den anlamlı olarak daha fazlaydı ($p < 0.05$).

Sonuç: Ultrason invaziv olmayan bir uygulamadır ve ortodontik diş hareketi sırasında kemik remodelingini hızlandırmak için umut vaat eden bir tedavidir.

Anahtar Kelimeler: Ortodontik Tedavi, Düşük Şiddetli Darbeli Ultrason, Diş Hareketi

INTRODUCTION

Orthodontic tooth movement is a result of organized remodeling of the periodontal tissues caused by application of forces (1,2). Accelerating tooth movement is desirable for decreasing treatment duration, reducing side effects and improving post-treatment stability. Shorter treatment periods have long been desired by both patients and orthodontists (1,3).

Administration of platelet-rich plasma (4), adiponectin (5), bisphosphonates (6), methylphenidate (7), dihydroxyvitamin D3 (8), parathyroid hormone (9), prostaglandin E2 (PGE2) (10), osteocalcin (11), icariin (12), and vitamin C (2) have been employed to increase rapidity and quality of orthodontic tooth movement. Investigators tested non-invasive techniques that are well accepted by patients including low level laser therapy (13-15) and low intensity pulsed ultrasound (16-18).

Low intensity pulsed ultrasound application has been confirmed by the U.S. Food and Drug Administration (FDA) for bone regeneration and fracture healing (3). Low-level laser stimulation can be used for treating orthodontically induced root resorption (19), enhancing mandibular growth in children with hemifacial microsomia (20), bone regeneration in the midpalatal suture area (21) and accelerating tooth movement (18).

Although there are few reports concerning the effects of low intensity pulsed ultrasound on tooth movement, low intensity pulsed ultrasound in vitro has exhibited an anabolic effect on growth factors and other signaling factors that results in differentiation of osteogenic cells (3). Low intensity pulsed ultrasound has been shown to accelerate orthodontic tooth movement by 45% and to promote alveolar bone remodeling by stimulating the human gingival fibroblast/runt-related transcription factor 2/bone morphogenetic protein 2 signaling pathway and receptor activator of nuclear factor-kappa B ligand (RANKL) expression (18).

The most common applications of low intensity pulsed ultrasound use 30mW/cm² intensity, 20% duty cycle and 1.5 MHz frequency (22). The intensity of low intensity pulsed ultrasound treatment can range from about 30 to 1000 mW/cm² (23,24). The energy density (J/cm²) is calculated as ultrasound intensity (W/cm²) x time (seconds). Robertson and Baker (25) suggested that an energy density dose of low intensity pulsed ultrasound ranges from 2 to 150 J/cm².

Based on literature, we hypothesized that low intensity pulsed ultrasound application might be accelerate the rate of orthodontic tooth movement in rats. Therefore, we investigated the effects of two energy densities of low intensity pulsed ultrasound on alveolar bone remodelling during orthodontic tooth movement.

MATERIAL AND METHODS

Animals and Appliance Placement: We used 40 adult male Wistar albino rats (12-weeks old age) taken from the Experimental Animal Center at Aydin Adnan Menderes University. Ethical permission was obtained from the University of Aydin Adnan Menderes, Local Ethics Committee for Animal Experiments (64583101/2015/015). The animals were housed under constant environmental conditions: 22±2 °C, 12 h light:12 h dark cycle with access to standard laboratory feed and water ad libitum.

Rats were divided randomly into four groups each cage of ten. Group 1 was the untreated negative control and groups 2–4 were the experimental groups. In group 2, a helical spring was used for orthodontic tooth movement. In groups 3 and 4, orthodontic treatment was combined with low intensity pulsed ultrasound at the energy density doses of 16 J/cm² or 48 J/cm², respectively, for 14 days using an ultrasound therapy device (BTL 5710Sono; BTL Industries Ltd., Newcastle, UK); 1 MHz, 20% duty cycle, 150 Hz, for 32 sec. Low intensity pulsed ultrasound treatment was applied to the right maxillary incisor. Ultrasonic coupling gel (BTL Sono, BTL Industries Ltd.) was placed between gingiva of the incisors and the ultrasound transducer. Rats were anesthetized lightly with 10 mg/kg sodium pentobarbital by intraperitoneal (i.p.) injection before application of low intensity pulsed ultrasound. Ultrasound was applied after placing the animal in a restraint that restricted excessive movements.

A helical spring prepared from 0.016 inch stainless steel wire was used for tooth movement and force of the spring was calibrated to 20 g. A hole was drilled in both maxillary incisors at the level of the gingival papilla on the mesial sides. Springs were attached into the holes to the incisors under 100 mg/kg xylazine and 20 mg/kg ketamine anesthesia; 1 ml xylazine+ketamine/kg was injected intraperitoneally (Figure 1). The distance between the mesial edges of the maxillary incisors was measured at the end of the study using a digital caliper.

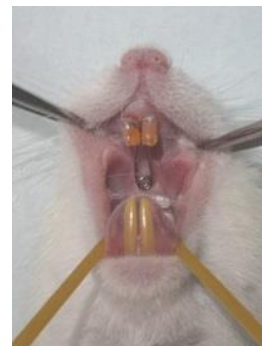

Figure 1. Appliance used for orthodontic tooth movement.

Histological Examination: At the end of the experiment period, all animals were sacrificed in accordance with animal ethics guidelines. Premaxillae of all animals were dissected and fixed with 10% formalin for 48 h. The samples were decalcified in 10% EDTA, for 8 weeks, then tissue samples were dehydrated through a graded alcohol series, cleared in xylene and embedded paraffin. The paraffin blocks were sectioned (5 µm thick). The sections were stored at 60°C overnight, then dewaxed using xylene for 30 min. Sections were rehydrated through a graded alcohol series and sections were stained with hematoxylin for 6 min. After washing with tap water for 5 min, the sections were differentiated with acid alcohol solution and stained with eosin for 2 min. The sections were dehydrated through a graded alcohol series to xylene. Sections were cleared in xylene for 30 min, then covered with Entellan (107961; Merck, Darmstadt, Germany) and observed by light microscopy (Olympus BX-43, Tokyo, Japan) (15).

Three histological sections from each animal were analyzed. All groups were compared for the number of osteoblasts, osteoclasts, infiltrated inflammatory cells, new bone formation and capillary density.

Immunohistochemical Examination: Avidin-biotin peroxidase method was used for immunohistochemical evaluation. Sections were incubated at 60°C overnight, then placed in xylene for 30 min. After dehydration through a graded alcohol series, the sections were washed with distilled water. Sections were treated with 2% trypsin at 37°C for 10 min and incubated in 3% H₂O₂ for 5 min. After incubating the sections with blocking solution for 1 h, they were incubated with primary antibodies: anti-RANKL (sc-7628; Santa Cruz Biotechnology, CA, USA) diluted 1:100, anti-OPG (sc-8468; Santa Cruz Biotechnology, CA, USA) diluted 1:100, anti-VEGF (sc-152; Santa Cruz Biotechnology, CA, USA) diluted 1:100 and anti-TGF-β (sc-146; Santa Cruz Biotechnology, CA, USA) diluted 1:100 for 18 h at 4°C. Sections were washed three times for 5 min each in phosphate-buffered saline (PBS) followed by incubation with biotinylated Ig G and addition of streptavidin peroxidase. After washing the secondary antibody with PBS three times for 5 min each, the sections were stained with DAB substrate system containing diaminobenzidine (DAB-Plus Substrate Kit; Invitrogen, Paisley, UK) to visualize the immunoreactions, then counterstained with Mayer's hematoxylin (ScyTek Laboratories, Utah, USA). The sections were covered with a coverslip using Entellan (107961; Merck) and observed by light microscopy (Olympus).

A semiquantitative grading system was used to compare the immunohistochemical staining. The intensities were rated as: 1, mild; 2, moderate; 3, strong; 4, very strong.

Biochemical Examination: After the end of the study period, blood samples were collected from the heart under the ketamine-xylazine anesthesia; then the animals were sacrificed by cervical dislocation. The serum samples were separated by centrifugation 10 minutes at 3000 rpm and portioned into 3 eppendorf tubes. The serum samples were kept at -80 °C until the time of analysis. The serum levels of C-telopeptide type I collagen (CTX-I), and bone alkaline phosphatase (BALP) were measured by using rat CTX-I ELISA kit (Cusabio Biotech Co., Ltd., Wuhan, China) and rat BALP ELISA kit (Cusabio Biotech Co., Ltd., Wuhan, China), respectively. Each kit had a microplate that precoated with specific antibody. While the principle of the CTX-I ELISA kit was competitive inhibition, principle of BALP ELISA kit was quantitative sandwich enzyme immunoassay technique. Standards and serum samples were run in duplicate in each assay according to kit instructions. To determine the samples concentrations we draw a graphic by using standard concentrations and their optic densities. The concentration of CTX-I is expressed as pg/ml, while the concentration of BALP is expressed as U/l. The sensitivity values of CTX-I ELISA kit and BALP ELISA kit were 31.25 pg/ml and 3.9 U/L respectively.

Statistical Analysis: All statistical analysis and calculations used IBM SPSS Statistics 21.0. Biochemical and histological measurements were evaluated by Shapiro Wilk's test to determine the normality of the distribution. Normally and non-normally distributed measurements were expressed as means ±SD and medians (minimum-maximum), respectively. Immunohistochemical staining intensity was assessed according to frequency as well. Groups were compared with respect to the biochemical, histological and immunohistochemical measurements by ANOVA or Kruskal-Wallis test according to the distribution of the measurements. ANOVA F statistics or Welch F statistics were calculated and Bonferroni or Games Howell *post hoc* tests were applied according to the Levene's test result. Dunn-Bonferroni correction was used as the *post hoc* test for Kruskal-Wallis test to assess the pairwise-group differences. The immunohistochemical staining intensity was evaluated using the Mantel-Haenszel test for linear association. A p<0.05 was accepted as statistically significant.

RESULTS

We found that although the amount of tooth movement was greater for groups 3 and 4 than for group 2, the only significant difference was for group 4 compared to group 2 (p<0.05) (Table 1).

Table 1. Effect of low intensity pulsed ultrasound stimulation on tooth movement.

	Group 1	Group 2	Group 3	Group 4
Tooth movement (mm)	-	2.00 ± 0.12 ¹	2.23 ± 0.45	2.51 ± 0.23 ¹

Data are means ±SD. ¹Difference between mean values is significant ($p < 0.05$).

Biochemical Findings: We found that serum BALP and CTX-I values were significantly greater for group 4 than for group 1 ($p < 0.05$) (Table

2). BALP and CTX-I levels in groups 2 and 3 were similar compared to each other and to groups 1 and 4.

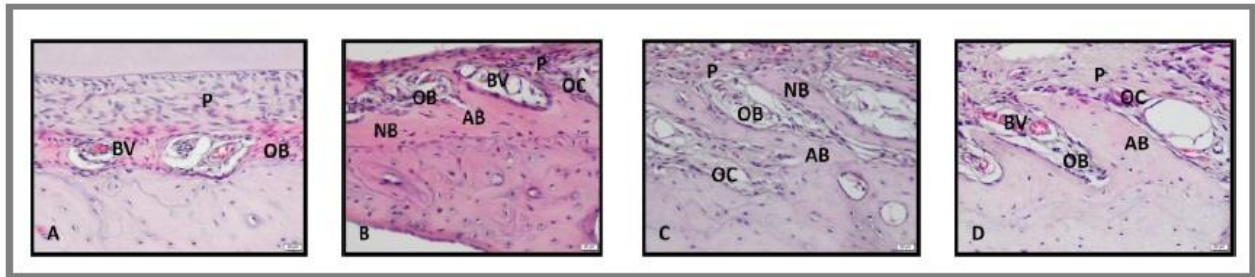
Table 2. Effects of low intensity pulsed ultrasound stimulation on serum BALP and CTX-I levels.

	Group 1	Group 2	Group 3	Group 4
BALP* (U/l)	33.90 ± 4.18 ^a	38.08 ± 5.05	39.38 ± 6.66	45.01 ± 6.03 ^a
CTX-I** (pg/ml)	255.0 (208–335) ^a	319.0 (270–460)	308.5 (239–430)	356.0 (293–429) ^b

*Means ± SD; ** median (min-max); ^{a,b}difference between values with same superscript in the same row is significant ($p < 0.05$).

Histological Findings: There were significant differences between the groups with respect to the number of osteoblasts, osteoclasts, inflammatory cells, capillary density and new bone formation ($p < 0.05$ for each comparison). Pairwise comparisons revealed that the mean number of

osteoblast was significantly higher in group 4 compared to group 1. The number of osteoclasts, inflammatory cells and capillary density were significantly greater for group 4 than for group 2 ($p < 0.05$) and for group 3 compared to group 1 ($p < 0.05$) (Figure 2; Table 3).

**Figure 2.** Hematoxylin and eosin staining photomicrographs from the study groups. Increased osteoblasts, osteoclasts, inflammatory cells, capillary density and new bone formation were observed in Group 4.

A) Group 1, B) Group 2, C) Group 3, D) Group 4. OB: osteoblast, OC: osteoclast, NB: new bone, AB: alveolar bone, BV: blood vessel, P: periodontal ligament. (A, B, C, D: x200 magnification).

Table 3. Effects of on the number of osteoblasts, osteoclasts, inflammatory cells, capillary density and new bone formation.

	Group 1	Group 2	Group 3	Group 4
Osteoblasts* [¥]	31.90 ± 3.70	59.70 ± 5.66	66.40 ± 5.52	91.40 ± 6.13
Osteoclasts**	1.0 (1–2) ^{1,2}	3.0 (2–4) ³	4.0 (3–5) ¹	6.0 (5–9) ^{2,3}
Inflammatory cells**	7.5 (6–9) ^{a,b}	10.0 (8–16) ^c	12.5 (11–14) ^a	18.0 (15–20) ^{b,c}
Capillary density**	10.5 (8–11) ^{a,β}	12.0 (10–17) ^γ	14.0 (12–15) ^a	20.5 (18–24) ^{β,γ}
New bone formation**	1.0 (1–2) ^f	2.0 (1–2)	2.0 (1–3)	2.0 (2–3) ^f

*Means ± SD; ** median (min-max); difference between values with same superscripts in the same row is significant ($p < 0.05$); [¥]all groups differ significantly from each other.

Immunohistochemical Findings: We found a significant linear association among the groups with the intensity scores for RANKL, OPG, TGF-β and VEGF staining ($p < 0.001$ for each). The intensity rating for each staining was increased from group 1 to group 4 (Table 4). The intensity

levels of RANKL and OPG for group 4 were significantly greater than for group 2 ($p < 0.05$). The intensity levels of TGF-β and VEGF for groups 3 and 4 were significantly higher than for group 1 ($p < 0.05$) (Figure 3; Table 5).

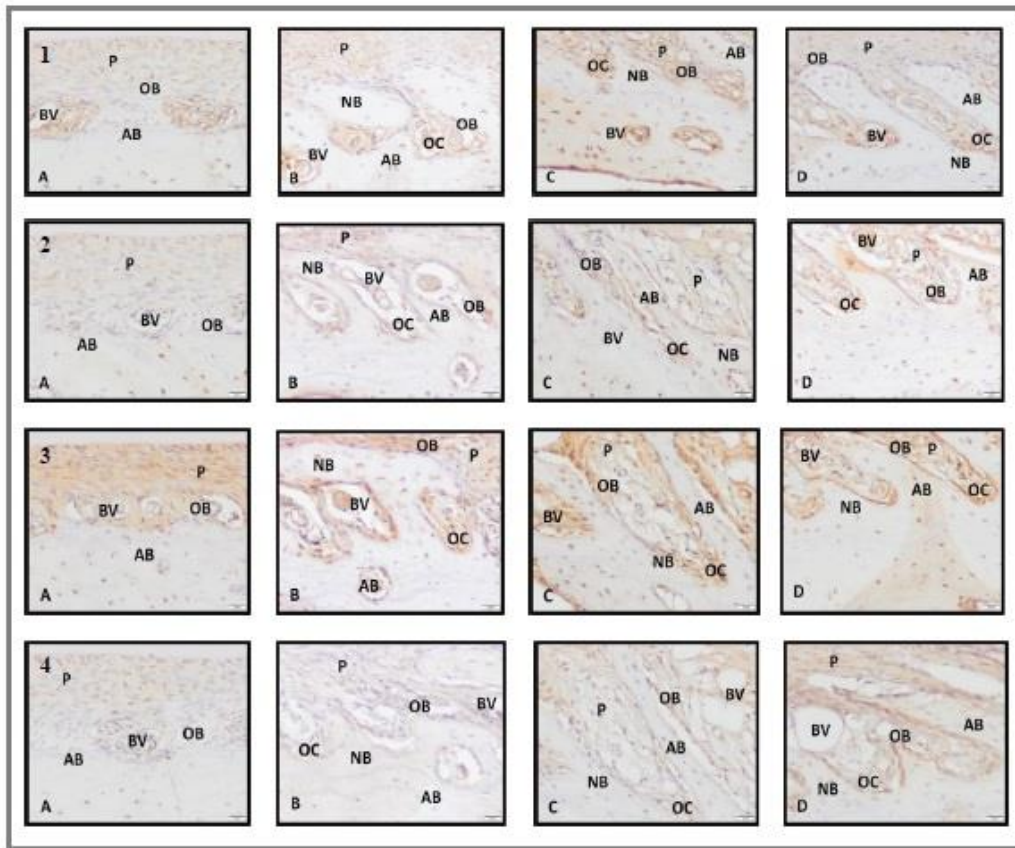


Figure 3. Immunohistochemical staining photomicrographs from the study groups. Strongly RANKL, OPG, VEGF and TGF- β immunoreactivity were observed at new bone formation sites in Group 4. Group 2 and 3 showed similar staining. A) Group 1, B) Group 2, C) Group 3, D) Group 4. 1) Sections immunostained with anti-RANKL primary antibody, 2) Sections immunostained with anti-OPG primary antibody, 3) Sections immunostained with anti-VEGF primary antibody, 4) Sections immunostained with anti-TGF- β primary antibody. (A, B, C, D: x200 magnification).

Table 4. Immunohistochemical staining intensity scores

	Group 1	Group 2	Group 3	Group 4	Test statistics	<i>p</i>
<i>RANKL</i> *					26.301	< 0.001
Mild	5	1	0	0		
Moderate	5	4	2	0		
Strong	0	5	7	3		
Very strong	0	0	1	7		
<i>OPG</i> *					20.338	< 0.001
Mild	4	1	0	0		
Moderate	6	8	6	2		
Strong	0	1	3	2		
Very strong	0	0	1	6		
<i>TGF-β</i> *					18.120	< 0.001
Mild	5	0	0	0		
Moderate	5	8	4	4		
Strong	0	2	6	1		
Very strong	0	0	0	5		
<i>VEGF</i> *					23.108	< 0.001
Mild	4	0	0	0		
Moderate	6	4	3	0		
Strong	0	6	6	5		
Very strong	0	0	1	5		

*Numbers in the cells indicate the frequency of rats having the staining intensity for the corresponding parameters in each group. Since the number of the rats is less than 20 in each group, percentage is not given.

Table 5. Group comparisons of the immunohistochemical staining intensity

	Group 1	Group 2	Group 3	Group 4
RANKL	1.5 (1 - 2) ^{1,2}	2.5 (1 - 3) ³	3.0 (2 - 4) ¹	4.0 (3 - 4) ^{2,3}
OPG	2.0 (1 - 2) ^a	2.0 (1 - 3) ^b	2.0 (2 - 4)	4.0 (2 - 4) ^{a,b}
TGF- β	1.5 (1 - 2) ^{α,β}	2.0 (2 - 3)	3.0 (2 - 3) ^{α}	3.5 (2 - 4) ^{β}
VEGF	2.0 (1 - 2) ^{*,**}	3.0 (2 - 3)	3.0 (2 - 4) [*]	3.5 (3 - 4) ^{**}

Data are medians (min-max); difference between values with same superscripts in the same row is significant ($p < 0.05$).

DISCUSSION

Low intensity pulsed ultrasound treatment is a safe, non-invasive technique that could be a promising approach for accelerating orthodontic tooth movement and shortening the period of orthodontic treatment. There are few reports concerning the effects of this treatment on orthodontic tooth movement (17,18). We investigated the effects of 16 or 48 J/cm² doses of low intensity pulsed ultrasound treatment using biochemical, histological and immunohistochemical techniques in rats.

We found that the rate of tooth movement differed among the experimental groups. The greatest tooth movement was observed in group 4. We observed 25% acceleration of tooth movement day 14, whereas Xue et al. (18) reported a rate increase of 45%.

BALP is produced by osteoblasts and participates in osteoid formation and mineralization. CTX-I is formed by degradation of bone collagen and therefore is considered a marker for resorption (26). Although we found increased serum BALP and CTX-I levels in the low intensity pulsed ultrasound and tooth movement groups, these differences were not statistically significant, possibly because the orthodontic force applied to a local area such as teeth is assessed from systemic blood.

Inflammation of the tissues occurs during orthodontic tooth movement. We found that number of inflammatory cells and capillary density were increased significantly in group 4 compared to group 2; groups 2 and 3, and groups 1 and 2 were similar in terms of these characteristics. We believe that low intensity pulsed ultrasound application increased inflammation, because it accelerated the tooth movement.

We found increased numbers of osteoclasts and osteoblasts in groups 3 and 4 compared to group 2. Different ultrasound intensities produce distinctive effects on osteoblasts in vitro (27,28).

Suzuki et al. (29) reported that application of low intensity pulsed ultrasound stimulated development of osteoblasts. An increased number of osteoclasts after the application of low intensity pulsed ultrasound has been reported in previous studies (16,18); our findings were consistent with earlier reports. Low intensity pulsed ultrasound application accelerates orthodontic tooth movement by increasing the number of osteoclasts and their activity (18).

RANKL and OPG regulate the bone remodelling and reflect the differentiation and function of osteoclasts. Both RANKL and OPG are synthesized from osteoblast, RANKL modulates the preosteoclast for differentiation to mature osteoclast and OPG inhibits RANKL-RANK binding and also osteoclast differentiation. RANKL responds to compressive forces and increase tooth movement (30). We expected to find significantly increased RANKL immunoreactivity in group 4 compared to group 2, because low intensity pulsed ultrasound stimulation accelerated orthodontic tooth movement. Our findings are consistent with earlier studies (18). OPG was significantly higher in group 4 than in group 2, which was consistent with previous reports (31,32).

We found that ultrasound treatment enhanced osteoclast activity by stimulating the inflammatory response to mechanical forces. Inflammatory cytokines stimulate RANKL production, which regulates osteoclast activity. Furthermore, under inflammatory conditions, RANKL is produced also by immune system cells; therefore, RANKL production increased.

Conclusion

Application of intensity pulsed ultrasound increased orthodontic tooth movement, which increased RANKL release and shortened the orthodontic treatment period. The use of this technique also increased the number of bone cells.

REFERENCES

- Huang H, Williams RC, Kyrkanides S. Accelerated orthodontic tooth movement: molecular mechanisms. *Am J Orthod Dentofacial Orthop* 2014;146:620-32.
- Miresmaeili A, Mollaei N, Azar R, et al. Effect of dietary vitamin C on orthodontic tooth movement in rats. *J Dent (Tehran)* 2015;12:409-13.
- Qamruddin I, Alam MK, Khamis MF, et al. Minimally invasive techniques to accelerate the orthodontic tooth movement: a systemic review of animal studies. *Biomed Res Int* 2015; 608530.

4. Gulec A, Bakkalbasi BC, Cumbul A, et al. Effects of local platelet-rich plasma injection on the rate of orthodontic tooth movement in a rat model: A histomorphometric study. *Am J Orthod Dentofac Orthop* 2017;151:92-104.
5. Haugen S, Aasarød KM, Stunes AK, et al. Adiponectin prevents orthodontic tooth movement in rats. *Arch Oral Biol* 2017;83:304-11.
6. Brunet MD, Araujo CM, Johann AC, et al. Effects of zoledronic acid on orthodontic tooth movement in rats. *Braz Dent J* 2016;27:515-23.
7. Aghili H, Yassaei S, Zahir ST, et al. Effect of methylphenidate on tooth movement and histological features in rats. *J Clin Diagn Res* 2017;11:ZF01-05.
8. Kawakami M, Takano-Yamamoto T. Local injection of 1,25-dihydroxyvitamin D3 enhanced bone formation for tooth stabilization after experimental tooth movements in rats. *J Bone Miner Metab* 2004;22:541-6.
9. Soma S, Iwamoto M, Higuchi Y, et al. Effects of continuous infusion of PTH on experimental tooth movement in rats. *J Bone Miner Res* 1999;14:546-54.
10. Yamasaki K, Shibata Y, Fukuhara T. The effect of prostaglandins on experimental tooth movement in monkeys (*Macaca fasciata*). *J Dent Res* 1982;61:1444-6.
11. Kobayashi Y, Takagi H, Sakai H, et al. Effects of local administration of osteocalcin on experimental tooth movement. *Angle Orthod* 1998;68: 259-66.
12. Chen Y, Wang XX, Zhao BJ, et al. Effects of icariin on orthodontic tooth movement in rats. *Int J Clin Exp Med* 2015;15:8608-16.
13. Tsuka Y, Fujita T, Shirakura M, et al. Effects of neodymium-doped yttrium aluminium garnet (Nd:YAG) laser irradiation on bone metabolism during tooth movement. *J Lasers Med* 2016;7:40-4.
14. Milligan M, Arudchelvan Y, Gong SG. Effects of two wattages of low-level laser therapy on orthodontic tooth movement. *Arch Oral Biol* 2017;80:62-8.
15. Altan BA, Sokucu O, Ozkut MM, et al. Metrical and histological investigation of the effects of low-level laser therapy on orthodontic tooth movement. *Lasers Med Sci* 2012;27:131-40.
16. Feres MFN, Kucharski C, Diar-Bakirly S, et al. Effect of low-intensity pulsed ultrasound on the activity of osteoclasts: an in vitro study. *Arch Oral Biol* 2016;70:73-8.
17. Dahhas FY, El-Bialy T, Afify AR, et al. Effects of low-intensity pulsed ultrasound on orthodontic tooth movement and orthodontically induced inflammatory root resorption in ovariectomized osteoporotic rats. *Ultrasound Med Biol* 2016;42:808-14.
18. Xue H, Zheng J, Cui Z, et al. Low-intensity pulsed ultrasound accelerates tooth movement via activation of the BMP-2 signaling pathway. *Plos One* 2013;8:e68926.
19. El-Bialy T, El-Shamy I, Graber TM. Repair of orthodontically induced root resorption by ultrasound in humans. *Am J Orthod Dentofac Orthop* 2004;126:186-93
20. El-Bialy T, Janadas A, Albaghdadi T. Nonsurgical treatment of hemifacial microsomia by therapeutic ultrasound and hybrid functional appliance. *Open Access J Clin Trials* 2010;2,29-36.
21. Toy E, Oztürk F, Altindış S, et al. Effects of low-intensity pulsed ultrasound on bone formation after the expansion of the inter-premaxillary suture in rats: a histologic and immunohistochemical study. *Aust Orthod J* 2014;30:176-183.
22. Watson T. Ultrasound in contemporary physiotherapy practice. *Ultrasonics* 2008;48:321-29.
23. Khanna A, Nelmes RT, Gougoulias N, et al. The effects of LIPUS on soft-tissue healing: a review of literature. *Br Med Bull* 2009;89:169-82.
24. terHaar G. Therapeutic ultrasound. *Eur J Ultrasound* 1999; 9:3-9.
25. Robertson VJ, Baker KG. A review of therapeutic ultrasound: effectiveness studies. *Phys Ther.* 2001;81:1339-50.
26. Gerdhem P, Ivaska KK, Alatalo SL, et al. Biochemical markers of bone metabolism and prediction of fracture in elderly women. *J Bone Miner Res* 2004;19:386-93.
27. Reher P, Elbeshier EI, Harvey W, et al. The stimulation of bone formation in vitro by therapeutic ultrasound. *Ultrasound Med Biol* 1997;23:1251-8.
28. Reher P, Harris M, Whiteman M, et al. Ultrasound stimulates nitric oxide and prostaglandin E2 production by human osteoblast. *Bone* 2002;3:236-41.
29. Suzuki A, Takayama T, Suzuki N, et al. Daily low-intensity pulsed ultrasound mediated osteogenic differentiation in rat osteoblasts. *Acta Biochim Biophys Sin (Shanghai)* 2009;41:108-15.
30. Kantarci A, Will L, Yen S (eds). *Tooth Movement*. Front Oral Biol 2016, Basel, Karger, 9-16.
31. Borsje MA, Ren Y, de Haan-Visser HW, et al. Comparison of low-intensity pulsed ultrasound and pulsed electromagnetic field treatments on OPG and RANKL expression in human osteoblast-like cells. *Angle Orthod* 2010;80:498-503.
32. Dalla-Bona DA, Tanaka E, Inubushi T, et al. Cementoblast response to low- and high-intensity ultrasound. *Arch Oral Biol* 2008;53:318-23.