



## Histopathological Effect of Bendiocarb on Small Intestine Tissues of Rats: Role of Vitamins C and E

Fatma Gokce APAYDIN<sup>1,\*</sup> , Hatice BAS<sup>2</sup> , Suna KALENDER<sup>3</sup> , Caglar ADIGUZEL<sup>1</sup> , Yusuf KALENDER<sup>1</sup> 

<sup>1</sup>Gazi University, Faculty of Science, Department of Biology, Ankara-Turkey

<sup>2</sup>Bozok University, Faculty of Arts and Science, Department of Biology, Yozgat-Turkey

<sup>3</sup>Gazi University, Faculty of Gazi Education, Department of Science, Ankara-Turkey

### Article Info

Received: 24/01/2018

Accepted: 18/12/2018

### Keywords

Bendiocarb  
Vitamin C  
Vitamin E  
Small intestine  
Histopathology

### Abstract

Bendiocarb is a carbamate insecticide which causes general toxic effects on mammalian. This study aimed to examine the possible ameliorative roles vitamins E and C and their combination against effect of bendiocarb small intestine toxicity in rats. For this purpose, forty-eight adult albino male rats were divided like: vitamin E, control, vitamin C, vitamins (C and E), bendiocarb, bendiocarb+vitamin E, bendiocarb+vitamin C, and bendiocarb+vitamin C+vitamin E groups. After four weeks of treatment small intestine tissues were examined for histopathological alterations. Bendiocarb induced toxicity on small intestine tissues, vitamins had not protective effects of this toxicity.

## 1. INTRODUCTION

Humans are under influence to via the diet contamination with many pesticides. Pesticide groups like pyrethroids (PYs), carbamates (CBs) and organophosphorus (OPs), which have toxic effects to their target living things also occur in several mammals and human [1]. Carbamates are carbonic acid esters and also extracted from the Calabar bean, the seed of a *Physostigma venenosum* [2]. Carbamate pesticides inhibit acetylcholine esterase activities in several tissues [3].

Bendiocarb (2,3-isopropyliden-dioxyphenylmethylcarbamate) is a carbamate group pesticide and it is used to control agricultural pests and also vectors such as flies, as well as household [4, 5]. Similar to other carbamates, bendiocarb causes inhibition of acetylcholinesterase [6]. When bendiocarb poisoning has been done, abdominal cramps, constriction of pupils, headache, chest discomfort, nausea, sweating, muscle tremors have been shown [7,8]. It has been reported that bendiocarb caused hepatotoxicity in rats [9].

Antioxidants, ascorbic acid (vitamin C) and tocopherol (vitamin E) are used as a nutritional support and they can protect tissues against toxic agents. Vitamin C (ascorbic acid), is soluble in water and chain-crusher antioxidant compound. It is one of the most widely used non-enzymatic antioxidant molecules [10]. Similarly, vitamin E is also a non-enzymatic antioxidant and it is well known lipid soluble antioxidant and inhibits lipid peroxidation by scavenging lipid proxy radicals [11]. Previous studies reported that vitamins prevent the cells against pesticides damage [11,12].

Evaluation of tissue toxicity is an important criterion for toxicological studies. It is well documented that many xenobiotic may induce tissue damage related to oxidative stress in animals. Therefore, oxidative stress can cause cell degeneration [9,12,13].

Previous studies have shown that treatment to small intestine causes a variety of structural damages in the digestive system [14]. For this reason, in this study we aim to possible protections of vitamins E and C treatment on small intestine tissues of rats against bendiocarb. [9,15,17-20].

## 2. MATERIAL AND METHODS

### 2.1. Experimental Procedure, Animals and Chemicals

Forty-eight Wistar male rats were preferred with 300 to 320 g average weight. At standard status (relative humidity 45%, 12-hour light/dark period and room temperature 18-22 °C) rats were kept in plastic cages (n=6) and fed rodent diet. Water for drinking was given for all animal ad libitum. There are eight group rats in this study: vitamin E (doses of 100 mg/kg), control, vitamin C (doses of 100 mg/kg), vitamin C+vitamin E, bendiocarb (doses of LD50 of 1/50 which is 0,8 mg/kg) (Jiang et al., 2013), bendiocarb and vitamin C, bendiocarb and vitamin E and bendiocarb+vitamin C+vitamin E groups. Bendiocarb was used from Germany (Dr. Ehrenstorfer). Vitamins and also others preferred used from Sigma. All chemicals were exposed to experimental animals with gavage orally. Xylazin-ketamin were used for experimental animals dissection for 28 days. Ethics committee approval was received in this study (no: G.Ü.ET-15.042).

### 2.2. Histopathological Evaluation

All rats were anesthesia and dissected then small portions of the small intestine were quickly removed and take into the fixation chemical to 10% formalin. After, tissue samples were dehydrated in ascending grades of ethanol series and embedded in pure paraffin and blocks of the tissues were prepared for microtome. The sections were cut in 5-7 µm thickness with microtome. Tissue slides were stained with Hematoxylin-Eosin (H & E) by standard histological methodology. Then the tissue slides were examined under a light microscope (Olympus BX51, Tokyo, Japan) and photographed with a camera (Olympus E-330, Olympus Optical Co., Ltd., Japan). Least ten tissue slides were prepared and investigated from each tissues.

## 3. RESULTS

A normal control structure of the small intestine of rats was observed via light microscopic examination (Figure 1A). Small intestinal cells of vitamin C, vitamin E and vitamin C+vitamin E treated animals were similar with control rats. Exposure to bendiocarb caused degenerative changes in the small intestine shown that necrosis, infiltration and atrophy was shown in this groups (Figure 1B-C). With the bendiocarb plus vitamin C necrosis and atrophy was shown (Figure 1D). Bendiocarb plus vitamin E we noted atrophy and villus degeneration (Figure 1E). We determined the necrotic changes and villus degeneration vitamins E and C used together (Figure 1F).

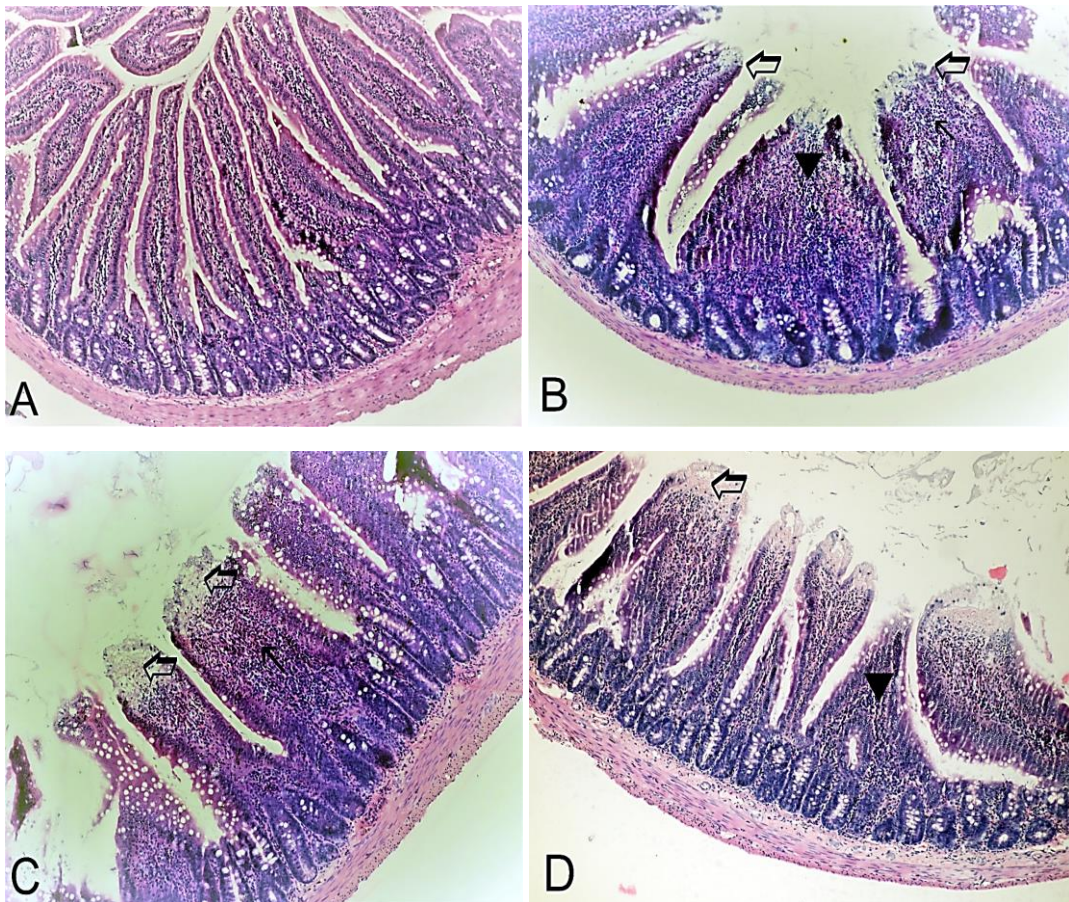
## 4. DISCUSSION

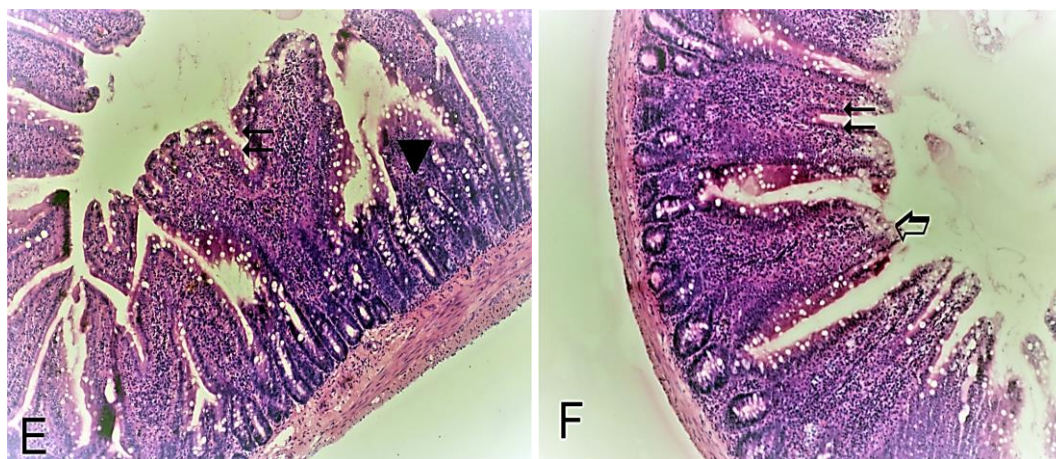
Histopathological alterations have known to be as important biomarkers for the toxicological experiments and also related to xenobiotic toxicities [15]. In this study, while bendiocarb was given at 1/50 of oral LD50, no rat dead during the experiment. It is reported that bendiocarb causes so many toxic situations in animals [9].

Many investigators have found lots of histological negative effect in so many tissues after bendiocarb exposure. Petrovova et al. determined that structural alterations in spleen after bendiocarb tretanment, which probably causes toxic effects in the immune system. In addition, the intestines are also affected by xenobiotic [5]. Shirpoor et al., indicate that ethanol induces the small intestine abnormality by oxidative toxicities, and that these effects can be protective by using vitamin E as an antioxidant and anti-inflammatory molecule [14]. Similar to other studies, in this study we revealed that several histopathological changes such as infiltration, necrosis in small intestine by bendiocarb induced.

The role of antioxidant enzymes and lipid peroxidation markers have been revealed in the pathogenesis of pesticides in several studies [16]. Baş et al., reported in their study, changes in antioxidant enzymes activities can be due to reactive oxygen species formation by chemicals and they are also thinking of the relationship between oxidative stress and pesticide toxicity [15]. In our study we observed that many histopathological changes in small intestine tissues. It may be due to oxidative damage on cells by bendiocarb. In addition, previous studies many chemicals such as heavy metals, pesticides caused negative effects on several tissues like kidney, testis and heart [17-20] also chemicals may cause oxidative damage and DNA damage in rats [21].

Vitamins are known that antioxidants which ameliorate cellular important molecules from reactive oxygen species damage for example collagen situations, immune system, anemia treatment, genetic, and activation of enzyme system [22]. When antioxidant supplementary in foods, it has been shown to enhance toxic elements scavenging role and tolerated oxidative damages [23]. Moreover, vitamin C and vitamin E protect various tissues against damages induced by chemicals [9, 23] However, in our study, we didn't show ameliorative effect of vitamins on small intestine tissues. It may be related to use doses of these vitamins.





**Figure 1.** (A) Small intestine sections of control rats, x100. (B-C) Small intestine sections of bendiocarb-treated rats, ⇨: necrosis, ▲: atrophy, ⇨: infiltration, x200. (D) Small intestine sections of bendiocarb plus vitamin C-treated rats, ⇨: necrosis, ▲: atrophy, x200. (E) Small intestine sections of bendiocarb plus vitamin E-treated rats ▲: atrophy, ⇨: villus degeneration, x200. (F) Small intestine sections of bendiocarb plus vitamin C plus vitamin E-treated rats, ⇨: necrosis, ⇨: villus degeneration, x200 H&E.

## CONFLICTS OF INTEREST

No conflict of interest was declared by the authors.

## REFERENCES

- [1] Jardim, A.N.O., Brito, A.P., Donkersgoed, G., Boon, P.E. and Caldas, E.D., “Dietary cumulative acute risk assessment of organophosphorus, carbamates and pyrethroids insecticides for the Brazilian population”, *Food and Chemical Toxicology*, 112: 108-117, (2018).
- [2] Hayes, W.J., Laws, E.R., *Handbook of Pesticide Toxicology*, Academic Press, New York. p. 303. (1991).
- [3] Siqueira, A., Rodrigues, K.B.A., Gonçalves-Júnior, V., Calefi, A.S., Fukushima, A.R., Cuevas, S.E.C., Spinosa, H.S. and Maiorka, P.C., “Exhumation of Wistar rats experimentally exposed to the carbamate pesticides aldicarb and carbofuran: A pathological and toxicological study”, *Experimental Toxicology and Pathology*, 68: 307–314, (2016).
- [4] Capcarova, M., Petrovova, E., Flesarova, S., Dankova, M., Massanyi, P. and Danko, J., “Bendiocarbamate induced alterations in selected parameters of rabbit homeostasis after experimental peroral administration”, *Pesticide Biochemistry and Physiology*, 8: 213–218, (2010).
- [5] Petrovova, E., Massanyi, P., Capcarova, M., Zivcak J. and Stodola, L., “Structural alterations in rabbit spleen after bendiocarb administration”, *Journal of Environmental Science and Health B*, 46: 788–792, (2011).
- [6] Flesarova, S., Lukac, N., Danko, J. and Massanyi, P., Bendiocarbamate induced structural alterations in rabbit thymus after experimental peroral administration”, *Journal of Environmental Science and Health*, 42: 329–334, (2007).
- [7] Smulders, C.J., Bueters, T.J., Van Kleef, R.G. and Vijverberg, H.P., “Selective effects of carbamate pesticides on rat neuronal nicotinic acetylcholine receptors and rat brain acetylcholinesterase”, *Toxicology and Applied Pharmacology*, 193: 139–146, (2003).

- [8] Jokanovic', M., "Medical treatment of acute poisoning with organophosphorus and carbamate pesticides" *Toxicology Letters*, 190: 107–115, (2009).
- [9] Apaydin, F.G., Bas, H., Kalender, S. and Kalender, Y., "Bendiocarb induced histopathological and biochemical alterations in rat liver and preventive role of vitamins C and E", *Environmental Toxicology Pharmacology*, 49: 148–155, (2017).
- [10] Uzun, F.G., Kalender, Y., "Chlorpyrifos induced hepatotoxic and hematologic changes in rats: The role of quercetin and catechin", *Food and Chemical Toxicology* 55: 549-556, (2013).
- [11] El-Demerdash, F., "Antioxidant effect of vitamin E and selenium on lipid peroxidation, enzyme activities and biochemical parameters in rats exposed to aluminum" *Journal of Trace Elements in Medicine and Biology*, 18: 113-121, (2004).
- [12] Kalender, S., Apaydin, F.G., Uzunhisarcikli, M. and Aslanturk, A., "Protective Role of Sodium Selenite and Vitamin E Against Rat Erythrocytes Induced by Mercury Chloride", *Gazi University Journal of Science*, 27(4): 1123-1129 (2014).
- [13] Aslanturk, A., Kalender, S., Uzunhisarcikli, M. and Kalender, Y., "Effects of methidathion on antioxidant enzyme activities and malondialdehyde level in midgut tissues of *Lymantria dispar* (Lepidoptera) larvae", *Journal of the Entomological Research Society*, 13: 27-38, (2011).
- [14] Shirpoor, A., Barmaki, H., Ansari, M.K., Ikhanizadeh, B. and Barmaki, H., "Protective effect of vitamin E against ethanol-induced small intestine damage in rats" *Biomedicine and Pharmacotherapy*, 78: 150–155, (2016).
- [15] Baş, H., Kalender, S., Karaboduk, H. and Apaydin, FG., "The effects on antioxidant enzyme systems in rat brain tissues of lead nitrate and mercury chloride", *Gazi University Journal of Science*, 28(2): 169-174, (2015).
- [16] Demir, F., Uzun, F.G., Durak, D. and Kalender, Y., "Subacute chlorpyrifos-induced oxidative stress in rat erythrocytes and the protective effects of catechin and quercetin", *Pesticide Biochemistry and Physiology*, 99: 77-81, (2011).
- [17] Apaydin, F.G., Bas, H., Kalender, S. and Kalender, Y., "Subacute effects of low dose lead nitrate and mercury chloride exposure on kidney of rats", *Environmental Toxicology and Pharmacology*, 41: 219-224, (2016).
- [18] Apaydin, F.G., Kalender, S., Bas, H., Demir, F. and Kalender, Y., "Lead nitrate induced testicular toxicity in diabetic and non-diabetic rats: Protective role of sodium selenite" *Brazilian Archives of Biology and Technology*, 58(1): 68-74, (2015).
- [19] Uzun, F.G., Kalender, Y., "Protective effect of vitamins C and E on malathion-induced nephrotoxicity in male rats" *Gazi University Journal of Science*, 24(2): 193-201, (2011).
- [20] Baş, H., Kalender, Y., "Chlorpyrifos induced cardiotoxicity in rats and the protective role of quercetin and catechin" *Gazi University Journal of Science*, 24(3): 387-395, (2011).
- [21] Baş, H., Kalender, Y., Pandir, D. and Kalender, S., "Effects of Lead Nitrate and Sodium Selenite on DNA Damage and Oxidative Stress in Diabetic and Non-Diabetic Rat Erythrocytes and Leucocytes" *Environmental Toxicology and Pharmacology*, 39: 1019-1026, (2015).

- [22] Mezouar, D., Merzouk, H., Merzouk, A.S., Merzouk, S.A., Belarbi, B. and Narce, M., “In vitro effects of vitamins C and E, n-3 and n-6 PUFA and n-9 MUFA on placental cell function and redox status in type 1 diabetic pregnant women”, *Placenta*, 42: 114-121, (2016).
- [23] Chappell, L.C., Seed, P.T., Kelly, F.J., Briley, A., Hunt, B.J., Charnock-Jones, S., Mallet, A. and Poston, L., “Vitamin C and E supplementation in women at risk of preeclampsia is associated with changes in indices of oxidative stress and placental function”, *American Journal of Obstetrics and Gynecology*, 187: 777-784, (2002).