

***Benedenia* sp. Infestation Along with Motile *Aeromonas* Septicemia in Common Stingray (*Dasyatis pastinaca* Linnaeus, 1758)**

Emre Turgay¹ , Remziye Eda Yardimci¹ , Suheyra Karatas¹ 

¹Istanbul University, Faculty of Aquatic Sciences, Istanbul, Turkey

ORCID IDs of the authors: E.T. 0000-0001-9964-3919; R.E.Y. 0000-0001-7737-8739; S.K. 0000-0003-2006-7854

Please cite this article as: Turgay E, Yardimci RE, Karatas S. *Benedenia* sp. Infestation Along with Motile *Aeromonas* Septicemia in Common Stingray (*Dasyatis pastinaca* Linnaeus, 1758). Eur J Biol 2019; 78(1): 1-4.

ABSTRACT

Objective: The aim of this study was to determine the cause of mortalities occurring in common stingray (*Dasyatis pastinaca*) individuals held in a public aquarium.

Materials and Methods: Moribund common stingrays (approx. 1 m in length and 2 kg in weight) that had previously been caught by trawling and placed in the quarantine tanks in a public aquarium were examined to determine the cause of mortalities.

Results: The affected common stingrays had haemorrhages on the ventral side of the body. Internally, the liver was pale and pseudotubercles were observed in the spleen. In the examined specimens, monogenean parasites were observed in blisters on the skin of the dorsal side of the body. According to their morphological, physiological and biochemical characteristics as well as gene sequence analysis, the parasites were identified as *Benedenia* sp., and the bacterial isolates were identified as *Aeromonas hydrophila*.

Conclusion: In this study, *Benedenia* sp. is reported initially, along with motile *Aeromonas septicemia* in common stingray.

Keywords: Common stingray, *Dasyatis pastinaca*, benedenia, *Aeromonas hydrophila*

INTRODUCTION

The common stingray (*Dasyatis pastinaca*), which is a member of the family Dasyatidae, is distributed throughout the North-eastern Atlantic Ocean, the Mediterranean Sea and along the African coast southwards to Senegal. It is also a coastal species, which enters coastal lagoons, shallow bays and estuaries. In the North Aegean Sea, the common stingray is caught by trawl fisheries (1) and occasionally (as part of small-scale commercial concerns), by bottom trawl, gillnet, beach seine, bottom longline and trammel net fisheries. While so many studies on the biology and ecology of the common stingray exist in other countries, this kind of information is limited in Turkey. In one such study, the diet of common stingray was studied by Saglam et al. (2). In that study, the specimens

were collected by bottom trawling at depths of 20-40 m in the southeastern Black Sea between June 2007 and May 2008. In the results of the study, no difference was detected between sexes and diet of small and large individuals, but significant differences were found between seasons. Yigin and Ismen (3) studied age, growth and reproduction of the common stingray in the North Aegean Sea. Only one case report of parasite infestation in Turkey exists in Turkey, by Diamant et al. (4). They reported subcutaneous spindle-shaped inclusions on the stingray's dorsal surface as the earliest clinical signs of a microsporidian infection in the common stingray in Iskenderun Bay. The purpose of this study was to determine the cause of mortalities occurring in common stingray held in quarantine under stressful conditions.



Address for Correspondence: Emre Turgay

E-mail: eturgay@istanbul.edu.tr

Submitted: 30.11.2018 • **Revision Requested:** 17.12.2018 • **Last Revision Received:** 18.12.2018 • **Accepted:** 19.12.2018

© Copyright 2019 by The Istanbul University Faculty of Science • Available online at <http://ejb.istanbul.edu.tr> • DOI: 10.26650/EurJBiol.2019.0018

MATERIALS AND METHODS

The common stingrays (*Dasyatis pastinaca*) (20 specimens, approx. 1 m in length and 1-2 kg in weight) were caught by trawling in Edremit Bay in the Aegean Sea, and then transported to Istanbul and placed into the quarantine tanks of a public aquarium. A few days later, mortalities were observed in the stingray population as well as severe feeding difficulty. The water parameters of the aquarium were as follows: temperature was 24°C, salinity was 28, pH was 8, dissolved oxygen concentration was 7,6 mg/L and oxidation reduction potential was 175 mV. Two moribund common stingrays were sampled in line with standard methods (5). During dissection, all internal organs and the skin, as well as the body cavity and the fins, were examined for parasites. The obtained parasites were first examined under a dissection microscope and the isolated parasites were fixed and preserved according to standard protocols. The bacteriological samples from the liver, spleen and skin lesions were streaked onto Marine Agar (MA) (Difco, Detroit, MI, USA) plates and the plates were incubated at 22°C for 72 hours. The morphological and physiological characteristics of the bacterial colonies from each plate were determined using conventional biochemical and physiological tests as well as rapid identification kits (API 20E) (BioMérieux, Marcy-l'Étoile, France). Molecular diagnostic methods were also used for the identification of both parasite samples and bacterial strains. The isolates on the MA plates were inoculated into Marine Broth (MB) (Difco, Detroit, MI, USA) and incubated overnight at 22°C, then total DNA was extracted from liquid cultures or directly from ethanol fixed parasite samples using the Pure Link™ Genomic DNA Mini Kit (Invitrogen, Carlsbad, CA, USA) according to the manufacturer's instructions. For bacterial identification, a 540-bp-long fragment of the 16S rRNA gene was amplified and sequenced using the universal bacteria primer set: primer S-D-Bact-0008-a-S-20 and primer S-*-Univ-0536-a-A-18 (6). To identify the parasites, the universal eukaryotic primer set F-566 and R-1200 was used to amplify and sequence a part of the 18S rRNA gene (7).

RESULTS

During the parasitological examination, monogenean parasites were observed in blisters on the skin of the dorsal side of the body (Figure 1). Affected common stingrays had haemorrhages on the ventral side of the body and on the cloaca (Figure 1). Internally, a pale liver or haemorrhages in the liver and pseudotubercles in the examined fish spleen were observed (Figure 1). The parasites were identified as *Benedenia* sp. following the diagnostic keys outlined by Yamaguti (8). The anterior part of the parasite had a pair of attachment organs and the opisthaptor had a marginal extension surrounding the haptor as a skirt (Figure 2). On the bacteriological examination side; creamy, round, raised, entire colonies of 2–3 mm diameter were formed on the MA. These bacterial isolates appeared as Gram-negative, motile chemo-organotrophic (fermentative) rods and were oxidase and catalase positive. According to their morphological and biochemical characteristics (Table 1) and 16S rRNA and 18S rRNA gene sequencing results, the bacterial isolates that obtained from

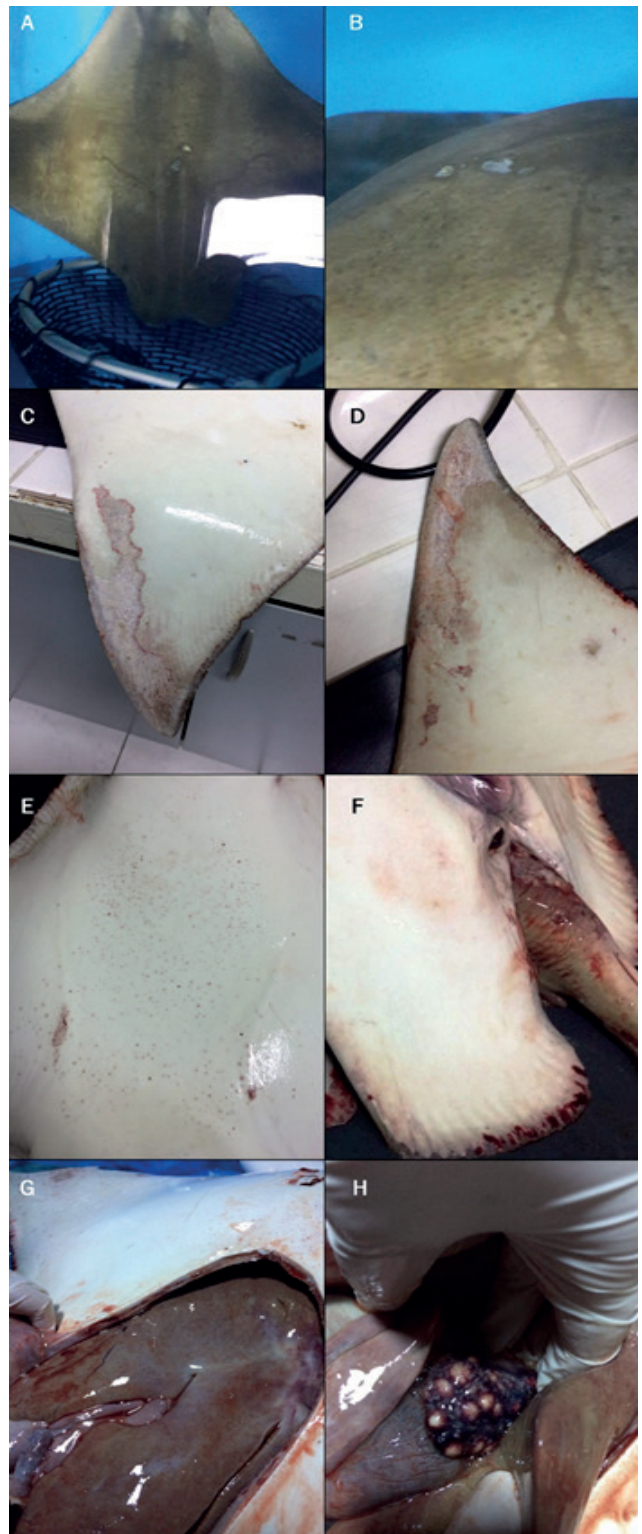

Figure 1. Affected common stingray, (A) *Benedenia* sp. on the dorsal side of the body, (B) blister on the skin, (C, D) haemorrhages on the ventral side of pectoral fins and skin lesions, (E) petechial haemorrhages on the ventral side of body, (F) haemorrhages on the cloaca, tail and pelvic fins, (G) haemorrhages in the pale liver, (H) pseudotubercles in the spleen.

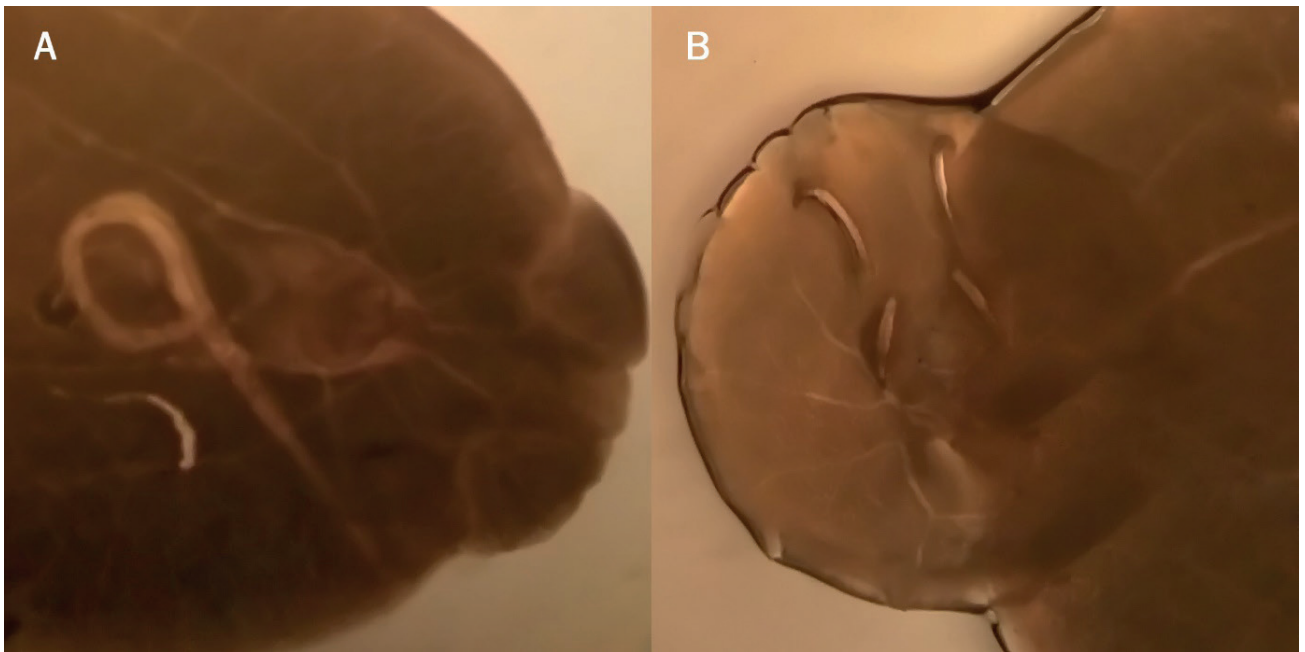


Figure 2. *Benedenia* sp. (A) attachment and copulatory organs at the anterior part (x25), (B) marginal hooks on the opisthaptor.

Table 1. Morphological and phenotypical characteristics of the isolated strain

Morphology	rods	Citrate	+
Motility	+	Degradation of urea	-
Gram staining	-	H ₂ S production	-
Catalase	+	ONPG	+
Cytochrome oxidase	+	MacConkey	+
O/129 resistance (150µg)	R	Glucose	+
O/F	F	Sucrose	+
Indole	+	Inositol	-
Voges Proskauer reaction	-	Maltose	+
Methyl red	+	Esculine	+
Arginine dihydrolase	+	Nitrate reduction	+
Lysine decarboxylase	-	Gelatin hydrolase	+
Ornithine decarboxylase	-	Growth at 37°C	+

Key: -: Negative, +: Positive, F: Fermentative, R: Resistant

the liver, spleen and skin lesions, were identified as *Aeromonas hydrophila*, whereas monogeneans were identified as *Benedenia* sp. (acc. no. MK106094).

DISCUSSION

Monogenean fish parasites are commonly found in both marine and freshwater environments and live on a wide range of aquatic animals including fishes, however, most of them are ectoparasites with relatively low fecundity and direct life cycles and they usually infect a single host species (9). Although monogenean parasites are usually not present in high numbers on individual fishes in the wild, they may cause more destructive effects in animals that are held in captivity like those in public aquaria as a consequence of increased stressors-mostly due to spatial restriction and overcrowding (10, 11).

The monogenean *Benedenia epinepheli* was first discovered by Yamaguti (12) and then this parasite was re-described and reported by Ogawa et al. (13). *Benedenia* species previously found in fish were as follows (with fish host and isolated tissue/organ information): *B. epinepheli* from gills, fins, eyes and body surface from *Epinephelus akaara*, *Conger myriaster* and *Paralichthys olivaceus* (12); *B. sekii* from body surface of *Pagrus major* (12); *B. seriola* from *Seriola lalandi* (12) and from skin in *Seriola quinqueradiata* (14); *B. rohdei* from gills and *B. lutjani* from skin of *Lutjanus carponotatus* (15); *B. sciaenae* from *Sciaena umbra* and *Umbrina cirrosa*, *B. monticellii* from gill filaments of *Liza aurata* (16, 17). Despite the large number of the parasite isolation reports in teleost fish, almost none of them were isolated from diseased hosts. Additionally, reports in elasmobranch species like stingrays are very limited.

The only *Benedenia sciaenae* infestation in Turkey, has been reported in cultured meagre (*Argyrosomus regius*) (18). In that study, they reported haemorrhagic lesions and scale losses on the skin as clinical findings. Similarly, our examined stingrays

only showed haemorrhagic lesions on the skin externally, but additionally we observed the parasites in blisters on the skin.

Aeromonas hydrophila is one of the ubiquitous and well known fish pathogens of both marine and freshwater fish species and is mostly considered an opportunistic pathogen (19). *A. hydrophila* involving infections in fish may cause several distinct pathological conditions but has mostly been associated with causing haemorrhagic septicaemia (20). In accordance with this, moribund stingrays had haemorrhages on their body and also internal haemorrhages were observed in the liver.

CONCLUSION

Low host specificity, ubiquitous distribution and the high susceptibility of marine aquarium fish are factors which are indicative of the parasite's great potential to become a disease problem among cultured fish. In this study, *Benedenia* sp. is reported initially along with motile *Aeromonas* septicemia in the common stingray.

Peer-review: Externally peer-reviewed.

Acknowledgements: This study was approved by the Istanbul University Local Committee on Animal Research Ethics (decision year 2016).

Conflict of Interest: The authors have no conflict of interest to declare.

Funding Information: There are no funders to report for this submission

REFERENCES

1. Yeldan H, Avsar D, Manaşırılı M. Age, growth and feeding of the common stingray (*Dasyatis pastinaca*, L., 1758) in the Cilician coastal basin, northeastern Mediterranean Sea. *J Appl Ichthyol* 2009; 25(s1): 98-102.
2. Sağlam H, Orhan A, Kutlu S, Aydin I. Diet and feeding strategy of the common stingray *Dasyatis pastinaca* (Linnaeus, 1758) on the Turkish coast of southeastern Black Sea. *Cah Biol Mar* 2010; 51(1), 37-44.
3. Yigin CC, Ismen A. Age, growth and reproduction of the common stingray, *Dasyatis pastinaca* from the North Aegean Sea. *Mar Biol Res* 2012; 8(7): 644-53.
4. Diamant A, Goren M, Yokeş MB, Galil BS, Klopman Y, Huchon D, et al. *Dasyatispora levantinae* gen. et sp. nov., a new microsporidian parasite from the common stingray *Dasyatis pastinaca* in the eastern Mediterranean. *Dis Aquat Organ* 2010; 91(2): 137-50.
5. Whitman KA. *Finfish and Shellfish Bacteriology Manual: Techniques and Procedures*. Ames, USA: Iowa State Press; 2004.
6. Suau A, Bonnet R, Sutren M, Godon J-J, Gibson GR, Collins MD, et al. Direct analysis of genes encoding 16S rRNA from complex communities reveals many novel molecular species within the human gut. *Appl Environ Microbiol* 1999; 65(11): 4799-807.
7. Hadziavdic K, Lekang K, Lanzen A, Jonassen I, Thompson EM, Troedsson C. Characterization of the 18S rRNA gene for designing universal eukaryote specific primers. *PloS one* 2014; 9(2): e87624.
8. Yamaguti S. *Systema helminthum: Monogenea and Aspidocotylea*, Interscience New York; 1963.
9. Whittington ID, Kearn GC. Hatching strategies in monogenean (Platyhelminth) parasites that facilitate host infection. *Integr Comp Biol* 2011; 51(1): 91-9.
10. Reed P, Francis-Floyd R, Klinger R, Petty D. Monogenean parasites of fish. 2009; 4: 1-4. Available from: URL: <http://fisheries.tamu.edu/files/2013/09/Monogenean-Parasites-of-Fish.pdf>
11. Scholz T. Parasites in cultured and feral fish. *Vet Parasitol* 1999; 84(3-4), 317-35.
12. Yamaguti S. *Studies on the helminth fauna of Japan, Part 19, Fourteen new ectoparasitic trematodes of fishes*. Japan: Published by the Author; 1937.
13. Ogawa K, Bondad-Reantaso MG, Wakabayashi H. Redescription of *Benedenia epinepheli* (Yamaguti, 1937) Meserve, 1938 (Monogenea: Capsalidae) from cultured and aquarium marine fishes of Japan. *Can J Fish Aquat Sci* 1995; 52(S1): 62-70.
14. Kearn GC, Ogawa K, Maeno Y. Hatching Patterns of the Monogenean Parasites *Benedenia seriola* and *Heteraxine heterocerca* from the Skin and Gills, Respectively, of the Same Host Fish, *Seriola quinqueradiata*. *Zoolog Sci* 1992; 9(2): 451-5.
15. Ernst I, Whittington ID. Hatching rhythms in the capsalid monogeneans *Benedenia lutjani* from the skin and *B. rohdei* from the gills of *Lutjanus carponotatus* at Heron Island, Queensland, Australia. *Int J Parasitol* 1996; 26(11): 1191-204.
16. Palombi A. I. *Trematodi d'Italia: parte I. Trematodi Monogenetici*, Rosenberg; 1949.
17. Minelli A, Ruffo S, La Posta S, editors. *Checklist delle Specie della Fauna Italiana, Fascicoli 1-10*. Bologna, Italy: Calderini, 1993.
18. Toksen E, Buchmann K, Bresciani J. Occurrence of *Benedenia sciaenae* van Beneden, 1856 (Monogenea: Capsalidae) in cultured meagre (*Argyrosomus regius* Asso, 1801)(Teleost: Sciaenidae) from western Turkey. *Bull Eur Assoc Fish Pathol* 2007; 27(6): 250.
19. Austin B, Austin DA. *Bacterial fish pathogens*. Fifth edition. Springer Netherlands, 2012; ISSN no: 978-94-007-4883-5.
20. Buller NB. *Bacteria and fungi from fish and other aquatic animals: a practical identification manual*. 2nd Edition. Oxfordshire, UK: CABI, 2014; ISSN: 978-1845938055.