

## Surgical Approach to Anterior Mediastinal Masses

### Anterior Mediastinal Kitlelere Cerrahi Yaklaşım

Çavuşoğlu N<sup>1\*</sup>, Özkaya M<sup>1</sup>

1. University Of Health Sciences Antalya Training and Research Hospital, Department of Thoracic Surgery

#### ABSTRACT

**Aim:** The aim of this study was to evaluate the clinical progress, type of surgical approach and early results of resection of anterior mediastinal masses.

**Patients and Methods:** We retrospectively reviewed the reports of 25 patients who underwent surgery for an anterior mediastinal mass between 2014 and 2019. Patients' age, gender, presenting symptoms, preoperative radiological investigations and surgical techniques were recorded. There were eight male and 17 female patients, and their age ranged from 18-89 with a mean of 44.4± 16.9 years.

**Results:** The most frequent presenting symptoms were chest pain (90%) and cough (50%). The most common pathological diagnoses were thymic tumors (n=14, 56%) and lymphoma (n=5, 20%). Surgical approaches applied were median sternotomy in 16 patients, partial sternotomy in five patients and VATS (Video Assisted Thoracic Surgery) in four patients. There were no postoperative deaths or major complications, but eight patients had minor complications. Postoperative stay was 5±5.2 days.

**Conclusion:** Surgery is a safe technique for diagnosis and treatment of anterior mediastinal masses.

Key words: Mediastinum; operative procedures; surgery

#### ÖZ

**Amaç:** Anterior mediastinal kitle tanısı ile ameliyat edilen vakaların klinik seyri, cerrahi yaklaşım tiplerini ve erken dönem sonuçlarını incelenmesi amaçlandı.

**Hastalar ve Yöntemler:** 2014 – 2019 yılları arasında anterior mediastinal kitle tanısı ile ameliyat edilen 25 olgu retrospektif olarak incelendi. Hastaların yaşı, cinsiyeti, prezente eden semptomları, preoperatif radyolojik değerlendirmeleri ve cerrahi teknikler kaydedildi. Sekizi erkek, 17'i kadın toplam 25 hastanın yaşları 18-89 arasında değişmekte olup ortalama 44,4± 16,9 yıl idi.

**Bulgular:** En sık izlenen semptom göğüs ağrısı (%90) ve öksürük (%50) olduğu gözlemlendi. En sık gözlenen patolojik tanılar timik tümörler (n=14, %56,0) ve lenfoma (n=5,%20,0) olarak belirlendi. Uygulanan cerrahi yaklaşım 16 hastada median sternotomi, beş hastada parsiyel sternotomi ve dört hastada VATS (Video Assisted Thoracic Surgery) idi. Postoperatif ölüm veya majör komplikasyon gözlenmemekle birlikte sekiz hastada minör komplikasyonlar gelişti. Ortalama cerrahi sonrası hastanede kalış süresi 5±5,2 gün idi.

**Sonuç:** Anterior mediasten kitlelerin tanı ve tedavisinde cerrahi yaklaşım güvenle uygulanabilen temel bir yöntemdir.

Anahtar Kelimeler: Mediastinum, Operatif Prosedürler, Cerrahi

Received Date: : 18.04.2019 Accepted Date: 24.05.2019 Published Date:23.08.2019

\*Corresponding Author: Nilay Çavuşoğlu, Health Sciences University Antalya Practice and Research Center Department of Thoracic Surgery, Antalya, Turkey. Phone: +90 5057705753 mail: drnili@hotmail.com

ORCID: 0000-0002-0675-9267

## INTRODUCTION

The mediastinum is limited by the pleural cavities laterally, the thoracic inlet superiorly and the diaphragm inferiorly and is further divided into anterior, middle and posterior compartments[1]. Masses in the anterior mediastinum account for 50% of all mediastinal masses and they can either be neoplastic (eg, thymomas, lymphomas, thymic carcinomas, thymic carcinoids, thymolipomas, germ cell tumors, lung metastases) or nonneoplastic conditions (eg, intrathoracic goiter, thymic cysts, lymphangiomas, aortic aneurysms)[2,3]. Anterior mediastinal masses impose both diagnostic and therapeutic challenges so that surgery is not the initial treatment for some of them (e.g. lymphoma or seminomatous germ cell tumor). But still, the traditional approach for both diagnosis and treatment is excision of the mass in the absence of any other pathological conditions[4,5]. Also, invasion or compression of vital surrounding structures may cause both surgical and anesthesiological challenges[6].

We retrospectively reviewed records of our patients who underwent surgery for an anterior mediastinal mass to evaluate the early results of resection.

## PATIENTS AND METHODS

Twenty-five patients who underwent surgery for an anterior mediastinal mass between 2014 and 2019 were analyzed retrospectively. The patients with mass other than the anterior mediastinum were excluded. The records of these patients were reviewed, and data regarding sex, age, presenting symptoms, physical findings, noninvasive diagnostic evaluation, definitive surgical procedure, early and long term results and the final histopathological diagnosis were analyzed. The study was conducted in accordance with the principles of the Declaration of Helsinki. Written consent was obtained from all patients. Due to the retrospective pattern of the study approval from the medical ethical committee was not required.

All patients underwent computed tomographic (CT) scans, and in each, an anterior mediastinal mass was revealed. Further evaluations, including Positron emission tomography (PET), magnetic resonance imaging (MRI) or echocardiography

were performed where required (Fig 1). Respiratory function test and routine blood tests were requested from the patients before the operation. Prior to surgery, patients were evaluated for signs and symptoms of myasthenia gravis, and were medically controlled. Goal of surgery was complete excision of the lesion and during the surgery pleural surfaces were examined for pleural metastases in order to exclude pleural metastases. Minimally invasive procedures were applied only if all oncologic goals met as in standard procedures. Video-assisted thoracic surgery (VATS) was performed with dual lumen endobronchial tubes for selective ventilation in order to create pneumothorax on the operative side. Sharp and blunt dissection techniques were used and dissections were performed with endoscopic port instruments. In order to avoid chest wall contamination and tumor seeding, the working port incisions were extended as needed and extraction sacs were used for delivery of specimens. Patients were also seen at the 1- to 6-week postoperative polyclinic visit.

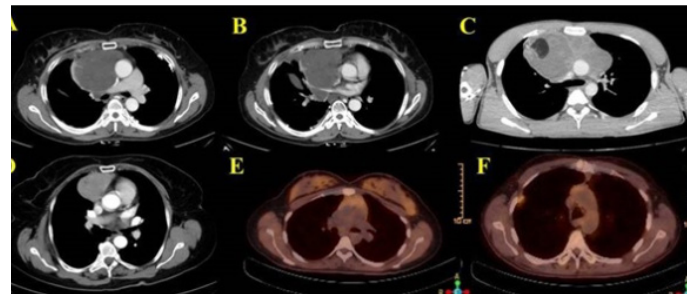
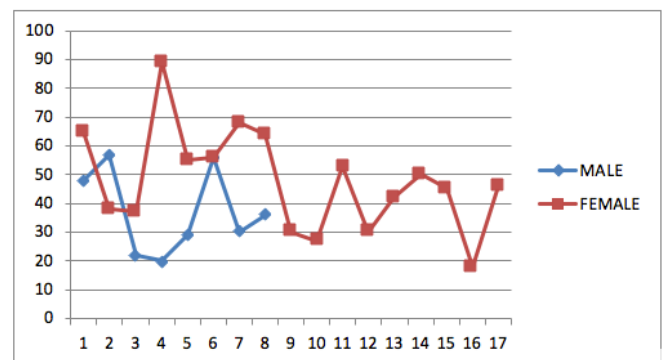


Figure 1. CT scans of (A) 55-year-old woman with fibromyxoid sarcoma, (B) 22-year-old man with mature cystic teratoma, (C) 27-year-old woman with thymic hyperplasia, (D) 30-year-old woman with thymic hyperplasia and PET-CT images of (E) 64-year-old woman with thymoma and (F) 56-year-old man with thymic and squamous cell carcinoma.



Graphic 1. Age distribution between genders

## RESULTS

There were eight male and 17 female patients, and their age ranged from 18-89 with a mean of  $44.4 \pm 16.9$  years (Graphic 1). Table 1 and 2 outlines clinical demographics of patients. None of the patients had diagnostic biopsy prior to the surgery and all patients were symptomatic. Symptoms consisted primarily of chest pain, cough and shortness of breath. Two patients had superior vena cava syndrome.

The surgical approach was standard median sternotomy in 16 patients, partial sternotomy in 5, and VATS in 4. Figure 2 demonstrates a patient who underwent partial sternotomy. The choice of operation was based on personal preference of the surgeon according to the location of the lesion. Complete excision of the lesion was achieved in 18 patients (72%) and the operation served as the primary therapeutic intervention in 15 patients (60%). Two of the remaining three patients were thymic carcinomas and one was germ cell tumor. These patients received radiotherapy and chemotherapy after surgery.

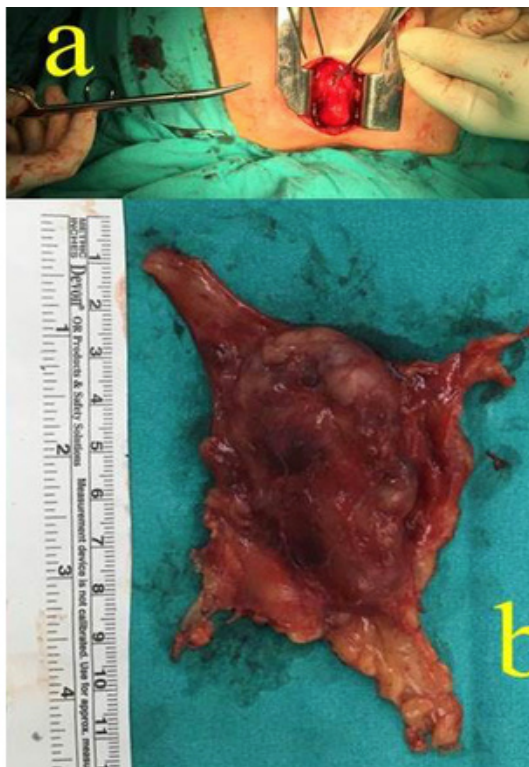


Figure 2. Intraoperative view. (a) Partial sternotomy (b) Resected specimen.

Overall, 18 patients had malignant disease and

the remaining 7, benign disease (72% vs. 28%). The etiology of the mass in these 25 patients was as follows: Lymphoma, 4 patients (Hodgkin's, 2; non-Hodgkin's, 2); thymoma, 5; thymic carcinomas, 2; germ cell tumor, 1; histiocytic sarcoma, 1; neuroendocrine sarcoma, 1; fibromyxoid sarcoma, 1; mature cystic teratoma, 2; ectopic thyroid tissue, 2; adenocarcinoma(metastatic), 1 and thymic hyperplasia, 4. The most common pathological diagnoses were thymic tumors (n=14, 56%) and hematologic malignancy (n=5, 20%). Specific pathologic diagnoses are listed in Table 1. There were no operative or hospital deaths in this study and no patients had a major complication. Eight minor complications occurred, including elevation of a hemi diaphragm (three patients), atelectasis (four patients), and acute renal failure (one patient). Postoperative stay was  $5 \pm 5.2$  days.

Table 1. Specific pathologic diagnoses

| Type                       | Female<br>n(%) | Male<br>n(%) | Total<br>n(%) |
|----------------------------|----------------|--------------|---------------|
| Lymphoma (B Cell)          | 1 (4.3)        | 1 (4.3)      | 2 (8.6)       |
| Lymphoma (Hodgkin)         | 1 (4.3)        | 1 (4.3)      | 2 (8.6)       |
| Histiocytic sarcoma        | 1 (4.3)        |              | 1 (4.3)       |
| Neuroendokrine sarcoma     | 1 (4.3)        |              | 1 (4.3)       |
| Fibromyxoid sarcoma        | 1 (4.3)        |              | 1 (4.3)       |
| Thymomas. Type B           | 5 (20.0)       |              | 5 (20.0)      |
| Thymic Carcinomas          |                | 2 (8.6)      | 2 (8.6)       |
| Mature cystic teratoma     |                | 2 (8.6)      | 2 (8.6)       |
| Germ cell tumor            |                | 1 (4.3)      | 1 (4.3)       |
| Thymic hyperplasia         | 4 (16.0)       | 1 (4.3)      | 5 (20.0)      |
| Ectopic thyroid tissue     | 2 (8.6)        |              | 2 (8.6)       |
| Adenocarcinoma(metastatic) | 1 (4.3)        |              | 1 (4.3)       |
| Total                      | 17             | 8            | 25            |

## DISCUSSION

Anterior and posterior borders of the anterior mediastinum are the sternum and the brachiocephalic vessels, pericardium, and ascending aorta, respectively. The most common tumors of the anterior mediastinum include thymic malignancies and lymphoma, but the prevalence of them differs according to both age and sex. In middle aged patients, thymoma is the most common anterior mediastinal mass and primary tumor of the anterior mediastinum [7]. In our series, 18 patients had malignant disease and the remaining seven patients had benign disease (72% vs. 28%). Also,

the most common pathological diagnoses were thymic tumors (n=14, 56%).

All patients with a mediastinal mass should be evaluated to determine the type of mass and the extent of disease before treatment, because surgery is not the treatment of choice in some cases. For a number of mediastinal masses, the definitive and most efficacious treatment is chemotherapy or radiation therapy or both[8]. However, the role of obtaining tissue diagnosis in the evaluation of mediastinal masses remains to be controversial because it may cause tumor cell seeding in the biopsy tract[9–11]. For these reasons, diagnosis and treatment of anterior mediastinal masses are one of the most challenging issues of thoracic surgery. Regardless of the type of the tumor it must be kept in mind that early surgery and chemotherapy should be considered to improve the cure rate of these diseases[12]. Complete excision of the lesion was achieved in 18 patients (72%) and the operation served as the primary therapeutic intervention in 15 patients (60%).

Median sternotomy is the incision of choice for many anterior mediastinal lesions[13]. Due to the lack of long-term data regarding recurrence and survival, minimally invasive procedures are not typically recommended, and may be considered if standard oncologic goals can be met [14–16]. In our study, surgical approaches applied were standard median sternotomy in 16 patients, partial sternotomy in five, and VATS in four. In the surgical management of large mediastinal tumors, we preferred a midline approach through a sternotomy. Although resection through video-assisted thoracic surgery (VATS) have become increasingly popular, this technique was unsuitable for large masses, and was applied for tumors smaller than three cm in diameter [17].

**Limitations:** The retrospective design of our study may be considered a limitation in terms of evidence value. However, it may contribute to the systematic reviews and meta-analyses [18] which will be done together with other studies originating from our country.

**Conclusion:** In this paper, we presented our experience in anterior mediastinal masses with different surgical approaches, with low operative mortality and morbidity rates. We believe that

complete resection should be attempted even if the surgery is challenging. In the absence of identifiable pathological diagnosis surgical resection should be considered in the management of anterior mediastinal tumors.

**Funding sources:** The authors received no financial support.

**Conflict of interest:** The authors have nothing to disclose and there are no conflicts of interests.

#### KAYNAKLAR

1. Laurent F, Latrabe V, Leceasne R, Zennaro H, Airaud JY, Rauturier JF, et al. Mediastinal masses: Diagnostic approach. *Eur Radiol* 1998;8:1148–59. doi:10.1007/s003300050525.
2. Strollo DC, Rosado De Christenson ML, Jett JR. Primary mediastinal tumors. Part 1: Tumors of the anterior mediastinum. *Chest* 1997;112:511–22. doi:10.1378/chest.112.2.511.
3. Marchevsky A, Marx A, Strobel P, Suster S, Venuta F, Marino M, et al. Policies and reporting guidelines for small biopsy specimens of mediastinal masses. *Chinese J Lung Cancer* 2014;17:104–9. doi:10.3779/j.issn.1009-3419.2014.02.07.
4. James M. Donahue and Francis C. Nichols. Primary Mediastinal Tumors and Cysts and Diagnostic Investigation of Mediastinal Masses. In: Shields TW, LoCicero J III RCF, editor. *Gen. Thorac. Surg.* 7th ed., Lippincott Williams and Wilkins; 2009, p. 2195–201.
5. Ferguson MK, Lee E, Skinner DB, Little AG. Selective Operative Approach for Diagnosis and Treatment of Anterior Mediastinal Masses. *Ann Thorac Surg* 1987;44:583–6. doi:10.1016/S0003-4975(10)62139-X.
6. Merrick HW, Martin JT, Woldenberg LEES. Massive Intraoperative Atelectasis Secondary to Untreated Mediastinal Hodgkin's Disease: Report of the Hazard and Review of the Literature. *J Surg Oncol* 1989;64:60–4.
7. Carter BW, Marom EM, Detterbeck FC. Approaching the patient with an anterior mediastinal mass: A guide for clinicians. *J Thorac Oncol* 2014;9:S102–9. doi:10.1097/JTO.0000000000000294.
8. Mullen B, Richardson JD. Primary Anterior Mediastinal Tumors in Children and Adults. *Ann Thorac Surg* 1986;42:338–45. doi:10.1016/S0003-4975(10)62751-8.
9. Tomaszek S, Wigle DA, Keshavjee S, Fischer S. Thymomas: Review of Current Clinical Practice. *Ann Thorac Surg* 2009;87:1973–80. doi:10.1016/j.athoracsur.2008.12.095.
10. Ettinger DS, Riehl GJ, Akerley W, Borghaei H, Chang AC, Cheney RT, et al. Thymomas and Thymic Carcinomas Clinical Practice Guidelines in Oncology. *J Natl Compr Cancer Netw* 2013;11:562–76. doi:10.6004/JNCCN.2013.0072.
11. Marchevsky A, Marx A, Strobel P, Suster S, Venuta F, Marino M, et al. Policies and reporting guidelines for small biopsy specimens of mediastinal masses. *J Thorac Oncol* 2014;17:104–9. doi:10.3779/j.issn.1009-3419.2014.02.07.
12. Zhang S, Gao H, Wang XA, Liang B, Li DW, Shao Y, et al. Primary choriocarcinoma in mediastinum with multiple lung metastases in a male patient: A case report and a review of the literature. *Thorac Cancer* 2014;5:463–7. doi:10.1111/1759-7714.12120.
13. Fry MGB and WA. Thoracic Incisions. In: Shields TW, LoCicero J III, Reed CE FR, editor. *Gen. Thorac. Surg.* 7th ed., Lippincott Williams and Wilkins; 2009, p. 397–401.
14. Toker A, Sone J, Zielinski M, Rea F, Tomulescu V, Deerbeck FC. Standard terms, definitions, and policies for minimally invasive resection of thymoma. *Chinese J Lung Cancer* 2014;17:90–4. doi:10.3779/j.issn.1009-3419.2014.02.05.
15. Pennathur A, Qureshi I, Schuchert MJ, Dhupar R, Ferson PF, Gooding WE, et al. Comparison of surgical techniques for early-stage thymoma: Feasibility of minimally invasive thymectomy and comparison with open resection. *J Thorac Cardiovasc Surg* 2011;141:694–700. doi:10.1016/j.jtcvs.2010.09.003.
16. Limmer KK, Kernstine KH. Minimally Invasive and Robotic-Assisted Thymus Resection. *Thorac Surg Clin* 2011;21:69–83. doi:10.1016/j.thorsurg.2010.08.005.
17. Li WWL, Van Boven WJP, Annema JT, Eberl S, Klomp HM, de Mol BAJM. Management of large mediastinal masses: Surgical and anesthesiological considerations. *J Thorac Dis* 2016;8:E175–84. doi:10.21037/jtd.2016.02.55.
18. Ahmet A. Systematic Reviews and Meta-Analyses *Acta Med. Alanya* 2018;2(2):62-63. [Turkish] DOI: 10.30565/medalanya.439541

**How to cite this article/Bu makaleye atıf için:**

Çavuşođlu N, Özkaya M. Surgical Approach to Anterior Mediastinal Masses.  
Acta Med. Alanya 2019;3(2):154-158 doi:10.30565/medalanya.555611