

Central Venous Catheter Malposition: Two Case Reports

Semih AYDEMİR¹, Yavuz KATIRCI²

¹Department of Intensive Care Unit, University of Health Sciences, Atatürk Pulmonary Diseases and Thoracic Surgery Education and Research Hospital, Ankara, Turkey

²Department of Emergency Medicine, University of Health Sciences, Keçioren Training and Research Hospital, Ankara, Turkey

Abstract

Introduction: Unintended vessel advancement during central venous catheter (CVC) insertion is a rare but serious complication. To reduce the complications while CVC placement, the practitioner should be experienced. After the placement it is required to verify correctness.

Case Presentation:

- **Case 1:** A 65-year-old male patient who returned as hypotensive after cardiopulmonary resuscitation was planned with CVC insertion for monitoring central venous pressure, fluid replacement and inotropic support. As the patient's hemostatic parameters were normal, catheter was placed into the right subclavian vein. Posterior-anterior chest radiograph (CR) was used to confirm catheterization site. It was found that catheter tip was not in normal position, right internal jugular vein (IJV) was directed and twisted in two places.
- **Case 2:** A 64-year-old patient with respiratory distress was conscious of consciousness. The patient's hemostasis parameters were normal and was placed central catheter into right internal jugular vein (IJV). It was seen by the CR that catheter tip was not in the correct position and it was directed to the right subclavian vein.

Discussion: One of the most common complications during CVC placement is malposition of the catheter. Placing a CVC is an invasive procedure and it should be remembered that various complications may develop during or after the placement. Moreover, practitioners should remember that malposition may not be noticed if no imaging and checking methods are used during CVC administration. It is important that the accuracy of the position of the CVC should be confirmed with post-procedure CR. Thus, any complications that require emergent intervention like malposition or pneumothorax can be detected early.

Keywords: Emergency Medicine, Penetrating Thoracic Trauma, Foreign Body.

Introduction

Central venous catheterization plays an important role in medical practice, and usually used in emergency departments, operating rooms and intensive care units for central venous pressure (CVP) monitoring, medications, fluid management, blood transfusion, parenteral nutrition and in complicated cases which require long term follow-up and a wide vein passage. The most common complications of central venous catheter (CVC) insertion are pneumothorax (up to 30%), infection (5% to 26%), and hematoma (2% to 26%)¹.

A less commonly defined yet important complication of CVC placement is malpositioning of the tip of the CVC in another vessel than the superior vena cava (SVC). This complication has been described in approximately 7% of cases of thoracic CVC placement in the literature. Before starting

to a catheterization procedure, risk factors that may cause malposition should be well-identified and after inserting a catheter chest radiograph (CR) should be performed to verify the location of the catheter². We aimed to point to the catheter malpositioning by presenting two cases.

Case Presentation:

Case 1: A 65-year-old male patient who returned as hypotensive after cardiopulmonary resuscitation was planned with CVC insertion for monitoring central venous pressure, fluid replacement and inotropic support. As the patient's hemostatic parameters were normal, catheter was placed into the right subclavian vein. After the procedure, blood was seen and detected. Posterior-anterior chest radiograph (CR) was used to confirm catheterization site and it was

Corresponding Author: Yavuz Katirci e-mail: yavuzkatirci25@gmail.com

Received: 30.05.2019 • **Accepted:** 24.07.2019

Cite this article as: Aydemir S, Katirci Y. Central venous catheter malposition: two case reports Eurasian J Critical Care. 2019;1(2):91-94

©Copyright 2018 by Emergency Physicians Association of Turkey - Available online at www.ejcritical.com

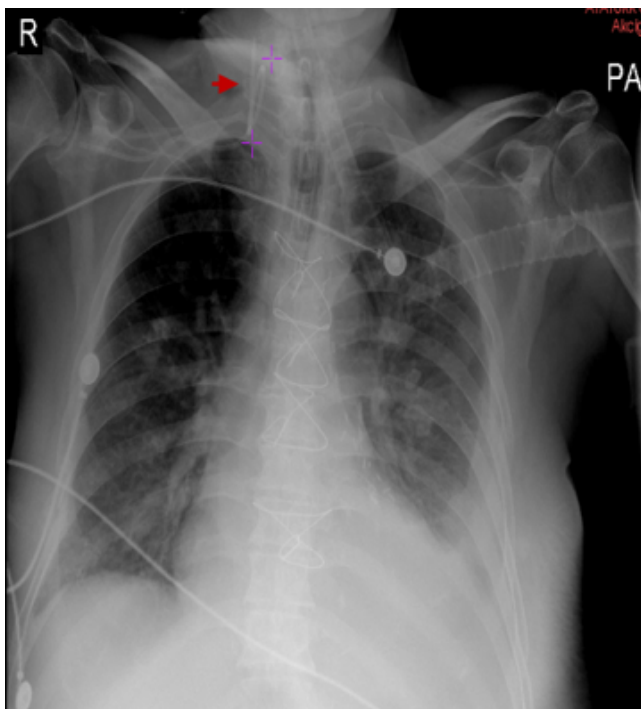


Figure 1: Chest radiograph showing a central line inserted in the right subclavian vein, catheter located at persistent right-internal jugular vein (arrow).

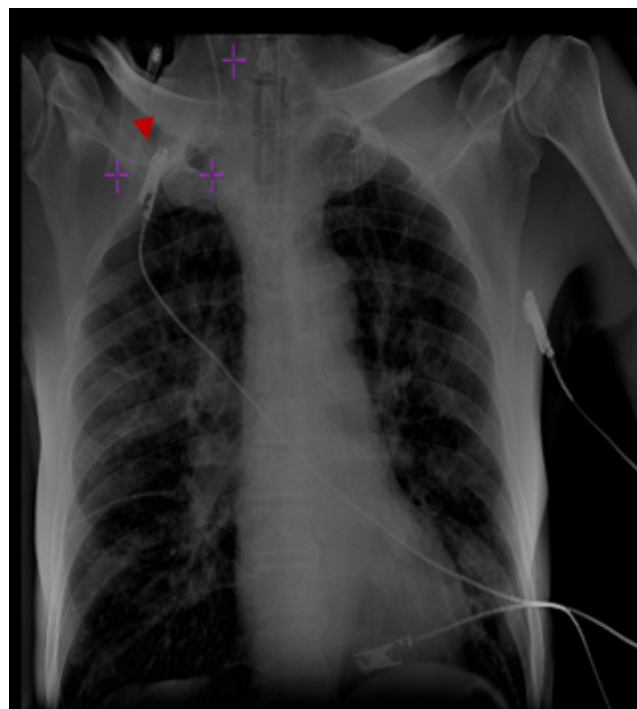


Figure 2: Chest radiograph showing a central line inserted in the right internal jugular vein, catheter located at persistent right subclavian vein (arrow).

seen that the tip of the catheter was not in right position by directing into the right Internal Jugular Vein (IJV) and circling. Therefore, the catheter was removed without any complication and inserted to another localization.

Case 2: A 64-year-old male patient admitted to emergency department with respiratory distress and altered mental status. Respiratory acidosis was seen in arterial blood gas analysis, therefore mechanical ventilation was initiated. As the patient's hemostatic parameters were normal, catheter was placed into the internal jugular vein (IJV). After the procedure, blood was seen and detected. Confirmation of the catheterization site by CR showed that the catheter tip was not in right position (Figure 2) by directing into the right subclavian vein. For this reason, the catheter was removed and inserted to another localization.

Discussion

The IJV is one of the most common sites that anesthesiologists use, and this site is chosen because CVC can be securely inserted in this location. Many of the complications may not be noticed, and many are not reported. Some complications may be life threatening or may cause morbidity, and some may not be recognized as a complication at all².

The incidence and occurrence of complications depend on various factors, such as the experience of the operator, the site of insertion, and the placement technique³.

CVC malpositions may lead to serious complications such as vascular stenosis and thrombosis depending on the location of the catheter. The incidence of catheter malposition varies from 3.3% to 14%. The right IJV is preferred because complications during the procedure and during follow-up are seen less than the other localizations. Left IJV, SCV or femoral vein are also used in cases where the right IJV cannot be used for various reasons⁴⁻⁶.

Beside some of other certain symptoms, the most common symptom that indicates CVC malpositioning is inefficient catheter function. Chest pain may occur in order to infuse fluid through a malpositioned CVC in small tributaries of large central veins. Pointing the tip of catheter cephalad in the internal jugular vein and/or infusing near the intracranial structures can produce an "ear gurgling" or "water running" feeling and headache. In addition, infusing hypertonic solutions through a brachial vein can produce shoulder or arm pain^{7,8}.

While the mechanisms of CVC malpositioning are not well understood, it seems to be multifactorial. Some studies have shown that upon needle insertion, the bevel orientation is helpful for the progression of the guide wire in the intended direction. There have been minor randomized controlled studies demonstrating an effect of slope of the needle orientation

in subclavian catheterizations, with a higher rate of correct placements when the slope of the needle was oriented caudally. Orienting the slope of the needle medially when attempting internal jugular vein insertion may maximize the success rate. True CVC placement should be clinically verified, and additionally confirmed with diagnostic imaging⁹. For providing a safe placement of CVC there are many techniques like marking on skin for estimating the length of catheter insertion, ultrasound/electrocardiography/echocardiography-guided localization of the vein. Additionally, it is quite important to confirm the position of the placed catheter by CR to see it located at atri-caval junction. Furthermore, this ensures to rule out the complications associated with the procedure¹⁰.

Conclusion

One of the most common complications during CVC placement is catheter malposition. Placing a CVC is an invasive procedure and it should be remembered that various complications may develop during or after the placement. Moreover, practitioners should remember that malposition may not be noticed if no imaging and checking methods are used during CVC administration. As we have seen in both cases, we performed CR as a routine after the procedure. Thus, we prevented possible complications before they emerged. We believe that X-ray is very useful in preventing possible complications in CVC interventions involving the neck and thorax. Thus, any complication (malposition, pneumothorax, etc.) that may require intervention can be detected early.

References

1. McGee DC and Gould MK. Preventing complications of central venous catheterization. *N Engl J Med.* 2003;348(12):1123-33.
2. Schummer W, Schummer C, Rose N, et al. Mechanical complications and malposition of central venous cannulations by experienced operators. A prospective study of 1794 catheterizations in critically ill patients. *Intensive Care Med.* 2007;33(6):1055-1059.
3. C.-C. Chen, P.-N. Tsao, and K.-I. Tsou Yau, "Paraplegia: complication of percutaneous central venous line malposition," *Pediatric Neurology*, vol. 24, no. 1, pp. 65–68, 2001.
4. Granata A, Figuera M, Castellino S, Logias F, Basile A. Azygos arch cannulation by central venous catheters for hemodialysis. *J Vasc Access* 2006;7:43-45.
5. Pikwer A, Bååth L, Davidson B, Perstoft I, Akeson J. The incidence and risk of central venous catheter malpositioning: a prospective cohort study in 1619 patients. *Anaesth Intensive Care* 2008;36:30-7.
6. Patel NH. Percutaneous translumbar placement of a Hickman catheter into the azygous vein. *AJR* 2000;175:1302-1304.
7. Webb JG, Simmonds SD, Chan-Yan C. Central venous catheter malposition presenting as chest pain. *Chest.* 1986;89(2):309-312.
8. Gilner LI. The "ear-gurgling" sign. *N Engl J Med.* 1977;296(22):1301.
9. Tripathi M, Dubey PK, Ambesh SP. Direction of the J-tip of the guidewire, in Seldinger technique, is a significant factor in misplacement of subclavian vein catheter: a randomized, controlled study. *Anesth Analg.* 2005;100(1):21-24
10. K.-S. Chu, J.-H. Hsu, S.-S. Wang et al., "Accurate central venous port-a catheter placement: intravenous electrocardiography and surface landmark techniques compared by using transesophageal echocardiography," *Anesthesia & Analgesia*, vol. 98, no. 4, pp. 910–914, 2004.
11. J.-H. Hsu, C.-K. Wang, K.-S. Chu et al., "Comparison of radiographic landmarks and the echocardiographic SVC/RA junction in the positioning of long-term central venous catheters," *Acta Anaesthesiologica Scandinavica*, vol. 50, no. 6, pp. 731–735, 2006.

