

ORIGINAL  
ARTICLE

 Mehmet Arıcan<sup>1</sup>  
 Erdem Değirmenci<sup>1</sup>

<sup>1</sup>Department of  
Orthopaedics and  
Traumatology, Düzce  
Faculty of Medicine, Düzce  
University, Düzce, Turkey

**Corresponding Author:**  
Mehmet Arıcan,  
Department of Orthopaedics  
and Traumatology, Düzce  
Faculty of Medicine, Düzce  
University, 81000, Düzce,  
Turkey  
Tel: +90 380 542 13 90 / 6532  
E-mail: ari\_can\_mehmet@hotmail.com

Received: 04.08.2019  
Acceptance: 19.09.2019  
DOI: 10.18521/kt.615442

Konuralp Medical Journal  
e-ISSN1309-3878  
konuralptipdergi@duzce.edu.tr  
konuralptipdergisi@gmail.com  
www.konuralptipdergi.duzce.edu.tr

## Improved Clinical Outcomes After Arthroscopic Microfracture in Isolated Medial Talar Osteochondral Lesions with a Single Injection of High Molecular Weight Hyaluronic Acid

### ABSTRACT

**Objective:** To investigate the effectiveness of a single intra-articular injection of high molecular weight hyaluronic acid (HMW-HA) for treating isolated medial osteochondral lesions (OCLs) of the talus following arthroscopic microfracture.

**Methods:** A total of 39 patients, treated between 2014–2017 for medial OCLs of the talus, were enrolled in the study. Patients were split into two groups: group 1, consisting of 18 patients who received a single injection of 4 ml of HMW-HA (22 mg/ml) injection following microfracture; and group 2, consisting of 21 patients who underwent microfracture but did not receive an injection. Clinical results were assessed at baseline, 6 months, and at a final follow-up using a visual analogue scale (VAS) and the American Orthopaedic Foot and Ankle Society Ankle-Hindfoot Scale (AOFAS).

**Results:** The mean AOFAS score increased in groups 1 and 2, from 45.61±14.71 to 95.11±5.02 (p=0.0001) and 41.81±13.83 to 90.29±7.43 (p=0.0001), respectively. Similarly, the average VAS score decreased in groups 1 and 2 from 8.72±1.23 to 2.11±1.45 (p=0.0001) and 9.05±0.80 to 3.67±2.22 (p=0.0001), respectively. In addition, the average AOFAS score in group 1 was higher than in group 2 (p=0.025) at the final follow-up, and the average VAS score in group 1 was lower than that of group 2 (p=0.0001, p=0.015, respectively) at 6 months postoperatively and the final follow-up.

**Conclusions:** Although both treatments for isolated medial OCL of the talus were associated with successful results, single-dose HMW-HA injection following arthroscopic microfracture was significantly more effective.

**Keywords:** Ankle Injuries, Cartilage, Arthroscopy, Hyaluronic Acid

## İzole Medial Talar Osteokondral Lezyonlarda Artroskopik Mikrokırık Sonrası Tek Doz Yüksek Moleküler Ağırlıklı Hyaluronik Asit Enjeksiyonunun Klinik Sonuçlara Pozitif Etkisi

### ÖZET

**Amaç:** Artroskopik mikrokırık sonrası talusun izole medial osteokondral lezyonlarının (OCL) tedavisinde tek doz eklem içi yüksek moleküler ağırlıklı hyaluronik asit (HMW-HA) enjeksiyonunun etkinliğinin araştırılması amaçlanmıştır.

**Gereç ve Yöntem:** Çalışmaya, 2014-2017 yılları arasında talusun medial OCL'leri tanısıyla tedavi edilen toplam 39 hasta dahil edildi. Hastalar, mikro kırık sonrası 4 ml HMW-HA (22 mg / ml) enjeksiyonu uygulanan 18 hasta (grup 1) ve mikro kırık uygulanmış, ancak enjeksiyon yapılmayan 21 hasta (grup 2) olmak üzere iki gruba ayrıldı. Klinik ve fonksiyonel sonuçlar tedaviden hemen önce, tedavinin 6. ayında ve son kontrolde Görsel Analog Skalası (VAS) ve Amerikan Ortopedik Ayak ve Ayak Bileği Skorlaması (AOFAS) ile değerlendirildi.

**Bulgular:** Ortalama AOFAS skoru 1. ve 2. grupta sırasıyla 45.61 ± 14.71'den 95.11 ± 5.02 (p = 0.0001) ve 41.81 ± 13.83'ten 90.29 ± 7.43'e (p = 0.0001) yükseldi. Benzer şekilde, ortalama VAS skoru 1. ve 2. grupta sırasıyla 8.72 ± 1.23'ten 2.11 ± 1.45'e (p = 0.0001) ve 9.05 ± 0.80'den 3.67 ± 2.22'ye (p = 0.0001) düşmüştür. Ek olarak, grup 1'deki ortalama AOFAS skoru, son kontrolde grup 2'den (p = 0.025) daha yüksekti ve grup 1'deki ortalama VAS skoru ameliyat sonrası 6. ayda ve son kontrolde grup 2'den daha düşüktü (p = 0.0001, p = 0.015, sırasıyla).

**Sonuç:** Her iki tedavi protokolünün de ağrı ve fonksiyon kaybında azalmaya katkısı olmasına rağmen, artroskopik mikrokırık sonrası tek doz HMW-HA enjeksiyonu önemli ölçüde daha etkili olmuştur.

**Anahtar Kelimeler:** Ayak Bileği Yaralanmaları, Kıkırdak, Artroskopisi, Hyaluronik Asit

## INTRODUCTION

Osteochondral lesion (OCL) of the talus is a common cause of ankle pain and instability after acute trauma or recurrent microtrauma (1). Although more than half of the total surface of the talus is covered with cartilage, OCL is more common in the medial talar dome, and restricted blood flow therein due to its large joint surface reduces the likelihood of healing after injury (2,3). Various treatment methods for OCL are available, ranging from conservative treatment, such as non-weight bearing short leg cast, to arthroscopic removal of loose bony fragments, antegrade or retrograde drilling, and/or bone graft (3-6). In recent years, arthroscopic microfracture techniques have been increasingly used as the primary treatment of talar OCL (2,7-10). With this technique, a fibrin clot forms in the chondral lesion site, and inflammation and healing begin with the stimulation of growth factors and cytokines (2,6,7,10,11). Many published studies have shown that intra-articular biological agents, such as hyaluronic acid (HA), platelet-rich plasma (PRP), and bone marrow aspirates positively affect chondrocyte growth and differentiation (12-15). Of these, HA has become the nonoperative treatment of choice for OCL over the past two decades because of its ability to restore viscoelasticity, stimulate the differentiation of chondrocytes, exert synovial anti-inflammatory effects, reduce pain, and increase function (12,16,17). However, the parameters that constitute best practice are still unknown, including single versus multiple doses, the ideal injection frequency, and high versus low molecular weight HA (18-20). While 3-5 intra-articular injections of low to medium weight HA per week have been shown to be effective in previous studies (13,15,18,21) evidence regarding the efficacy of a single injection is limited. The purpose of this current study was to investigate the efficacy of single injection of high molecular weight hyaluronic acid (HMW-HA) for treatment of isolated medial OCL of the talus following microfracture in patients who were resistant to conservative treatment modalities.

## MATERIAL AND METHODS

**Patients:** This retrospectively designed study examined 42 patients who were treated with arthroscopic microfracture between January 2014 and July 2017 for medial OCL of the talus. The study was performed in accordance with the Declaration of Helsinki ethical principles for medical research involving human subjects and was approved by the Ethical Committee of the Medical School of Düzce University, Düzce, Turkey in 2018 (approval no. 2018/226). Written informed consents of patients were obtained before the onset of study.

A total of 39 patients who met our inclusion criteria were included in this present study: 1)

symptomatic medial OCL of the talus revealed by magnetic resonance imaging (MRI); 2) aged between 18 and 55 years; 3) lesion < 1.5 cm<sup>2</sup> in size; 4) unilateral lesion; 5) unresponsive to conservative treatments; and 6) underwent MRI as part of the final follow-up examination. Patients who were pregnant, undergoing anticoagulant treatment, or allergic to HA; had acute inflammation, blood-clotting disorders, an active infection, previous ankle surgery, severe ligament instability, or ipsilateral, posterior or diffuse chondral lesions; or had any injection like platelet rich plasma or an autologous blood in the last 6 months were excluded.

According to our criteria; three patients were excluded due to age (n = 2) and platelet rich plasma injection in the last 6 months (n = 1). A total of 39 patients were assigned to one of two groups: group 1 included 18 patients who received a single-dose HMW-HA injection 2 weeks following microfracture; and group 2 included 21 patients who were treated only by microfracture. Demographic data, including age, sex, duration of symptoms, body mass index (BMI), follow-up time, aetiology, lesion size and sides were recorded.

**Surgery:** Arthroscopic procedures were performed under general anaesthesia in the supine position using an upper thigh tourniquet and a thigh holder and a blunt trocar with arthroscope were inserted through standard anteromedial and anterolateral portals. The lower extremity was draped and prepared according to a standard sterile procedure and approximately 15 ml of saline solution was injected to routinely distend the joint cavity. Firstly the blunt trocar was advanced into the anteromedial portal. Hypertrophic and inflamed synovial tissues were removed with a shaver. After the OCL was visually confirmed, the arthroscope moved from the anteromedial portal to the anterolateral one. Maximum plantar flexion without distraction was used to assess the talar dome. A marked probe was introduced into the anterolateral portal to raise the unstable cartilage from the base; the stability and cartilage continuity of the lesion were determined. An arthroscopic shaver was used for the debridement of loose flaps of cartilage. Then, lesion size was measured according to the marked probe. A microfracture pick was used to create several small holes in the subchondral bone through the anteromedial portal. Hole depth sufficiency was determined according to the release of fatty droplets.

Following closure, the ankle was bandaged in dry sterile dressings and wrapped in an elastic bandage.

**Rehabilitation Protocol:** All patients completed the same postoperative physiotherapy regimen. Patients were advised to apply cold pack for 20 minutes five times in a day for 2 weeks. Active forward flexion, extension, abduction, adduction, and rotation were started on postoperative day 1 without weight bearing, and weight-bearing restrictions persisted for 4 weeks. At the end of postoperative week 4, the patient was allowed to gradually increase weight bearing and progressive physiotherapy was continued.

**HA Administration:** Patients in group 1 received HMW-HA injections after 2 weeks from the surgery, delivered in an outpatient clinic using an aseptic technique, and any adverse effects were recorded. The injections were administered by a single experienced surgeon (MA) who did not participate in the clinical assessments of the patients, or in the data analysis.

**Outcome Measurements:** Measurement of patient outcomes was performed by the author (ED), who did not take part in the treatment procedures like surgery or injection to ensure minimum bias. Clinical and functional outcomes were assessed at baseline, 6 months, and the final follow-up using a visual analogue scale (VAS) and the American Orthopaedic Foot and Ankle Society Ankle-Hindfoot Scale (AOFAS). The VAS can be used for measuring pain, which is somewhat difficult to quantify objectively. The simplest type of VAS is a straight horizontal line, typically 100 mm in length. The AOFAS measures function, pain, and alignment; the total possible score is 100 points (40 points for pain; 50 points for function and 10 points for alignment). Higher scores represent better outcomes.

**Statistical Analysis:** Statistical analyses were performed using NCSS 2007 software for Windows (NCSS, Kaysville, UT, USA). In addition to standard descriptive statistical analysis (mean and standard deviation, median, interquartile range), groups were compared regarding normally distributed variables with an independent t-test; one-way analysis of variance (ANOVA) was used for time-dependent comparison of variables, and the Newman Keuls post-hoc multiple comparison test was used to compare time subgroups. Non-parametric data were analysed with the Mann Whitney U test, and the chi-square test was used to analyse categorical data. A p-value < 0.05 was considered significant.

## RESULTS

A total of 39 patients who met our inclusion criteria were enrolled: there were 18 patients in group 1 (10 [55.56%] males and 8 [44.44%] female; mean age,  $40.06 \pm 12.47$  years [19–55 years]) and 21 patients (11 [52.38%] males and 10 [47.62%] females; mean age,  $38.33 \pm 12.35$  years [20–55 years]) in group 2. In group 1, the right ankle was affected in 6 (33.33%) patients and the left ankle was affected in 12 (66.67%) patients. In group 2, the right ankle was affected in 12 (57.14%) patients and the left ankle was affected in 9 (42.86%) patients. The mean symptom duration was  $10.39 \pm 4.69$  months (6–24 months) in group 1 and  $9.62 \pm 3.14$  months (6–18 months) in group 2. The mean follow-up duration was  $31.61 \pm 14.02$  months (16–56 months) in group 1 and  $28.93 \pm 10.7$  months (16–53 months) in group 2. The mean BMI was  $26.31 \pm 3.48$  (22.80–33.30) in group 1 and  $26.48 \pm 3.28$  (22.10–31.90) in group 2. The aetiology of OCL included ankle sprain (n = 3, 16.67%), sports injury (n = 3, 6.67%), trauma (n = 5, 27.78%) and unknown (n = 7, 38.89%) in group 1, and ankle sprain (n = 2, 9.52%), sports injury (n = 2, 9.52%), trauma (n = 3, 14.29%) and unknown (n = 14, 66.67%) in group 2. The average lesion size was  $1.10 \pm 0.19$  cm<sup>2</sup> (0.80–1.40 cm<sup>2</sup>) in group 1 and  $1.07 \pm 0.22$  cm<sup>2</sup> (0.80–1.50 cm<sup>2</sup>) in group 2.

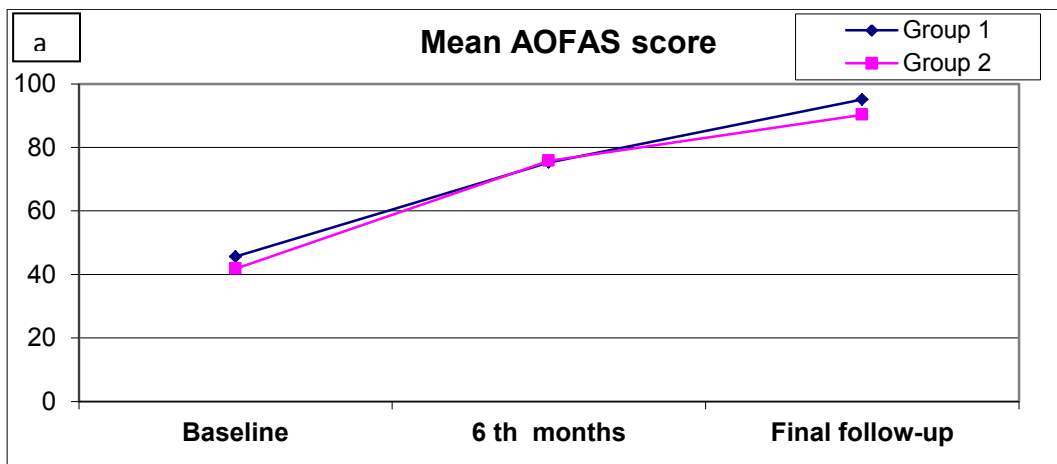
No significant differences in mean age, sex, BMI, mean symptom duration, mean follow-up time, affected side, aetiology, or lesion size were observed between both of the groups (p > 0.05) (Table 1).

At the final follow-up, the average AOFAS score increased in group 1 from  $45.61 \pm 14.71$  to  $95.11 \pm 5.02$  (p = 0.0001), and in group 2 from  $41.81 \pm 13.83$  to  $90.29 \pm 7.43$  (p = 0.0001). The average VAS score decreased in group 1 from  $8.72 \pm 1.23$  to  $2.11 \pm 1.45$  (p = 0.0001) and in group 2 from  $9.05 \pm 0.80$  to  $3.67 \pm 2.22$  (p = 0.0001). While there was no statistically significant difference in mean AOFAS score between groups 1 and 2, at baseline or at 6 months postoperatively (p = 0.411 and p = 0.905, respectively), the mean AOFAS score in group 1 was significantly higher than in group 2 at the final follow-up (p = 0.025). In addition, while there was no statistically significant difference in mean VAS score between groups 1 and 2 at baseline (p = 0.328), although the mean VAS score of group 1 was significantly lower than that of group 2 at both 6 months postoperatively and the final follow-up (p = 0.0001 and p = 0.015, respectively) (Fig. 1a,b and Table 2).

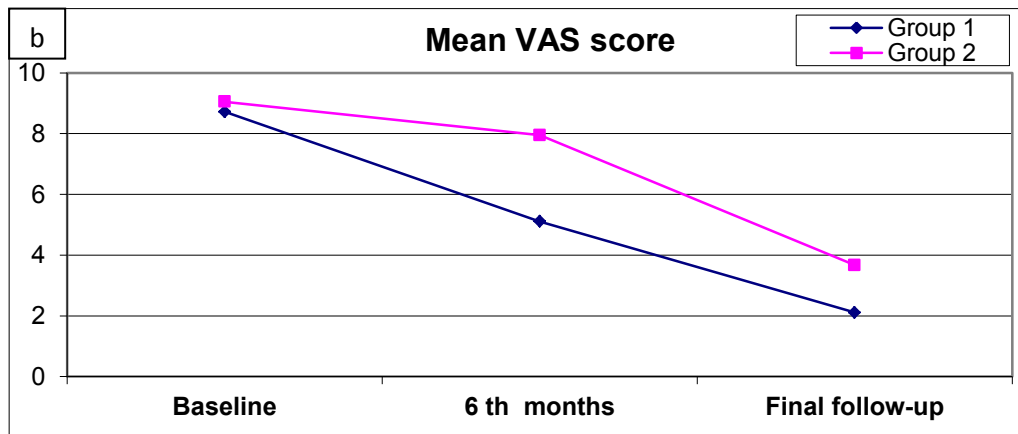
**Table 1.** Summary of patients demographics and clinical characteristics at baseline between group 1 (injection) and group 2 (non-injection).

		Group 1 (n:18)		Group 2 (n:21)		p
Age(mean±SD[years])		40,06±12,47		38,33±12,35		0,668*
Sex	Male	10	55,56%	11	52,38%	0,843+
	Female	8	44,44%	10	47,62%	
BMI(mean±SD [kg/m <sup>2</sup> ])		26,31±3,48		26,48±3,28		0,880*
Symptom durations (mean±SD [months])		10,39±4,69		9,62±3,14		0,546*
Follow-up duration (mean±SD [months])		31,61±14,02		28,93±10,7		0,503*
Affected side	Right	6	33,33%	12	57,14%	0,137+
	Left	12	66,67%	9	42,86%	
Etiology	Ankle sprain	3	16,67%	2	9,52%	0,430+
	Unknown	7	38,89%	14	66,67%	
	Sports injury	3	16,67%	2	9,52%	
	Trauma	5	27,78%	3	14,29%	
Lezyon Size (mean±SD[cm <sup>2</sup> ])		1,10±0,19		1,07±0,22		0,377+

\* Independent t test, + Chi Square test, SD; Standard deviation, BMI; Body mass index



AOFAS; American Orthopaedic Foot and Ankle Society Ankle-Hind Foot Scale



VAS; Visual Analogue Scale

**Figure 1** a, b. a; Mean AOFAS score from baseline at 6<sup>th</sup> months and final follow-up. b; Mean VAS score from baseline at 6<sup>th</sup> months and final follow-up.

**Table 2.** Baseline, 6<sup>th</sup> months and final follow-up mean AOFAS –VAS score between group 1 (injection) and group 2 (non-injection).

		Group 1 (n:18)	Group 2 (n:21)	p*
AOFAS	Baseline	45,61±14,71	41,81±13,83	0,411
	6 <sup>th</sup> months	75,28±13,44	75,76±11,83	0,905
	Final follow-up	95,11±5,02	90,29±7,43	0,025
	p ‡	0,0001	0,0001	
VAS	Baseline	8,72±1,23	9,05±0,80	0,328
	6 <sup>th</sup> months	5,11±1,78	7,95±1,12	0,0001
	Final follow-up	2,11±1,45	3,67±2,22	0,015
	p ‡	0,0001	0,0001	

Newman Keuls Multiple Comparison Test	AOFAS		VAS	
	Grup 1	Grup 2	Grup 1	Grup 2
Baseline / 6 <sup>th</sup> months	0,0001	0,0001	0,0001	0,0001
Baseline / Final follow-up	0,0001	0,0001	0,0001	0,0001
6 <sup>th</sup> months / Final follow-up	0,0001	0,0001	0,0001	0,0001

\* Independent t test , ‡ Matched One-Way Variance Analysis, AOFAS; American Orthopaedic Foot and Ankle Society Ankle-Hind Foot Scale, VAS; Visual Analogue Scale, ±; Standard deviation

No statistically significant difference in the change in AOFAS score between baseline and 6 months postoperatively, baseline and the final follow-up, or 6 months postoperatively and the final follow-up was observed between groups 1 and 2 ( $p > 0.05$ ). While there was no statistically significant difference in the mean change in VAS score between baseline and the final follow-up, or between 6 months postoperatively and the final follow-up between groups 1 and 2 ( $p > 0.05$ ), the change in VAS score between baseline and 6 months postoperatively was significantly greater in group 1 ( $p = 0.0001$ ) (Table 3).

In addition, we performed MRI of the OCL, with or without HMW-HA injection at baseline and the final follow-up; we did not observe any significant differences in appearance on MRI appearance between baseline and final-follow up.

No intraoperative, perioperative, or postoperative complications, such as infection, wound problems, deep vein thrombosis, postoperative ankle stiffness, or neurological damage were reported. In addition, the single-dose HMW-HA injection was well tolerated and no serious adverse effects were observed.

**Table 3.** Comparison of mean change in values of AOFAS and VAS score from baseline at 6<sup>th</sup> months, baseline at final follow-up and 6<sup>th</sup> months at final follow-up.

Mean differences		Group 1 (n:18)	Group 2 (n:21)	p‡
AOFAS	Baseline-6 <sup>th</sup> months	-29,67±18,76	-33,95±18,26	0,444
	Baseline- Final follow-up	-49,5±14,11	-48,48±18,06	0,899
	6 <sup>th</sup> months - Final follow-up	-19,83±12,41	-14,52±12,9	0,117
VAS	Baseline-6 <sup>th</sup> months	3,61±1,24	1,10±1,00	0,0001
	Baseline- Final follow-up	6,61±1,61	5,38±2,13	0,057
	6 <sup>th</sup> months - Final follow-up	3,00±1,75	4,29±2,33	0,060

‡Mann Whitney U test, AOFAS; American Orthopaedic Foot and Ankle Society Ankle-Hind Foot Scale, VAS; Visual Analogue Scale, ±; Standard deviation

## DISCUSSION

Due to the fact that more than half of the total surface of the talus is covered by cartilage, its nutrition supply is limited such that healing of OCLs is difficult (3,5,11). The treatment choice varies based on clinical presentation and the location and size of the lesion (18,21-23). Recently, arthroscopic debridement, drilling, and microfracture have been used as first-line treatments for symptomatic OCLs smaller than 1.5 cm<sup>2</sup> in diameter that are unresponsive to conservative treatment (2,8,10,11). The primary aim of bone marrow stimulation is to create multiple holes, at 3–4 mm intervals, which reach the subchondral area after curettage and debridement of the lesion region. Sufficient depth is indicated by the appearance of fatty droplets (7-9). After this process, pluripotent mesenchymal cells are deposited in the lesion site.

The role and effects of arthroscopic microfracture on OCL of the talus have been examined in some clinical studies (2,8-11). There is general agreement that this technique is minimally invasive and not technically demanding, with both low complication rates and low cost. In addition, good to excellent clinical and functional results can be achieved in more than 80% of patients, especially in the case of small lesions (< 1.5 cm<sup>2</sup>) (9,10,23). Park et al. evaluated clinical and functional results of microfracture for OCL of the talus. They compared 58 patients with talar OCL to 46 patients with OCL who underwent microfracture. The patients were evaluated using a VAS, and the AOFAS, in terms of pain and function. At the mean 38.3-month follow-up, it was found that microfracture significantly improved clinical outcomes (9). In another study, Lee et al. examined 35 patients aged < 50 years who underwent microfracture for OCL of the talus (< 1.5 cm<sup>2</sup>; mean follow-up, 33 months). The evaluation of patients was made with a VAS, the AOFAS, and the AAS in terms of pain and function. It was concluded that arthroscopic microfracture for isolated OCL of the talus is a safe and effective procedure that yields good clinical outcomes in the majority of patients (24). Similarly, Choi et al. compared the clinical and functional results between microfracture and drilling for talar OCL. The authors compared 50 patients who underwent microfracture to 40 who underwent drilling; their results were similar to those of Park et al. (10). In the present study, we examined 39 patients who underwent arthroscopic microfracture for isolated medial OCL of the talus. Despite the short follow-up time in our work, our results were in accordance with previous studies. Regarding the results at the final follow-up, statistically significant improvements in the VAS and AOFAS scores were seen compared to the preoperative values ( $p < 0.05$ ).

Despite the good and excellent results obtained in most of the studies, poor outcomes of arthroscopic microfracture for OCL of the talus were

reported in a few studies (7,23,25). One such study, by Cuttica et al., evaluated the presence of postoperative oedema on MRI following microfracture for OCL of the talus, and correlated the MRI findings and clinical outcomes in a total of 29 patients with 30 OCL after a mean follow-up of 81.47 weeks. They found that patients with moderate to severe oedema had inferior clinical outcomes (25). In the current study, we performed MRI immediately before treatment, and at the final follow-up, in all patients. Our results showed that arthroscopic microfracture for OCL of the talus, with or without HMW-HA, did not cause a change in appearance on MRI at the final follow-up. However, the VAS pain and AOFAS scores were not correlated with appearance on MRI.

Clinically, HA for musculoskeletal disorders is mainly applied for OCL of the knee (26-28) and ankle (13-16,18,19,21,29-31). Most studies have reported that HA has potential advantages including restoration of viscoelasticity, stimulation of chondrocytes, reduction of pain, increase in function, and anti-inflammatory effects on the synovium (12,17,28). Although, good to excellent results obtained in most studies within the short- or mid-term postoperative period, there is no gold standard method of HA administration for OCL of the talus (13,15,18-21,29). High versus low molecular weight HA, single versus multiple doses, injection time and frequency, and the use of local anaesthesia all remain controversial (18-20). There have been numerous studies on the use of 3–5 weekly intra-articular low to medium weight HA injections for talar OCL following microfracture (13,15,18, 21), but evidence regarding the efficacy of a single HMW-HA injection is limited. A recent prospective randomized controlled study confirmed the clinical benefit of single-dose intra-articular HMW-HA in the treatment of knee pain due to osteoarthritis (32). However, to our knowledge no well-controlled study concerning OCL of the talus has been published. In this current study, the results of patients who diagnosed with isolated medial OCL of the talus were compared, treated either with microfracture with or without a single intra-articular HMW-HA injection at 2 weeks postoperatively. Regarding the clinical and functional outcomes after a mean follow-up time of  $31.61 \pm 14.02$  months (range: 16–56 months), significantly greater improvements in the VAS pain and AOFAS scores were observed in group 1 versus group 2 compared to the preoperative status ( $p < 0.05$ ). Based on these results, we recommend single-dose intraarticular HMW-HA injection for the treatment of isolated medial OCL of the talus as an adjunct to microfracture.

Some studies have reported that different HA management protocols for OCL of the talus yield good to excellent clinical outcomes at short- or mid-

term follow-ups (13,15,18,21,29). For example, Doral et al. performed a comparative prospective randomized controlled single-blind study of arthroscopic microfracture with HA and microfracture alone for 24 months; 41 patients received an intra-articular injection of half-dose HA (25 mg / 2.5 MI) weekly starting at 3 weeks postoperatively, while another 16 patients did not receive any injection. They reported that treatment of OCL of the talus (lesion size < 20 mm<sup>2</sup>) using microfracture significantly improved postoperative functional and pain scores, and that adjunctive treatment with intra-articular HA injection may result in better clinical outcomes over microfracture alone (18). In the present study, our results were concordant with previous reports on single-dose intra-articular HMW-HA injection as an adjunctive treatment for isolated medial OCL of the talus following microfracture.

Some minor complications associated with arthroscopic microfracture for talar OCL have been discussed in the literature, including continued pain, nerve injury (superficial or deep peroneal, sural or saphenous nerve), infection, or deep vein

thrombophlebitis (33). These complications were not seen in our study; in fact there were no reported intraoperative, perioperative, or postoperative complications. In addition, the single-dose HMW-HA injection was well tolerated and no serious adverse effects, such as allergic reaction, were observed.

This present study is not without some limitations. Firstly, it was retrospective and examined only short-term results of patients. Also it was performed at a single centre and population of patients were relatively small.

#### CONCLUSION

Although both treatment modalities decreased pain and improved the clinical outcomes, single-dose intra-articular HMW-HA injection after arthroscopic microfracture was superior to microfracture alone. In addition, considering the morbidity associated with multiple injections to the ankle after microfracture, based on the results of this study we recommend single-dose intra-articular HMW-HA injection as an alternative to multiple injections. Further prospective-multicentre studies with larger patient samples are needed to optimize HA treatment protocols after microfracture for talar OCL.

#### REFERENCES

1. Waterman BR, Owens BD, Davey S, et al. Belmont PJ Jr. The epidemiology of ankle sprains in the United States. *J Bone Joint Surg Am.* 2010;92(13):2279-84.
2. Donnenwerth MP, Roukis TS. Outcome of arthroscopic debridement and microfracture as the primary treatment for osteochondral lesions of the talar dome. *Arthroscopy.* 2012;28(12):1902-7.
3. Tol JL, Struijs PA, Bossuyt PM, et al. Treatment strategies in osteochondral defects of the talar dome: a systematic review. *Foot Ankle Int.* 2000;21(2):119-26.
4. Zengerink M, Struijs PA, Tol JL, et al. Treatment of osteochondral lesions of the talus: a systematic review. *Knee Surg Sports Traumatol Arthrosc.* 2010;18(2):238-46.
5. Murawski CD, Kennedy JG. Operative treatment of osteochondral lesions of the talus. *J Bone Joint Surg Am.* 2013;95(11):1045-54.
6. Looze CA, Capo J, Ryan MK, et al. Evaluation and Management of Osteochondral Lesions of the Talus. *Cartilage.* 2017;8(1):19-30.
7. Murawski CD, Foo LF, Kennedy JG. A Review of Arthroscopic Bone Marrow Stimulation Techniques of the Talus: The Good, the Bad, and the Causes for Concern. *Cartilage.* 2010;1(2):137-44.
8. Lee KB, Bai LB, Yoon TR, et al. Second-look arthroscopic findings and clinical outcomes after microfracture for osteochondral lesions of the talus. *Am J Sports Med.* 2009;37 Suppl 1:63S-70S.
9. Park HW, Lee KB. Comparison of chondral versus osteochondral lesions of the talus after arthroscopic microfracture. *Knee Surg Sports Traumatol Arthrosc.* 2015;23(3):860-7.
10. Choi JI, Lee KB. Comparison of clinical outcomes between arthroscopic subchondral drilling and microfracture for osteochondral lesions of the talus. *Knee Surg Sports Traumatol Arthrosc.* 2016;24(7):2140-7.
11. Chuckpaiwong B, Berkson EM, Theodore GH. Microfracture for osteochondral lesions of the ankle: outcome analysis and outcome predictors of 105 cases. *Arthroscopy.* 2008;24(1):106-12.
12. Hegewald AA, Ringe J, Bartel J, et al. Hyaluronic acid and autologous synovial fluid induce chondrogenic differentiation of equine mesenchymal stem cells: a preliminary study. *Tissue Cell.* 2004;36(6):431-8.
13. Görmeli G, Karakaplan M, Görmeli CA et al. Clinical Effects of Platelet-Rich Plasma and Hyaluronic Acid as an Additional Therapy for Talar Osteochondral Lesions Treated with Microfracture Surgery: A Prospective Randomized Clinical Trial. *Foot Ankle Int.* 2015;36(8):891-900.
14. Kon E, Mandelbaum B, Buda R, et al. Platelet-rich plasma intra-articular injection versus hyaluronic acid viscosupplementation as treatments for cartilage pathology: from early degeneration to osteoarthritis. *Arthroscopy.* 2011;27(11):1490-501.
15. Mei-Dan O, Carmont MR, Laver L, et al. Platelet-rich plasma or hyaluronate in the management of osteochondral lesions of the talus. *Am J Sports Med.* 2012;40(3):534-41.

16. Murphy EP, Curtin M, Mc Goldrick NP, et al. Prospective Evaluation of Intra-Articular Sodium Hyaluronate Injection in the Ankle. *J Foot Ankle Surg.* 2017;56(2):327-331.
17. Akmal M, Singh A, Anand A, et al. The effects of hyaluronic acid on articular chondrocytes. *J Bone Joint Surg Br.* 2005;87(8):1143-9.
18. Doral MN, Bilge O, Batmaz G, et al. Treatment of osteochondral lesions of the talus with microfracture technique and postoperative hyaluronan injection. *Knee Surg Sports Traumatol Arthrosc.* 2012;20(7):1398-403.
19. Salk RS, Chang TJ, D'Costa WF, et al. Sodium hyaluronate in the treatment of osteoarthritis of the ankle: a controlled, randomized, double-blind pilot study. *J Bone Joint Surg Am.* 2006;88(2):295-302.
20. Sun SF, Hsu CW, Sun HP, et al. The effect of three weekly intra-articular injections of hyaluronate on pain, function, and balance in patients with unilateral ankle arthritis. *J Bone Joint Surg Am.* 2011;93(18):1720-6.
21. Shang XL, Tao HY, Chen SY, et al. Clinical and MRI outcomes of HA injection following arthroscopic microfracture for osteochondral lesions of the talus. *Knee Surg Sports Traumatol Arthrosc.* 2016;24(4):1243-9.
22. D'Ambrosi R, Maccario C, Serra N, et al. Relationship between symptomatic osteochondral lesions of the talus and quality of life, body mass index, age, size and anatomic location. *Foot Ankle Surg.* 2018;24(4):365-372.
23. Choi WJ, Park KK, Kim BS, et al. Osteochondral lesion of the talus: is there a critical defect size for poor outcome? *Am J Sports Med.* 2009;37(10):1974-80.
24. Lee KB, Bai LB, Chung JY, et al. Arthroscopic microfracture for osteochondral lesions of the talus. *Knee Surg Sports Traumatol Arthrosc.* 2010;18(2):247-53.
25. Cuttica DJ, Shockley JA, Hyer CF, et al. Correlation of MRI edema and clinical outcomes following microfracture of osteochondral lesions of the talus. *Foot Ankle Spec.* 2011;4(5):274-9.
26. Wobig M, Bach G, Beks P, et al. The role of elastoviscosity in the efficacy of viscosupplementation for osteoarthritis of the knee: a comparison of hylan G-F 20 and a lower-molecular-weight hyaluronan. *Clin Ther.* 1999;21(9):1549-62.
27. Conrozier T, Jerosch J, Beks P, et al. Prospective, multi-centre, randomised evaluation of the safety and efficacy of five dosing regimens of viscosupplementation with hylan G-F 20 in patients with symptomatic tibio-femoral osteoarthritis: a pilot study. *Arch Orthop Trauma Surg.* 2009;129(3):417-23.
28. Watterson JR, Esdaile JM. Viscosupplementation: therapeutic mechanisms and clinical potential in osteoarthritis of the knee. *J Am Acad Orthop Surg.* 2000;8(5):277-84.
29. Strauss E, Schachter A, Frenkel S, et al. The efficacy of intra-articular hyaluronan injection after the microfracture technique for the treatment of articular cartilage lesions. *Am J Sports Med.* 2009;37(4):720-6.
30. Sun SF, Chou YJ, Hsu CW, et al. Efficacy of intra-articular hyaluronic acid in patients with osteoarthritis of the ankle: a prospective study. *Osteoarthritis Cartilage.* 2006;14(9):867-74.
31. De Groot H 3rd, Uzunishvili S, Weir R, et al. Intra-articular injection of hyaluronic acid is not superior to saline solution injection for ankle arthritis: a randomized, double-blind, placebo-controlled study. *J Bone Joint Surg Am.* 2012;94(1):2-8.
32. Sun SF, Hsu CW, Lin HS, et al. Comparison of Single Intra-Articular Injection of Novel Hyaluronan (HYA-JOINT Plus) with Synvisc-One for Knee Osteoarthritis: A Randomized, Controlled, Double-Blind Trial of Efficacy and Safety. *J Bone Joint Surg Am.* 2017;99(6):462-471.
33. Deng DF, Hamilton GA, Lee M, et al. Complications associated with foot and ankle arthroscopy. *J Foot Ankle Surg.* 2012;51(3):281-4