



Case Report

J. Exp. Clin. Med., 2018; 35(2): 53-55
doi: 10.5835/jecm.omu.35.02.006



Twin pregnancy in a woman with hypogonadotropic hypogonadism and uterus didelphys: A case report and literature review

Hasan Ulubaşoğlu^{a*}, Sertaç Batioğlu^b, Davut Güven^c

^a Department of Obstetrics and Gynecology, Faculty of Medicine, Education and Training Hospital, Samsun, Turkey

^b Department of Obstetrics and Gynecology, Faculty of Medicine, Kolan Hospital, İstanbul, Turkey

^c Department of Obstetrics and Gynecology, Faculty of Medicine, Ondokuz Mayıs University, Medical Faculty, Samsun, Turkey

ARTICLE INFO

ABSTRACT

Article History

Received 26 / 04 / 2016
Accepted 20 / 06 / 2016
Online Published Date 25 / 10 / 2019

* Correspondance to:

Hasan Ulubasoglu
Department of Obstetrics and
Gynecology,
Faculty of Medicine,
Education and Training Hospital,
Samsun, Turkey
e-mail: h.ulubas@hotmail.com

Hypogonadotropic hypogonadism is a rarely seen medical condition arising from absence or decrease of hypothalamic pituitary function. Hormone plasma concentrations are either can not be determined or are at very low rates. Uterus didelphys is a congenital uterine about medial fusion defects of mullerian ducts. A 22-year-old female patient applied to our clinic due to premier infertility. The diagnosis of uterus didelphys was confirmed as a result of hysterosalpingography. Recombinant FSH was started on ovulation induction. In the transvaginal ultrasonography performed 3 weeks later, 2 gestational sacs and fetal heartbeats in both cavities were observed. After cesarean operation, strassmann procedure was performed and both cavities were combined in the same session.

Keywords:

Cesarean
Hypogonadotropic hypogonadism
Infertility
Uterus didelphys

© 2018 OMU

1. Introduction

Hypogonadotropic hypogonadism is a rarely seen medical condition arising from absence or decrease of hypothalamic pituitary function. In hypogonadotropic hypogonadism, follicle stimulating hormone (FSH) and luteinizing hormone (LH) plasma concentrations are either can not be determined or are determined at very low rates (Awwad et al, 2013).

Uterus didelphys is a congenital uterine abnormality

caused by medial fusion defects of mullerian ducts. Women with abnormality of uterus didelphys need infertility treatment more frequently than those with other uterine abnormalities. Moreover, multiple pregnancy is a rarely seen condition in the women with uterus didelphys (Bhattacharya and Mistri, 2010). We presented twin pregnancy in a woman with uterus didelphys and hypogonadotropic hypogonadism after ovulation induction with gonadotropin. On the 3rd

day of menstruation, 75 IU/day recombinant FSH was started on ovulation induction. The diagnosis of uterus didelphys was confirmed as a result of hysterosalpingography and radiopaque material was present in both bilateral fallopian tubes. On the 3rd day of menstruation, 75 IU/day recombinant FSH was started on ovulation induction. The diagnosis of uterus didelphys was confirmed as a result of hysterosalpingography and radiopaque material was present in both bilateral fallopian tubes. On the 3rd day of menstruation, 75 IU/day recombinant FSH was started on ovulation induction.

2. Case

A 22-year-old female patient applied to our clinic due to primary infertility. The patient had been married for 3 years and had never received infertility treatment. Spontaneous menstruation was not realizing in her anamnesis and she was taking combined oral contraceptive for menstruation.

In her gynecological examination, longitudinal vaginal septum and two cervical dilations were observed. The laboratory findings of the patient (FSH: 0.1 mIU/ml, LH: 0.1 mIU/ml, estradiol: E2:3 pg/ml) were compatible with hypogonadotropic hypogonadism. The diagnosis of uterus didelphys was confirmed as a result of hysterosalpingography and radiopaque material was present in both bilateral fallopian tubes. On the 3rd day of menstruation, 75 IU/day recombinant FSH was started on ovulation induction. The dose was increased as 150 IU on the 7th day of the cycle. Due to the observation of 2 dominant follicles with approximately 18-mm length in the transvaginal ultrasonography made on the 14th day of the cycle, and the determination of E2 value as 650 pg/ml, recombinant human chorionic gonadotropin (hCG) was administered subcutaneously. 36 hours later, intrauterine insemination was performed. In the transvaginal ultrasonography performed 3 weeks later, 2 gestational sacs and fetal heartbeats in both cavities were observed. Her pregnancy follow-ups were normal. Antenatal screening tests were not performed. The patient was admitted in our hospital with regular and painful uterine contractions in the 34th gestational week. In her vaginal examination, 3-cm cervical dilation and effacement of 60 % were observed. In the 34th week, elective cesarean operation was performed through bilateral sub-segment transverse incision. Strassmann procedure was performed and both cavities were combined in the same session (Fig. 1). Weights of the first and the second infants were relatively 1900 and 2000g. Apgar scores were 7/8. The infants did not need neonatal intensive care. No preoperative complication developed. Postoperative period was normal. She and her infants were discharged on the 6th postoperative day without any complication.

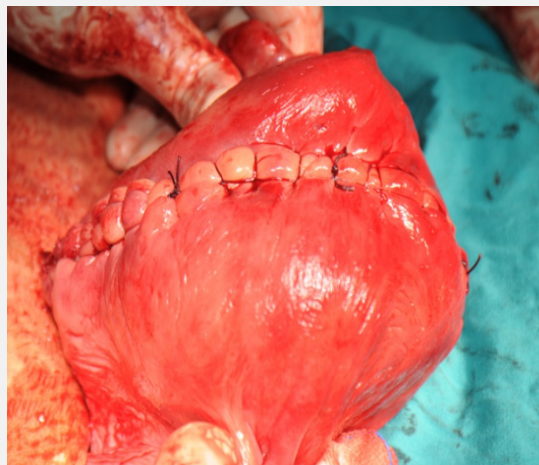


Fig. 1. Strassmann metroplasty.

3. Discussion

It is quite hard to determine the incidence of müllerian abnormalities in general population. The most common ones are uterus didelphys, bicornuate uterus, and unicornuate uterus (Meiling et al., 2011). Most of these congenital abnormalities are defined as a potential cause of fetal malpresentation, preterm labor, recurrent pregnancy wastage, and infertility (Chan et al., 2011). In our case, the labor was preterm but malpresentation did not occur. Reproductive performance of uterus didelphys is rather low (Raga et al., 1997). Most authors had different thoughts on the obstetric results of uterus didelphys. According to some authors, women with uterus didelphys need infertility treatment more frequently than those with other uterine abnormalities (Zhang et al., 2010). The infertility in women with hypogonadotropic hypogonadism is associated with inadequate secretion of hypothalamic gonadotropin releasing hormone (GnRH).

This situation causes decreasing of plasma levels of FSH and LH. These hormones should be replaced. Ovulation induction is required for successful pregnancy (Hsing-Tse et al., 2012). Gonadotropin treatment can be used as an alternative to pulsatile GnRH or menopausal gonadotropins to ensure pregnancy in infertile patients with hypogonadotropic hypogonadism. We used purified FSH as gonadotropin and achieved a successful pregnancy. The patients with müllerian abnormality who conceived by using human menopausal gonadotropin –human chorionic gonadotropin are reported in the literature (Tanaka et al., 1998). In the literature 88% of the women with müllerian abnormality are stated to have pregnancies resulting in live birth after strassmann operation. Pregnancy periods of these were normal, ended within the term and they had cesarean sections. The rate of taking live infant to home is reported to be 100% (Lolis

et al., 2005). We performed strassmann metroplasty operation in order to prevent possible recurrent pregnancy wastage and preterm labor in case of future pregnancies of the patient. Successful pregnancies can be achieved by using ovulation induction agents in

theuterus didelphys patients with hypogonadotropic hypogonadism. Strassmann metroplasty can be performed in order to prevent preterm recurrent pregnancy wastage and malpresentation.

REFERENCES

- Awwad, J.T., Farra, C., Mitri, F., Abdallah M.A., Jaoudeh, M.A., Ghazeeri, G. 2013. Split daily recombinant human LH dose in hypogonadotropic hypogonadism: A nonrandomized controlled pilot study. *Reprod. Biomed.* 26, 88-92.
- Bhattacharya, S., Mistri, P.K., 2010. Twin pregnancy in a woman with uterus didelphys. *Online J Health Allied Scs.* 9(4): 24.
- Chan Y.Y., Jayaprakasan, K., Tan, A., Thornton, J.G., Coomarasamy, A., Raine-Fenning, N.J., 2011. Reproductive outcomes in women with congenital uterine anomalies: A systematic review. *Ultrasound Obstet. Gynecol.* 38, 371–382.
- Hsing-Tse, Y., Chyi-Long, L., Hong-Yuan, H., Yung-Kuei, S., 2012. Successful pregnancy in a woman with kallmann's syndrome using human menopausal gonadotropin followed by low-dose human chorionic gonadotropin in the mid-to-late follicular phase. *Taiwanese J. Obstet. Gyn.* 2, 300-302.
- Lolis D.E., Pashopoulos, M., Makrydimas, G., Zikopoulos, K., Sotiriadis, A., Paraskevaidis, E., 2005. Reproductive outcome after strassman metroplasty in women with a bicornuate uterus. *J. Reprod. Med.* 50, 297-301.
- Meiling, H., Anthony, O., George, A., 2011. Congenital uterine anomalies and a diverse pregnancy outcomes. *Am. J. Obstet. Gynecol.* 205, 558.
- Raga, F., Bauset, C., Remohi, J., Fernando, Bonilla-Musoles., Carlos, Simon., Antonio, Pellicer., 1997. Reproductive impact of congenital mullerian anomalies. *Hum. Reprod.* 122277-2281.
- Tanaka, T., Fujimoto, S., Matsuzaki, N., Sakuragi, N., Ichinoe, K., 1988. Twin gestation induced with hMG-hCG in a patient with a bicornuate uterus: Report of a successful delivery. *Int. J. Fertil.* 33, 33-35.
- Zhang, Y., Zhao, Y., Qiao, J., 2010. Obstetric outcome of women with uterine anomalies in china. *Chinese Med. J.* 123, 418-422.