



Case Report

J. Exp. Clin. Med., 2018; 35(4): 115-117  
doi: 10.5835/jecm.omu.35.04.005



## Transient ST-segment elevation due to intracranial hemorrhage in a patient presenting with acute anterior myocardial infarction

Murat Akcay <sup>a\*</sup>, Metin Coksevim <sup>b</sup>

<sup>a</sup> Department of Cardiology, Faculty of Medicine, Ondokuz Mayıs University, Samsun, Turkey

<sup>b</sup> Clinic of Cardiology, Giresun Bulancak State Hospital, Giresun, Turkey

### ARTICLE INFO

### ABSTRACT

#### Article History

Received 30 / 12 / 2017  
Accepted 10 / 01 / 2018  
Online Published Date 18 / 11 / 2019

#### \* Correspondence to:

Murat Akcay  
Department of Cardiology,  
Faculty of Medicine  
Ondokuz Mayıs University,  
Samsun, Turkey  
e-mail: drmuratakay@hotmail.com

Neurogenic stunned myocardium (NSM) is defined as sudden onset, reversible or irreversible myocardial injury, often mimicking acute myocardial infarction. It is arised from an imbalance in the autonomic nervous system in various acute brain injury situations, most commonly in the subarachnoid hemorrhage. Different electrocardiographic abnormalities and arrhythmias are very common even in the absence of structural heart disease. It should be carefully distinguished from acute coronary events. We presented a case of temporary ST-segment elevation after intracranial hemorrhage mimicking re-infarction that developed after thrombolytic therapy which reperused acute anterior myocardial infarction.

#### Keywords:

Intracranial hemorrhage  
Neurogenic stunned myocardium  
Transient diffuse ST-segment elevation

© 2018 OMU

### 1. Introduction

The electrocardiographic and cardiac changes are not uncommon after central nervous system injuries such as subarachnoid, intracranial hemorrhage, subdural hematoma and ischemic stroke (Woon et al., 2012; Mierzevska et al., 2015). Neurogenic stunned myocardium (NSM) is defined as sudden onset, reversible or irreversible myocardial injury, often mimicking acute myocardial infarction. It is arised from an imbalance in the autonomic nervous system in various acute brain injury situations, most commonly in the subarachnoid hemorrhage (Mierzevska et al., 2015). This condition may have many different clinical

manifestations as well as different electrocardiographic findings (Katsanos et al., 2013; Mierzevska et al., 2015). It should be carefully distinguished from acute coronary events. We presented a case of temporary ST-segment elevation after intracranial hemorrhage mimicking re-infarction that developed after thrombolytic therapy which reperused acute anterior myocardial infarction.

### 2. Case

A 54-year-old male patient admitted to emergency service on the second hour of chest pain. Electrocardiography (ECG) showed a 3 mm ST-segment elevation in leads V1-V4. The patient given

antithrombotic therapy at appropriate doses with an acute anterior myocardial infarction. Thrombolytic therapy was planned to be given as it is not in percutaneous coronary intervention center. Intravenous 10 IU of two doses of reteplase (r-PA) for 30 min administered to the patient who has no contraindication for treatment. Then, the patient transferred to our center. After thrombolytic therapy, the patient was clinically reperfused and hemodynamically stabilized. ECG taken again and the QS pattern and biphasic T wave were detected in leads V1-V3. Echocardiography revealed hypokinetic septum and anterior wall with 40% ejection fraction. The patient transferred to the coronary angiography laboratory with percutaneous intervention plan. Coronary angiography showed diffuse atherosclerosis in the left anterior descending artery and medical follow-up planned (Fig. 1a/Video-1). Following intensive care, the patient's blurring of consciousness and apneic breathing suddenly developed. Subsequently, the patient suffered hemodynamic instability and intubated. ECG showed widespread ST-segment elevation (Fig. 1b). An acute cerebrovascular event diagnosed by cranial tomography with a 63\*65 mm size intracerebral hematoma on the left frontotemporal region, which resulted in a shift of to the right and a subfalcial herniation (Fig. 1c). Echocardiography revealed no new segmental wall motion abnormality. The ST-segment elevation improved one hour after the acute phase. Cardiac markers didn't increase in follow up. Coronary angiography wasn't considered again. ECG findings

were evaluated as a complication of intracranial haemorrhage. Patient transferred to intensive care unit of neurology department. Antithrombotic therapy stopped. New ECG changes or new echocardiographic wall motion abnormality didn't detect. The patient died on the second day of follow-up due to intracerebral hematoma.

### 3. Discussion

Neurogenic stunned myocardium may be mixed with acute coronary syndromes especially in emergency departments (Mierzewska et al., 2015). NSM is a difficult clinical condition due to diagnostic difficulties and may result in ECG changes, elevation in cardiac biomarkers, LV dysfunction or cardiogenic shock (Mierzewska et al., 2015). Common ECG changes; prolonged QT interval, ST-segment changes, T-wave inversion, new Q waves or U wave (Katsanos et al., 2013; Mierzewska et al., 2015; Murthy et al., 2015). NSM may also cause echocardiographic basal, mid-ventricular segmental wall motion abnormalities. Although NSM is thought to be primarily a consequence of myocardial injury induced by local massive catecholamine release from the nerve endings in myocardium, the precise pathogenetic process is still unclear and further investigations are needed. Coronary vasospasm and hypoperfusion, hypotension and hypoxia, direct cardiotoxic effect of catecholamines are thought to be another mechanisms (Yusuf et al., 2007; Wybraniec et al., 2014; Köklü et al., 2015; Murthy et al., 2015).

Both acute coronary syndromes (ACS) and intracranial hemorrhage (ICH) are vital clinical conditions and require different treatment approaches (Katsanos et al., 2013). Despite the fact that antithrombotic, anticoagulant therapies are mandatory in ACS, these medications are contraindicated in ICH (Yusuf et al., 2007; Woon et al., 2012; Katsanos et al., 2013; Wybraniec et al., 2014; Köklü et al., 2015). Even if the patient is presenting with ACS as in our case, it should be kept in our mind that ECG changes may occur when consciousness and neurological findings develop as a result of ICH. Cardiac abnormalities secondary to intracranial events are usually transient, as in our case. In such a case, diagnosis should be clarified in a short time with cranial imaging methods and focused on the treatment of the intracranial event.

### Conclusion

Different electrocardiographic and cardiac abnormalities are developed after various acute brain injuries and defined as neurogenic stunned myocardium. Acute coronary syndromes and intracranial hemorrhage are vital clinical conditions, require different treatment approaches and should be carefully distinguished.

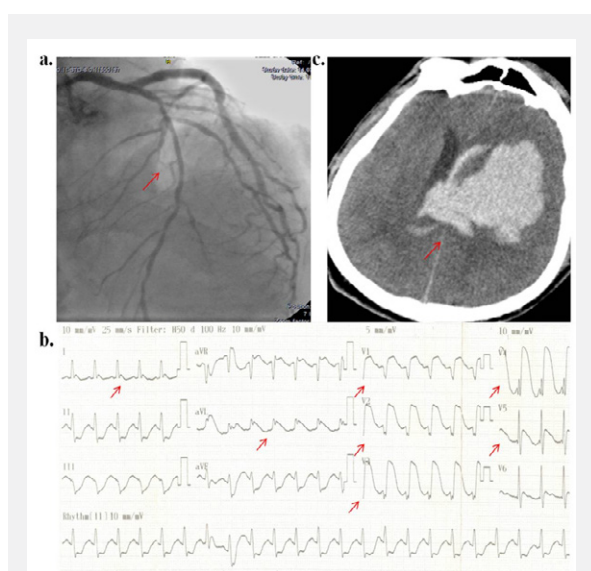


Fig. 1a. Electrocardiographic imaging of diffuse ST-segment elevation after intracranial bleeding. 1b. Angiographic imaging of left anterior descending coronary artery with diffuse 1c. Computed tomographic imaging of intracranial bleeding

**REFERENCES**

- Katsanos, A.H., Korantzopoulos, P., Tsivgoulis, G., Kyritsis, A.P., Kosmidou, M., Giannopoulos, S., 2013. Electrocardiographic abnormalities and cardiac arrhythmias in structural brain lesions. *Int. J. Cardiol.* 167, 328-334.
- Köklü, E., Yüksel, İ.Ö., Bayar, N., Küçükseymen, S., Arslan, Ş., 2015. Subarachnoid hemorrhage that electrocardiographically mimics acute coronary syndrome: A case report. *Türk Kardiyol. Dern. Ars.* 43, 730-733.
- Mierzevska-Schmidt, M., Gawecka, A., 2015. Neurogenic stunned myocardium - Do we consider this diagnosis in patients with acute central nervous system injury and acute heart failure? *Anaesthesiol. Intensive Ther.* 47, 175-180.
- Murthy, S.B., Shah, S., Rao, C.P., Bershady, E.M., Suarez, J.I., 2015. Neurogenic stunned myocardium following acute subarachnoid hemorrhage: Pathophysiology and practical considerations. *J. Intensive Care Med.* 30, 318-325.
- Woon, J. H., Jin, H. K., Woo, S. J., Mi, Y. J., Sang, H. L., Jeong, Y. S., 2012. Subarachnoid hemorrhage misdiagnosed as an acute ST-elevation myocardial infarction. *Korean Circ. J.* 42, 216-219.
- Wybraniec, M.T., Mizia-Stec, K., L., 2014. Neurocardiogenic injury in subarachnoid hemorrhage: A wide spectrum of catecholamin-mediated brain-heart interactions. *Cardiol. J.* 21, 220-228.
- Yusuf, S.W., Bhalla, K.S., Champion, J.C., 2007. Intracranial bleed mimicking acute myocardial infarction. *Intern. Med. J.* 37, 339-340.

**Video Legends**

**Video 1:** Coronary angiographic imaging of vessels