

Neutropenic Toxic Epidermal Necrolysis Due to Sulphonamide Use

Handan Bilen¹, Haticetül Kübra Sarı²

¹ Department of Dermatology, Faculty of Medicine, Ataturk University, Erzurum, Turkey.

² Department of Dermatology, Binali Yıldırım University, Mengücek Gazi Research and Training Hospital, Erzincan, Turkey

Abstract

Toxic epidermal necrolysis (TEN), which has high mortality and morbidity rates, often develops after medication. Clinically, at least 30% of the mucous membranes and skin are involved. Neutropenia is very rare in TEN cases and is directly related to mortality. We wanted to share a case diagnosed with TEN who developed neutropenia during follow-up and was discharged with full recovery with early diagnosis and effective treatment.

Key words: Cotrimoxazole, Toxic epidermal necrolysis, Neutropenia

Özet

Yüksek mortalite ve morbidite oranlarına sahip toksik epidermal nekroliz (TEN) genellikle ilaç tedavisinden sonra gelişir. Klinik olarak, mukoza ve cildin en az% 30'u tutulur. Nötropeni TEN olgularında çok nadir görülür ve doğrudan mortalite ile ilişkilidir. Takip sırasında nötropeni gelişen ve erken tanı ve etkili tedavi ile tam iyileşme ile taburcu edilen TEN tanılı bir vakayı paylaşmak istedik.

Anahtar Sözcükler: Nötropeni, Kotrimaksazol, Toksik epidermal nekroliz

Introduction

Trimethoprim-sulfamethoxazole (TMP / SMX) is an antibiotic that acts by inhibiting the enzymes involved in the synthesis of tetrahydrofolic acid in bacteria. Although both molecules are bacteriostatic, when used together they block the enzymes and show bactericidal action¹. Toxic epidermal necrolysis (TEN) is a condition with high mortality and morbidity, often associated with skin and mucosal involvement, against drugs. It is most commonly seen after drug use and sulfonamides are included in this group. Neutropenia is a considerably rare laboratory finding in patients with TEN and is directly related to mortality².

Case

A 36-year-old female patient was admitted to the emergency department with complaints of fever, weakness, general malaise, rashes on the torso, arms and legs and a painful lesion in the mouth. Physical examination revealed maculopapular

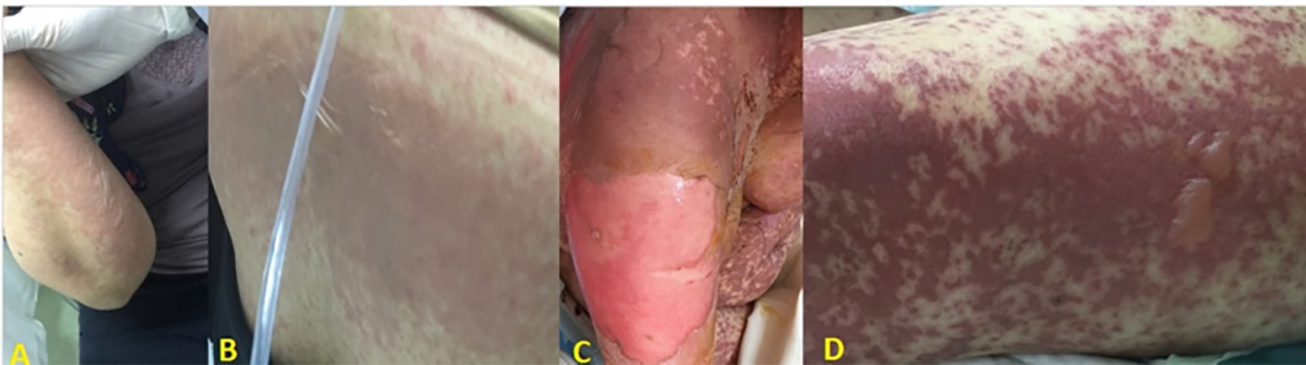
lesions and sporadic vesiculobullous lesions in the upper extremity, frictional bullous lesions (30-40%) (**Figure A-B**) with maculopapular lesions in the dorsum, several bullous and erode lesions in the oral mucosa, and redness in both eyes, mostly in the right eye. In her history, sulfonamide (trimethoprim / sulfamethoxazole) was administered prophylactically 3 days before, after c-section. The patient was hospitalized with a pre-diagnosis of TEN. TMP/SMX treatment was discontinued. Methylprednisolone treatment at a dose of 1 mg/kg and a fluid-electrolyte replacement was started. Urine, blood, and skin cultures were taken. HIV tests were requested. No pathology was detected in routine laboratory tests. In the first week of the treatment, widespread maculopapular and sporadic vesiculobullous lesions, increase of erode bullous lesions especially on the right upper extremity and dorsum, targetoid and sporadic bullous lesions on the lower extremities (80%) (**Figure C-D**), advancement in the oral lesions and a regression in the neutrophil count to 1000 10³/ mm³ were observed. Bullous lesions of the patient were carefully drained, only necrotic lesions were debrided, and the dressing was performed with silver sulfadiazine-free antiseptic agents daily. On the 20th day of treatment, lesions

Corresponding Author: Haticetül Kübra Sarı **e-mail:** drhksari@gmail.com

Received: 04.11.2019 • **Accepted:** 10.11.2019

Cite this article as: Bilen H, Sari HK. Neutropenic toxic epidermal necrolysis due to sulphonamide use. Eurasian J Tox. 2019;1(3): 117-120.

©Copyright 2018 by Emergency Physicians Association of Turkey - Available online at <https://dergipark.org.tr/ejtox>



regressed and the neutrophil count increased. After 30 days of corticosteroid and supportive therapy, the lesions healed completely, leaving postinflammatory hyperpigmentation, nail onychomadesis and alopecia in the hair.

Discussion

Toxic epidermal necrolysis (TEN) is a condition with high mortality and morbidity, often associated with skin and mucosal involvement, against drugs. It is clinically characterized by epidermal dissociation in at least 30% of the body involving at least 2 mucosal areas, diffuse purpura, and non-typical target-like lesions³.

Patients with viral diseases (HIV, hepatitis, herpes, etc.), immunosuppressed patients, patients with a previous diagnosis of TEN of themselves or their families are at risk for this condition⁴. After recent studies, the high rates of HLA-A29, HLA-B12, and HLA-DR7 positivity in TEN cases have shown that it is possible to create risk groups in terms of genetic susceptibility.

The most important risk factor for TEN is drugs with 80-95%. Although the risk of TEN has been reported for more than 200 drugs, the most common drugs with TEN risk are allopurinol, carbamazepine, lamotrigine, phenobarbital, phenytoin, sertraline, and sulfonamide group antibiotics (especially trimethoprim/sulfamethoxazole). 5% of the cases are idiopathic⁵. The disease shows up most commonly between 1. and 3. weeks after the drug intake, but it can be observed to come up until 60 days⁶.

The pathogenesis of the disease is unknown, but it is thought to be a cytotoxic immune reaction to an antigen on the surface of keratinocytes⁷.

At least 50% of patients have prodromal symptoms (fever, weakness, headache, rhinitis, sore throat, itching of the eyes, myalgia, etc.) that may be mistaken for the signs of upper respiratory tract infection. In addition to these complaints, mucosal lesions are symptoms of the disease. Erythema in the mucous membranes gradually develops into painful hemorrhagic bullae. Crusts show up as grayish pseudomembrane on the lips and then appear as hemorrhagic⁸.

Photophobia, pain, lacrimation, chemosis, and redness may occur due to eye involvement. Corneal ulceration, anterior uveitis, and purulent conjunctivitis may develop in patients with more severe involvement. Finally, these lesions may cause blindness⁹. Genital mucosal involvement appears as painful erosion on the glans penis, vulva, and vagina, burning during urination and urinary retention. Acute tubular necrosis, hematuria, and microalbuminuria may occur in the acute phase¹⁰. Anemia, mild elevation of hepatic enzymes and amylase elevation may be observed and not have a significant effect on prognosis. Neutropenia is a very rare laboratory finding and is directly related to mortality. It is so rare that it was not included in 'Severity of Illness Score for TEN' (SCORTEN), which is a prognostic marker for TEN². Although neutropenia, which is very rare and mortal, developed in our case, it was cured fully after treatment.

A multidisciplinary approach is important in the treatment of TEN. Drugs used until 2 months ago should be questioned and all suspicious drugs should be discontinued. Patients should be admitted to intensive care or burn units. The room temperature should be kept between 28-32 ° C, especially in those with large surface area involvement. Intubation may be considered in patients with severe airway involvement, airway obstruction, acute respiratory distress syndrome, and in patients in the need for sedation due to excessive pain. TEN patients should be considered as burn patients and adequate fluid replacement should be given. Pain treatment is the most important treatment for these patients and morphine derivatives are recommended. Prophylactic antibiotics are not recommended, but if proliferation occurs in skin, blood and urine cultures, the causative agent should be initiated¹¹.

The use of intravenous immunoglobulin did not improve survival in patients with TEN. Cyclosporine was found to reduce mortality in adults and progression of epidermal decomposition (dose: 3 mg / kg / day for 10 days and reduced and ended by 30 days)¹². Systemic corticosteroids have been clinically effective in healing and are currently the most commonly used agent for drug side effects. In recent studies, anti-TNF agents are looking promising in TEN diseases¹³.

Conclusion

The companion of neutropenia in the presence of TEN, which has very high rates of mortality and morbidity, makes the prognosis worse. With our case, we wanted to share that even this patient group could be discharged with full recovery with early diagnosis and effective treatment.

References

1. Gleckman R, Blagg N, Joubert DW. Trimethoprim: mechanisms of action, antimicrobial activity, bacterial resistance, pharmacokinetics, adverse reactions, and therapeutic indications. *Pharmacotherapy*, 1981; 1(1): 14-20.
2. Dodiuk-Gad RP, Chung WH, Valeyrie-Allanore L, Shear NH. Stevens-Johnson Syndrome and Toxic Epidermal Necrolysis: An Update. *Am J Clin Dermatol*, 2015; 16(6): 475-493.
3. Roujeau JC. The spectrum of Stevens-Johnson syndrome and toxic epidermal necrolysis: a clinical classification. *J Invest Dermatol*, 1994; 102(6): 285-305.
4. Duncan KO, Tigelaar RE, Bologna JL. Stevens-Johnson syndrome limited to multiple sites of radiation therapy in a patient receiving phenobarbital. *J Am Acad Dermatol*, 1999; 40(3): 493-496.
5. Roujeau JC, Stern RS. Severe adverse cutaneous reactions to drugs. *N Engl J Med*, 1994; 331(19): 1272-1285.
6. Mockenhaupt M. Severe drug-induced skin reactions: clinical pattern, diagnostics and therapy. *J Dtsch Dermatol Ges*, 2009; 7(2): 142-160.
7. Shear NH, Spielberg SP, Grant DM, Tang BK, Kalow W. Differences in metabolism of sulfonamides predisposing to idiosyncratic toxicity. *Ann Intern Med*, 1986; 105(2): 179-184.
8. Revuz J, Penso D, Roujeau JC, Guillaume JC, Payne CR, Wechsler J, et al. Toxic epidermal necrolysis. Clinical findings and prognosis factors in 87 patients. *Arch Dermatol*, 1987; 123(9): 1160-1165.
9. Gueudry J. Risk factors for the development of ocular complications of Stevens-Johnson syndrome and toxic epidermal necrolysis. *Arch Dermatol*, 2009; 145(2): 157-162.
10. Meneux, E. Vulvovaginal involvement in toxic epidermal necrolysis: a retrospective study of 40 cases. *Obstet Gynecol*, 1998; 91(2): 283-287.
11. Fernando SL. The management of toxic epidermal necrolysis. *Australas J Dermatol*, 2012; 53(3): 165-171.
12. Kirchhof MG, Miliszewski MA, Sikora S, Papp A, Dutz JP. Retrospective review of Stevens-Johnson syndrome/toxic epidermal necrolysis treatment comparing intravenous immunoglobulin with cyclosporine. *J Am Acad Dermatol*, 2014; 71(5): 941-947.
13. Paradisi A, Abeni D, Bergamo F, Ricci F, Didona D, Didona B. Etanercept therapy for toxic epidermal necrolysis. *J Am Acad Dermatol*, 2014; 71(2): 278-283.

