

Ventricular tachycardia ablation in patients with structural heart disease: single centre experience

Abdulkadir USLU¹ , Ayhan KUP¹ , Serdar DEMIR¹ , Kamil GULSEN¹ , Fethullah KAYAN³ , Alper KEPEZ² , Taylan AKGUN¹ 

¹ Cardiology Clinic, Kartal Kosuyolu Higher Speciality Heart and Vascular Diseases Training and Research Hospital, Istanbul Turkey.

² Department of Cardiology, School of Medicine, Marmara University Training and Research Hospital, Istanbul, Turkey.

³ Cardiology Clinic, Mardin State Hospital, Mardin, Turkey

Corresponding Author: Abdulkadir USLU

E-mail: dr.akadiruslu@gmail.com

Submitted: 28.09.2019

Accepted: 25.11.2019

ABSTRACT

Objective: The aim of this study is to report our institutional experience with ventricular tachycardia (VT) ablation in patients with structural heart disease.

Patients and Methods: A total of 36 consecutive patients (31 male, age: 62.8 ± 13.2 years) who had undergone VT ablation in our institution between 01.01.2017 and 01.05.2019 were included in the analysis.

Results: A total of 27 patients with the diagnosis of ischemic cardiomyopathy and 9 patients with the diagnosis of nonischemic cardiomyopathy had undergone VT ablation. VT ablation was successful in 32 (88.9%) patients. There were no major procedural complications; however, one patient with ischemic cardiomyopathy died 48 hours after the procedure because of post-ablation cardiogenic shock. Another patient with unsuccessful VT ablation died during hospitalization due to electrical storm. Endocardial ablation was performed in 23 (63.9%) patients and epicardial or combined endocardial and epicardial ablation was performed in 13 (36.1%) patients. Substrate ablation was the dominant strategy in 29 (80.6%) patients whereas activation mapping and isthmus ablation was performed in 7 (19.4%) patients.

Conclusion: Our experience confirms the effectiveness and safety of VT ablation in patients with structural heart disease who are resistant to medical therapy and/or who receive recurrent implantable cardioverter-defibrillator shocks.

Keywords: Ventricular tachycardia, Radiofrequency ablation, Cardiomyopathies

INTRODUCTION

Ventricular tachycardia (VT) is the leading cause of mortality and morbidity in patients with structural heart disease. VT is often associated with sudden cardiac death and implantable cardioverter-defibrillator (ICD) implantation is frequently performed on these patients for prevention of arrhythmic death in accordance with current guidelines [1]. However, recurrent VT is associated with disabling recurrent shocks and may lead to hemodynamic instability.

Ventricular tachycardia ablation has emerged as an effective procedure for patients with structural heart disease and VT. The use of three-dimensional electroanatomical systems has enabled substrate mapping and ablation in sinus rhythm which has rendered VT ablation possible even in patients with hemodynamically intolerable VT. Increased knowledge about the mechanisms of scar related VT and increased experience with VT ablation have widened the applicability of VT ablation especially in patients who are at risk for VT recurrence.

In the present paper we reported our institutional experience with VT ablation in patients with structural heart disease.

MATERIALS and METHODS

Patients

A total of 36 consecutive patients (31 male, age: 62.8 ± 13.2 years) with structural heart disease who had undergone VT ablation between 01.01.2017 and 01.05.2019 at the Kartal Kosuyolu Higher Speciality Heart and Vascular Diseases Training and Research Hospital, in Istanbul were included in the analysis. Data of all patients were obtained from patient files and retrospectively evaluated. VT ablation was performed due to patients' resistance to medical therapy and/or recurrent implantable cardioverter-defibrillator shocks. Active ischemia was ruled out before the ablation procedure in all patients with ischemic cardiomyopathy. Informed consent was obtained from

How to cite this article: Uslu A, Kup A, Demir S, Gulsen K, Kayan F, Kepez A, Akgun T. Ventricular tachycardia ablation in patients with structural heart disease: single centre experience. *Marmara Med J* 2020; 33: 23-26 doi: 10.5472/marumj.681982

all the patients before the procedure. Kartal Kosuyolu Higher Specialty Heart and Vascular Diseases Training and Research Hospital Ethics Committee approved the study protocol (approval number 5-206).

VT Ablation

Endocardial mapping was performed to all patients and epicardial mapping was performed when endocardial mapping failed to identify desired ablation sites. Substrate mapping was performed using Ensite Precision 3D mapping system (Abbott, St Paul, Minnesota, USA). Substrate mapping and ablation was the preferred strategy for the majority of patients. Activation mapping during tachycardia was performed if the tachycardia was hemodynamically tolerated. Normal tissue was defined as tissue with bipolar voltage > 1.5 mV, dense scar was defined as bipolar voltage < 0.5 mV and scar borderzone was defined as a bipolar voltage 0.5-1.5 mV on voltage mapping. Late systolic potentials and local abnormal ventricular activities (LAVA) during sinus rhythm and mid diastolic potentials during VT were tagged as the potential ablation sites (Figures 1 and 2). Entrainment maneuvers were performed to identify isthmus if VT was hemodynamically tolerated. Pacemapping was used to identify the exit site of clinical VT. Irrigated tip catheters were used during ablation. VT stimulation was performed with one to three extrastimuli at two sites in the right ventricle at the end of the procedure to assess the effectiveness of ablation. Procedural success was assessed by non-inducibility of clinical VT during ventricular stimulation and abolishment of all late systolic potentials and LAVA's.

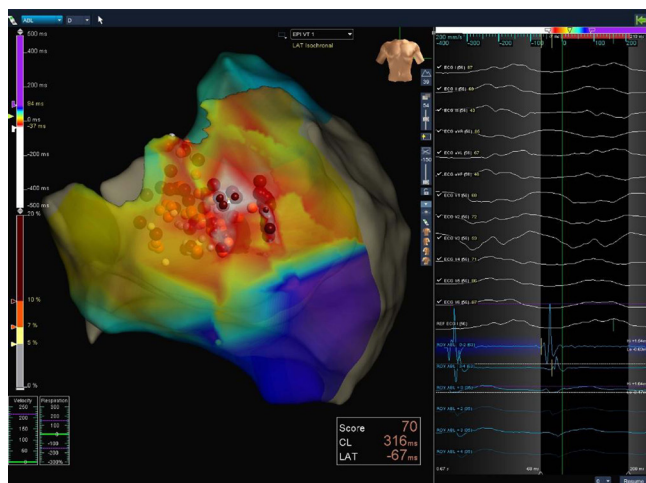


Figure 1: Mid-diastolic potentials during ventricular tachycardia (VT) recorded from endocardial surface. Sites with mid-diastolic potential during VT were assumed to be within critical isthmus and targeted for ablation

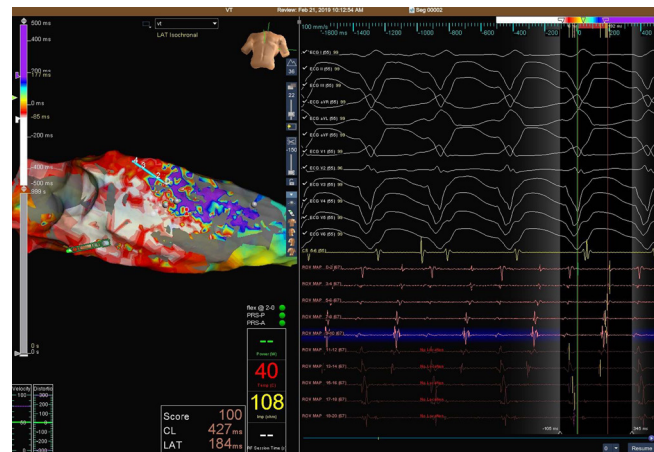


Figure 2: Mid-diastolic potentials during ventricular tachycardia (VT) recorded from epicardial space. Sites with mid-diastolic potential during VT were assumed to be within critical isthmus and targeted for ablation

Statistical Analysis

All statistical tests were performed with a commercially available statistical analysis program (SPSS 16.0 for windows, SPSS Inc., Chicago, Illinois, United States). Distribution of the data was tested by using one-sample Kolmogorov-Smirnov test. Values displaying normal distribution were expressed as the mean \pm SD and values not displaying normal distribution were expressed as median with interquartile range. Categorical variables were expressed in frequencies and percentages. Significance of difference between groups regarding numeric variables with normal distribution was tested with independent samples of Student's *t*-test. Significance of difference between groups regarding categorical variables was tested with Chi-square test. A *p* value less than 0.05 was considered significant.

RESULTS

Demographic and procedural characteristics and outcome of patients are presented in Table-I. Most of the patients were male and majority of patients had ischemic cardiomyopathy (Table-I). There were 9 patients (75%) who were diagnosed as nonischemic cardiomyopathy and among them 1 was diagnosed as arrhythmogenic right ventricular dysplasia (ARVD). None of the patients had Brugada pattern on electrocardiogram (ECG). Most of the patients could not tolerate VT hemodynamically and initial procedural step was substrate mapping and ablation in 80.6% of the patients. Non-inducibility of VT was achieved in 88.9% of patients at the end of procedure. There were no major procedural complications such as systemic embolization, pulmonary edema or death. However, one patient with ischemic cardiomyopathy died after 48 hours following the procedure because of post-ablation cardiogenic shock. Another patient with unsuccessful VT ablation died during hospitalization due to electrical storm.

Table I: Demographic and procedural findings and outcome of patients who had undergone VT ablation

Number	36
Age (years)	62.8 ± 13.2
Male gender	31 (86.1%)
Ischemic cardiomyopathy	27 (25.0%)
Nonischemic cardiomyopathy	9 (75.0%)
Ejection fraction (%)	36.1 ± 13.0
Initial step: Substrate ablation	29 (80.6%)
Initial step: Activation mapping and isthmus ablation	7 (19.4%)
Endocardial ablation	23 (63.9%)
Epicardial (or combined) ablation	13 (36.1%)
Success (VT non-inducible at the end of procedure)	32 (88.9%)

There was no significant difference between patients with ischemic and nonischemic cardiomyopathy regarding rate of substrate ablation or procedural success (Table II). However, the frequency of combined endocardial and epicardial ablation was significantly high in patients with nonischemic cardiomyopathy (Table II). Mean ejection fraction was significantly lower in patients with ischemic cardiomyopathy (Table II).

Table II: Comparison of procedural findings and outcome of patients with ischemic and nonischemic cardiomyopathy

	Ischemic cardiomyopathy (n:27)	Nonischemic cardiomyopathy(n: 9)	P value
Ejection fraction (%)	32.8 ± 10.3	46.1 ± 15.8	0.006
Male gender	25 (92.6%)	6 (66.7%)	0.08
Initial step: Substrate ablation	22 (81.5%)	7 (77.8%)	0.58
Epicardial (or combined) ablation	7 (25.9%)	6 (66.7%)	0.037
Success (VT non-inducible at the end of procedure)	24 (88.9%)	8(88.9)	0.74

DISCUSSION

Present findings that reflect our experiences with VT ablation in structural heart disease suggest the effectiveness and safety of VT ablation procedure in patients with ischemic and nonischemic cardiomyopathy. The success rate was defined as non-inducibility of clinical tachycardia that was 88.9% with no procedural complications aside from one patient who developed hemodynamic instability after the procedure and died during hospitalization.

Catheter ablation of VT in structural heart disease is increasingly being used as adjunctive therapy to implantable cardioverter-defibrillator (ICD) [2]. Multicenter randomized trials have shown significantly decreased ICD interventions in patients who had undergone VT ablation [2-6], and one multicenter study has suggested mortality benefit [7]. Activation mapping and entrainment mapping may be used to identify critical isthmus site that is responsible for initiation and maintenance of reentry in patients with hemodynamically tolerated VT.

However, it is difficult to get activation mapping in most of VT cases due to hemodynamic intolerance. Three dimensional electroanatomical systems have enabled substrate mapping in sinus rhythm and targeting fractionated/late potentials and LAVA which reflect arrhythmogenic myocardium [2]. In the Ablation of Clinical Ventricular Tachycardia Versus Addition of Substrate on the Long Term Success Rate of VT Ablation (VISTA) trial an extensive substrate-based ablation approach was found to be superior to ablation targeting only clinical and stable VTs in patients with ischemic cardiomyopathy presenting with tolerated VT [8]. We performed activation mapping and entrainment mapping in patients with hemodynamically tolerated VT to delineate critical isthmus for catheter ablation. However, most of the patients could not tolerate VT in our patient population that precluded activation mapping and our initial step was substrate mapping in 80.6% of the patients.

There are no randomized studies related with VT ablation in nonsischemic cardiomyopathy patients [9]. Several studies have reported inferior outcome after ablation compared to patients with ischemic cardiomyopathy which is probably due to patchy and diffuse substrate with frequent intramural or subepicardial location [9]. Our ablation strategy for patients with nonischemic cardiomyopathy was similar to our strategy for patients with ischemic cardiomyopathy. However, epicardial or combined endocardial and epicardial ablation was significantly performed in a high percentage of our patients with nonsischemic cardiomyopathy which was in agreement with previous reports. Success rate of ablation was similar between ischemic and nonischemic cardiomyopathy groups, however, it was difficult to reach a firm conclusion because of the small number of patients in nonischemic cardiomyopathy group.

Conclusion

Our experience confirms the effectiveness and safety of VT ablation in patients with structural heart disease who are resistant to medical therapy and/or who receive recurrent implantable cardioverter-defibrillator shocks. There was no difference between patients with ischemic and nonischemic cardiomyopathy regarding ablation strategy and success rates, however, epicardial ablation had to be performed more frequently in patients with nonischemic cardiomyopathy.

Acknowledgement

Authors would like to thank Bahadır Ufuk, Nermin Yuksel and Devrim Gurbuz for their valuable contribution to electrophysiological procedures.

Ethical Committee Approval

This study was approved by the Kartal Kosuyolu Higher Education Heart and Vascular Diseases Training and Research Hospital Ethics Committee (approval number: 5-206). Informed consent was obtained from all patients before the procedure.

Conflict of Interest

The authors declare that they have no no conflict of interest.

REFERENCES

- [1] Ponikowski P, Voors AA, Anker SD, et al. 2016 ESC Guidelines for the diagnosis and treatment of acute and chronic heart failure The Task Force for the diagnosis and treatment of acute and chronic heart failure of the European Society of Cardiology (ESC) Developed with the special contribution of the Heart Failure Association (HFA) of the ESC. *Eur Heart J* 2016; 37: 2129-200. doi: 10.1093/eurheartj/ehw128.
- [2] Dukkipati SR, Koruth JS, Choudry S, Miller MA, Whang W, Reddy VY. Catheter ablation of ventricular tachycardia in structural heart disease: Indications, strategies, and outcomes – part II. *J Am Coll Cardiol* 2017; 70: 2924-41. doi: 10.1016/j.jacc.2017.10.030.
- [3] Sapp JL, Wells GA, Parkash R, et al. Ventricular tachycardia ablation versus escalation of antiarrhythmic drugs. *N Engl J Med* 2016; 375: 111-21. doi: 10.1056/NEJMoa1513614.
- [4] Reddy VY, Reynolds MR, Neuzil P, et al. Prophylactic catheter ablation for the prevention of defibrillator therapy. *N Engl J Med* 2007; 357: 2657-65. doi: 10.1056/NEJMoa065457.
- [5] Kuck KH, Schaumann A, Eckardt L, et al. Catheter ablation of stable ventricular tachycardia before defibrillator implantation in patients with coronary heart disease (VTACH): a multicentre randomised controlled trial. *Lancet* 2010; 375: 31-40. doi: 10.1016/S0140-6736(09)61755-4.
- [6] Kuck KH, Tilz RR, Deneke T, et al. Impact of substrate modification by catheter ablation on implantable cardioverter-defibrillator interventions in patients with unstable ventricular arrhythmias and coronary artery disease: results from the multicenter randomized controlled SMS (Substrate Modification Study). *Circ Arrhythm Electrophysiol* 2017; 10: e004422. doi: 10.1161/CIRCEP.116.004422
- [7] Tung R, Vaseghi M, Frankel DS, et al. Freedom from recurrent ventricular tachycardia after catheter ablation is associated with improved survival in patients with structural heart disease: An International VT Ablation Center Collaborative Group study. *Heart Rhythm* 2015; 12: 1997-2007. doi: 10.1016/j.hrthm.2015.05.036
- [8] Di Biase L, Burkhardt JD, Lakkireddy D, et al. Ablation of stable VTs versus substrate ablation in ischemic cardiomyopathy: The VISTA Randomized Multicenter Trial. *J Am Coll Cardiol* 2015; 66: 2872-82. doi: 10.1016/j.jacc.2015.10.026.
- [9] Okubo K, Gigli L, Della Bella P. Catheter ablation of ventricular tachycardia in nonischemic cardiomyopathy. *J Arrhythm* 2018; 34: 347-55. doi: 10.1002/joa3.12099.