

The Effects of Propylthiouracil on Small Intestine of Mice: A Light and Electron Microscobical Study

Ömür Karabulut Bulan

Istanbul University, Faculty of Science, Department of Biology, İstanbul, Turkey.

(E-mail: omurbulan@yahoo.com)

Abstract

In this study, the effect of propylthiouracil on epithelial cells of the small intestine is examined by histological and cytological methods. As a result of histologic analyses an increase in PAS positive reaction was observed in the intestinal epithelium of the experimental group given PTU for 1 month. As a result of cytologic examination, administration of PTU for 1 month to rats induced marked ultrastructural changes in the small intestinal epithelium. As a result, we can conclude that PTU causes significant structural changes and stimulates its synthesis and secretion functions in the small intestinal epithelium

Key words: Propylthiouracil, thyroid hormones, small intestine.

Introduction

Propylthiouracil (PTU) is a popularly used antithyroid drug for the treatment of hyperthyroidism since 1946 (Ökten et al. 1996; Nakamura et al. 2007). It shows effect by inhibiting the thyroid hormone synthesis and blocking the transformation of thyroxine (T_4) to triiodothyronine (T_3) (Ökten et al. 1996).

The gut plays a major role as a reservoir for the thyroid hormones, especially for T_3 , and it may also play a role in the regulation of hormone activity. It has been known that thyroid hormones modulate the development, growth and differentiation of the small intestine like in many eukaryote tissues (Hodin et al. 1992; Hodin et al. 1996) as well as affect the structure and function of the small intestine (Lewin, 1974; Miller et al. 1978). In addition, thyroid hormones affect gastrointestinal structure and function at multiple levels, producing prominent gastrointestinal symptoms in both hyperthyroid and hypothyroid states (Miller et al. 1978).

In this study the aim was to examine the effects of PTU as a goitrogen on the epithelial cells of the small intestine, morphologically.

Materials and Methods

In this study, 3-3.5 months old (24) male Balb/c mice, weighing 30-37 grams were used. Depending on the duration of the administration of PTU, animals were divided into 2 groups. Each group was formed as having a total of 12 animals, 7 from experimental and 5 from control groups. 0,16mg/20gr/day PTU in 0,9% sterile physiological water was injected intraperitoneally for 7 days on experimental animals forming group I, while it was injected for 30 days to experimental animals forming group II. 0,9% sterile physiological water was injected intraperitoneally to control animals of all groups as the same amount and duration as experimental animals. All experimental animals were sacrificed a day after the last injection together with controls.

Histological methods

Tissue pieces taken from the small intestine were fixed by Bouin fixative and embedded in paraffin wax. Periodic Acid Schiff (PAS) and Hematoxylin-Eosin were applied to the sections.

Cytological methods

Tissue pieces of 1mm³ from jejunum were fixed by 2% glutaraldehyde and 1% osmium tetroxide prepared with phosphate buffer and were embedded in Epon 812.

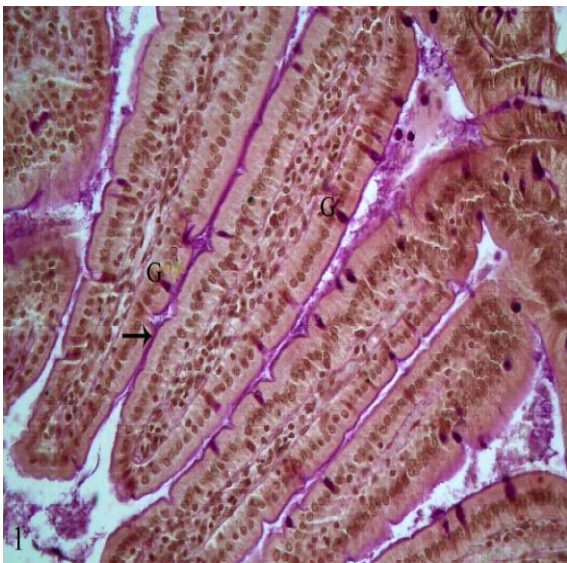

Figure 1. Control group. Goblet cells showing PAS(+) reaction (G), PAS(+) reaction between villi and just above the brush border (→). PAS, X400.

At electron microscopic levels, in the control group, it was observed an ordinary appearance (Fig.3). Chronic administration of PTU for 1 month to rats induced marked ultrastructural changes in the small intestinal epithelium. Goblet cells had many mucus granules that were secreted in the apical end or about to be secreted in the experimental group. Active Golgi apparatus and expanded granular endoplasmic reticulum cisternae was observed in this group. In addition, it was noticed an increase in the number of active Golgi apparatus containing expanded sacculi and

Results

At light microscopic levels, an increase in PAS positive reaction was observed in the intestinal epithelium of the experimental group given PTU for 1 month (Fig.2) in comparison with control group (Fig. 1). The secretion dyed by PAS was increased between the villus. The secretion of many goblet cells was releasing or had been released in this group.

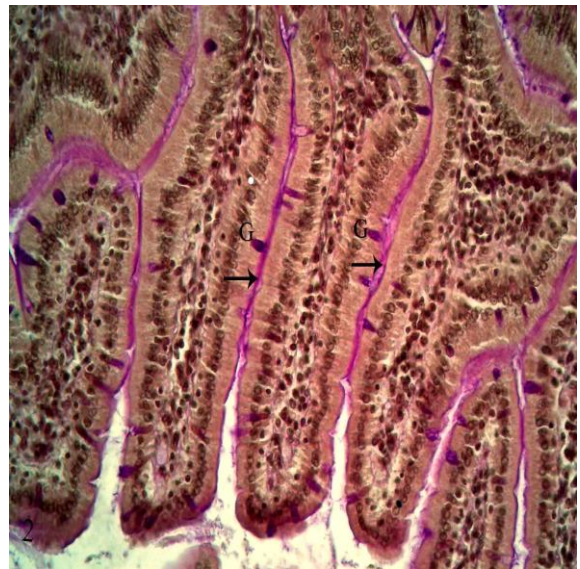


Figure 2. One month PTU treated group. Goblet cells showing generally strong PAS(+) reaction (G), increase in PAS(+) reaction observed in between villi and just above the brush border (→). PAS, X400.

vacuoles, granular endoplasmic reticulum in the periphery of mitochondria, vacuolization in the basal of the cells, electron dense cytoplasm, a lot of mitochondrion and picnotic nuclei in absorptive cells of the experimental group (Fig.4-6).

Discussion

Propylthiouracil (PTU) is an anti-thyroid drug of thionamide group commonly used in the treatment of hyperthyroidism (Ökten et al. 1996; Ben Hamida et al. 2001; Nakamura et al. 2007). Various investigators have shown that

propylthiouracil induced hypothyroidism (Theodossiou et al. 1999; Dhong et al. 2003; Huang et al. 2005; Sener et al. 2006). It shows the effect by inhibiting the thyroid hormone

synthesis (Ökten et al. 1996). Propylthiouracil dramatically reduced thyroid hormones (Gilbert et al. 2003).

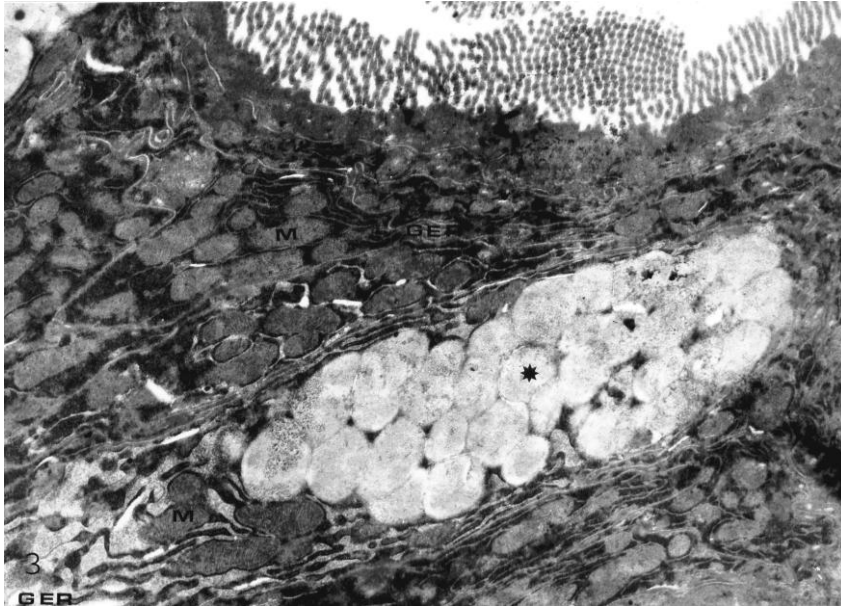


Figure 3. Control group. Granular endoplasmic reticulum (GER), mitochondria (M), mucus granules (*) in goblet cell. Parallel granular endoplasmic reticulum (GER) and mitochondria (M) in absorptive cell. X9700.

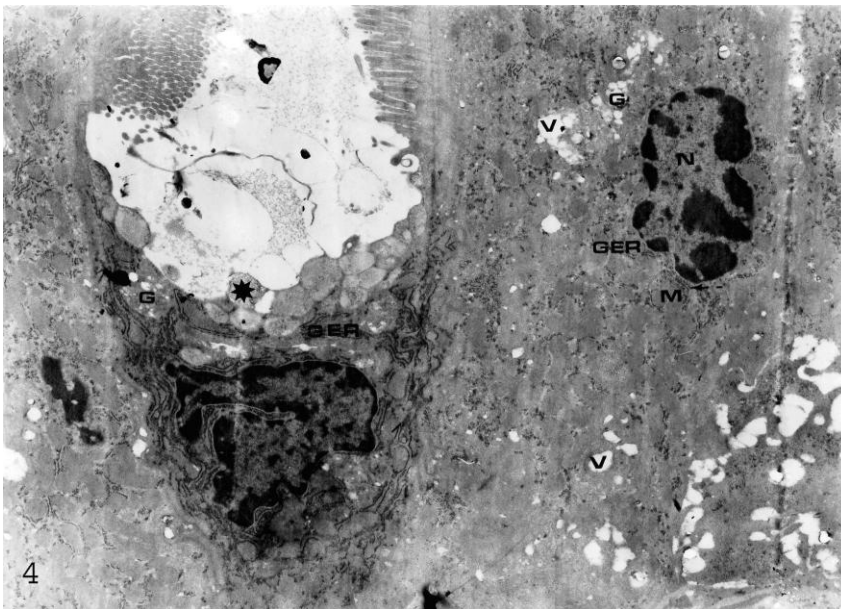


Figure 4. Experimental group. In the goblet cell secreting, mucus granules (*), active Golgi apparatus (G), parallel granular endoplasmic reticulum (GER). In absorptive cell, active Golgi apparatus (G), granular endoplasmic reticulum (GER) in the periphery of mitochondria (M), vacuolization (v), pyknotic nuclei (N). X9700.

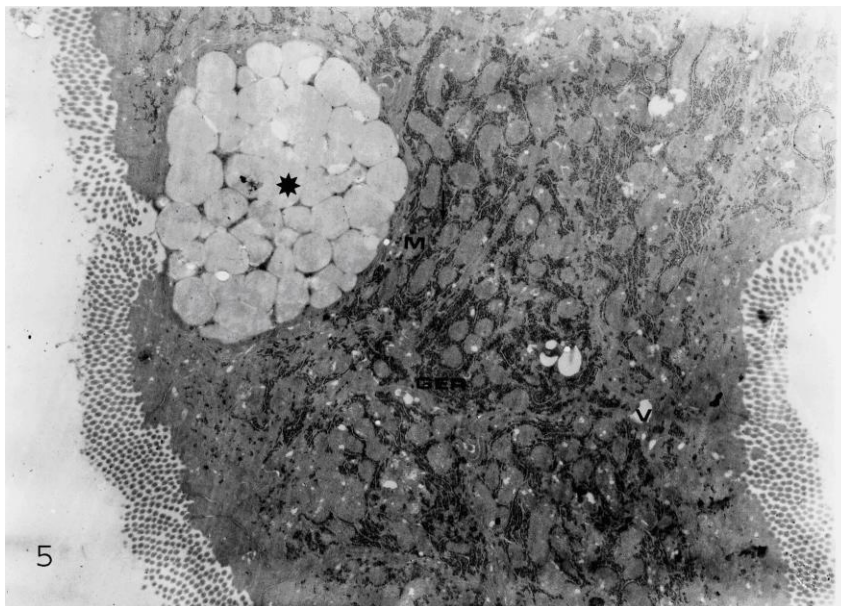


Figure 5. Experimental group. In the goblet cell, mucus granules (*) in the apical end, granular endoplasmic reticulum (GER) in the periphery of mitochondria (M), vacuolization (v). X9700.

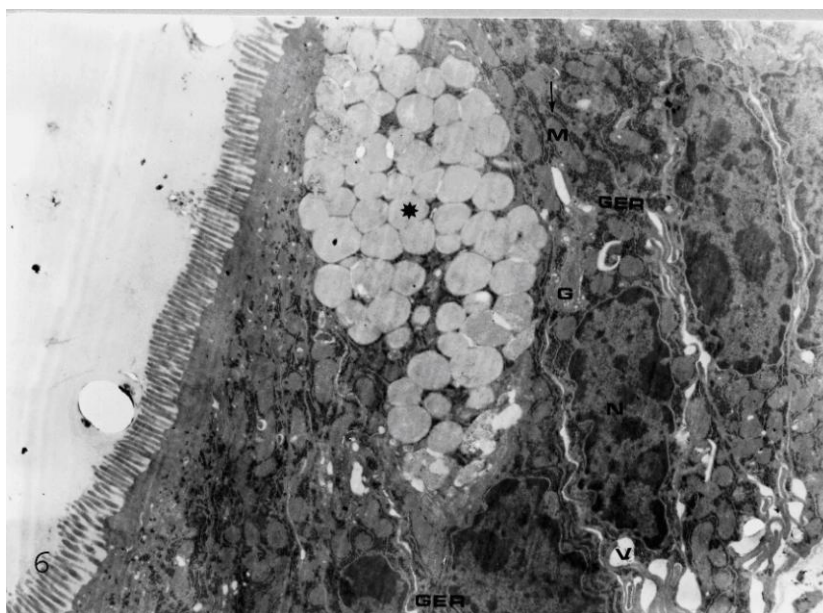


Figure 6. Experimental group. Goblet cell had many mucus granules (*) in the apical end, granular endoplasmic reticulum (GER) in the periphery of mitochondria (M), vacuolization (v), picnotic nuclei (N). X9700.

Thyroid hormones are one of the important regulators of development, growth and differentiation of intestinal epithelium (Tutton 1976; Hodin et al. 1992; Brtko et al. 1994; Hodin et al. 1996). It has been noted that the

gastrointestinal system actively interacts with thyroid hormones, both T_4 and T_3 and are absorbed well by the intestine (Hays 1970; 1988). It has been reported that thyroxine (T_4) and triiodothyronine (T_3) provide normal

maturation in cells of the intestinal mucosa (Middleton and Morrow 1971; Israel et al. 1987) and it has been observed that the small intestine would not develop if the thyroid gland was removed in developing rats (Bronk and Parsons 1965). In addition, we have shown in our previous study that thyroid hormones cause significant structural alterations on the epithelial cells of the small intestine, stimulate absorption and secretion functions (Bulan 1999).

In this study, an increase in PAS positive reaction was observed in the intestinal epithelium of the experimental group given PTU for 1 month. As known, PAS (+) reaction is an indicator of the presence of tissue carbohydrates (Bancroft and Steven 1982). The alterations in structure and amount of PAS (+) materials can change the magnitude of the colour (Dahlquist et al. 1965). The increase in main units in material forming mucous of goblet cells may be the cause of increase in PAS (+) reaction.

In this study, pycnotic nuclei and cytoplasmic vacuolization are findings of cells which are forced and disrupted as a result of an excess metabolic activity (Siurala et al. 1968). The presence of active Golgi apparatus, expanded granular endoplasmic reticulum cisternae and a lot of mitochondrion suggest that these cell were excessively active in metabolic terms and these cells were stimulated by PTU. The increase in ribosomes attached to granular endoplasmic reticulum can be an indicator of the increase in protein synthesis in these cells.

As a result, it has been concluded that PTU caused significant structural changes and stimulates its synthesis and secretion functions in the small intestinal epithelium, in the given dosage and time.

References

- Bancroft J.D and Stevens A. (1982). *Theory and practica of histological techniques*. Churchill Livingstone, Edinburgh,.
- Ben Hamida F., Soussia L., Guermazi F., Rebai T. And Zeghal N. (2001). Propylthiouracil and perchlorate effects on thyroid function in young and lactating mice. *Ann Endocrinol (Paris)*, 62(5):446-53.
- Bronk J.R. and Parsons DS. (1994). Influence of the thyroid gland on the accumulation of sugars in rats intestinal mucosa during adsorbition. *J.Physiol.*, 179:107-115.
- Brtko J., Pascual A. and Aranda A. (1994). 3,5,3/-Triiodothyronine nuclear reseptors and their role in the thyroid hormone action. *Endocr. Reg.*, 28:107-115.
- Bulan Ö.K. (1999). The effects of thyroid hormones on the epithelial cells of the small intestine. *University of Istanbul Journal of Biology*, 61/62:1-23.
- Dahlquist A., Olson I. and Norden A. (1965). The periodate-schift reaction: Specificity, kinetics and reaction products with pure substrates. *J. Histochem. Cytochem.*, 13(6): 423-430.
- Dhong H.J., Kim H.Y. and Ha B.S. (2003). Histologic changes to olfactory epithelium in hypothyroid rats. *Otolaryngol Head Neck Surg.*, 129(1):24-32.
- Gilbert M.E. and Paczkowski C. (2003). Propylthiouracil (PTU)-induced hypothyroidism in the developing rat impairs synaptic transmission and plasticity in the dentate gyrus of the adult hippocampus. *Brain Res Dev Brain Res.* 145(1):19-29.
- Hang X.W. Yang R.I., Zhao Z.Y., Ji C. and Yang R.W. (2005). Mechanism for apoptosis of hippocampus neuron induced by hypothyroidism in perinatal rats. *Zhejiang Da Xue Bao yi Xue Ban.*, 34(4):298-303.
- Hays MT.(1970). Absorption of triiodothyroinine in man. *J. Clin. Endocr.*, 30:675-677.
- Hays M.T. (1988). Thyroid Hormone and the Gut. *Endocrine Research.* 14 (2,3): 203- 224.
- Hodin R.A, Chamberlain S.M. and Upton M.P. (1992). Thyroid hormone differentially regulates rat intestinal brush border enzyme gene expression. *Gastroenterology*, 103(5):1523-1536.
- Hodin R.A, Shei A, Morin M. and Meng S. (1996). Thyroid hormone and the gut: Selective transcriptional activation of a villus-enterocyte marker. *Surgery*, 120(2) 138-143.
- Israel E.J., Pang K.Y., Harmatz P.R. and Walker W.A. (1987). Structural and functional maturation of rat gastrointestinal barrier with thyroxine. *Am. J. Physiol.*, 252 (6,pt1) G762-G767.
- Levin R.J. (1974). A brief overview of the influence of the thyroid on intestinal function. *Dowling HR, Riecken EO.* Intestinal adaptation.

- Proceedings of an International Conference on the Anatomy*, 253-261.
- Middleton W.R.J. and Morrow A.W. (1971). Thyroid hormones and the gut. *Gut*, 12 172-177.
- Miller L.J, Gorman C.A. and Liang V.W. (1978). Gut-thyroid interrelationships. *Gastroenterology*, 75, 901-911.
- Nakamura R., Teshima R., Hachisuka A., Sato Y., Takagi K., Woo G.H., Shibutani M. and Sowada J. (2007). Effects of developmental hypothyroidism induced by maternal administration of methimazole or propylthiouracil on immune system of rats. *Int Immunopharmacol Dec*, 7(13):1630-8.
- Ökten A., Mungan Z. and Onuk M.D.(1996). A case of propylthiouracil induced hepatotoxicity and hemolytic anemia. *Tur J Gastroenterol*, 7:82-85.
- Sener G., Kabasakal I., Atasoy B.M., Erzik C., Velioglu O.A., Cetinel S., Contuk G. Gedik N. And Yeğen B.C. (2006). Propylthiouracil induced hypothyroidism protects ionizing radiation-induced multiple organ damage in rats. *J Endocrinol.*, 189(2):257-69.
- Siurala M., Varis K. and Lamberg B.A. (1968). Intestinal absorption and autoimmunity in endocrine disorders. *Acta Med. Scand.*, 184, 53-64.
- Theodossiou C., Skrepnik N., Robert E.G., Prasad C., Axelrad T.W., Schapira D.V. and Hunt J.D. (1999). Propylthiouracil-induced hypothyroidism reduces xenograft tumor growth in athymic nude mice. *Cancer*, 86(8): 1596-601.
- Tutton P.J.M. (1976). The influence of thyroidectomy and of triiodothyronine administration on epithelial cell proliferation in the jejunum of rat. *Virchows Arch.*, 20 139-142.