

# The Effects of Vitamin B6 on the Liver of Diabetic Rats: A Morphological and Biochemical Study

Şehnaz Bolkent<sup>1\*</sup>, Özlem Saçan<sup>2</sup>, Ayşe Karatuğ<sup>1</sup>, Refiye Yanardağ<sup>2</sup>

<sup>1</sup>Istanbul University, Faculty of Science, Department of Biology, 34134, Vezneciler, Istanbul-Turkey

<sup>2</sup>Istanbul University, Faculty of Engineering, Department of Chemistry, 34320, Avcılar, İstanbul-Turkey

## Abstract

The aim of present study was to investigate the morphological and biochemical effects of vitamin B6 on liver tissue of normal and streptozotocin-diabetic rats. Experimental diabetes was induced by intraperitoneal injection of streptozotocin (STZ) in a single dose of 65 mg/kg. Vitamin B6 was administered by subcutaneous injection at a dose of 20 mg/kg for 15 days. The degenerative changes in the liver tissue, biochemical changes in blood glucose levels and in serum aspartate transaminase (AST), alanine transaminase (ALT) and alkaline phosphatase (ALP) activities were determined. Degenerative changes observed in the diabetic animals by light microscopic investigations. Blood glucose levels, serum AST, ALT and ALP activities increased in the diabetic group. On the other hand, the treatment with vitamin B6 for 15 days reversed these effects. As a result, all of the obtained morphological and biochemical findings led to the conclusion that vitamin B6 has a protective effect against diabetes mellitus.

**Keywords:** Vitamin B6, diabetes mellitus, liver, streptozotocin, rat.

**\*Corresponding author:** Şehnaz Bolkent (E-mail: sbolkent@istanbul.edu.tr)

## Introduction

Vitamin B6 is a collective term for pyridoxal, pyridoxine and pyridoxamine and their phosphorylated forms (Rall and Meydani 1993; Okada et al. 1997). The biologically active form of vitamin B6 is required as a coenzyme in more than 103 enzymatic reactions, all six major categories of enzymes except ligases (Coburn 1994; Okada et al. 1999). Vitamin B6 is involved in a number of metabolic reactions, most of which are involved in the metabolism of amino acids and proteins, lipids, carbohydrates, nucleotide, protein synthesis and cellular proliferation (Rall and Meydani 1993; Borschel et al. 1986).

Pyridoxine deficiency has been shown to lead to fatty liver, low insulin-like activity in the serum and pancreas, accumulation of total lipids, mainly of triglycerides and cholesterol

ester in liver (Selvam and Ravichandran 1991); formation of calcium oxalate stones in the kidney (Ravichandran and Selvam 1991); reduction of glycogen, glucose, and alanine in the liver, carcinogenesis (Reynolds 1986); premature ischaemic heart disease (Vermaak et al. 1987); immunological decline observed in persons infected with the human immunodeficiency virus (HIV) (Rall and Meydani 1993). On the other hand, vitamin B6 is a substance effective in heme synthesis, in galactorea-amenorrhoea due to hyperprolactinemia, in nausea due to pregnancy and radiotherapy, in hydrazine toxication, in retinopathy (Ellis et al. 1991) and in the treatment of gestational diabetes (Spellacy et al. 1977), nephropathy and vascular diseases (Jain 2007).

In this study, it was aimed to investigate the possible involvement of a protective effect of vitamin B6 on the liver tissues of STZ- diabetic rats, morphologically and biochemically.

## Material and Methods

### *Experimental animals*

46 male, eight months old, Swiss albino rats were used in this study. The experiments were reviewed and approved by the Local Institute's Animal Care and Use Committees. They were fed daily with 20 g of milled wheat and 10 g of sheep milk cheese. The rats were divided into four groups designated as follows: Group I: Control animals (intact) (n=10). Group II: Control animals given vitamin B6 (n=10). Group III: STZ-diabetic, untreated animals (n=13). Group IV: STZ-diabetic animals given vitamin B6 (n=13). The rats in diabetics groups were fasted for 18 h and rendered diabetic on day zero by a single subcutaneous injection of 65 mg/kg streptozotocin in a freshly prepared citrate buffer (pH=4.5). The rats in group II and group IV were subcutaneously injected with 20 mg/kg of vitamin B6 in water, daily for 15 days. The rats starved overnight, were dissected under ether anesthesia 15 days after STZ injections. The liver tissue and blood samples were taken for morphological investigations and for biochemical analyses, respectively.

### *Morphological Assays*

Small pieces of liver tissues were taken under ether anaesthesia from animals that had been fasted overnight. The tissue pieces for the light microscopic investigation were fixed with Bouin's fixative and embedded in paraffin after known routine procedures. Sections of 5  $\mu$ m

thickness, after application of Hematoxylin Eosin and Masson's trichrome were examined under Olympus CH 40 microscope.

### *Biochemical Assays*

The body weight of all rats was measured at days 0 and 15. Blood samples were collected through the tail vein of the experimental animals at 0 and 15 days. In all samples, 18 h period of fasting blood glucose levels were determined by the o-toluidine method (Relander and Raiha 1963). Serum aspartate transaminase (AST) and alanine transaminase (ALT) were determined by the Reitman and Frankel method (Reitman and Frankel 1957). Serum alkaline phosphatase activity was estimated by two point method (Walter and Schütt 1974).

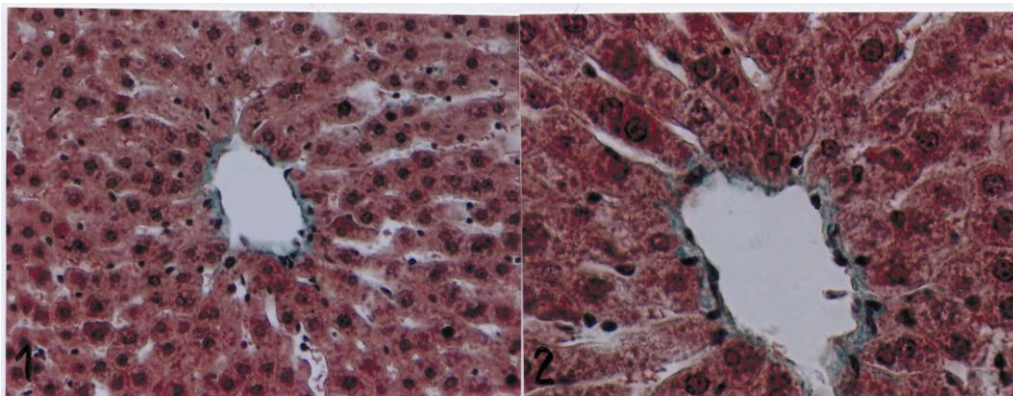
### *Statistical Analysis*

The results were evaluated using an unpaired t-test and ANOVA variance analysis using the NCSS statistical computer package.

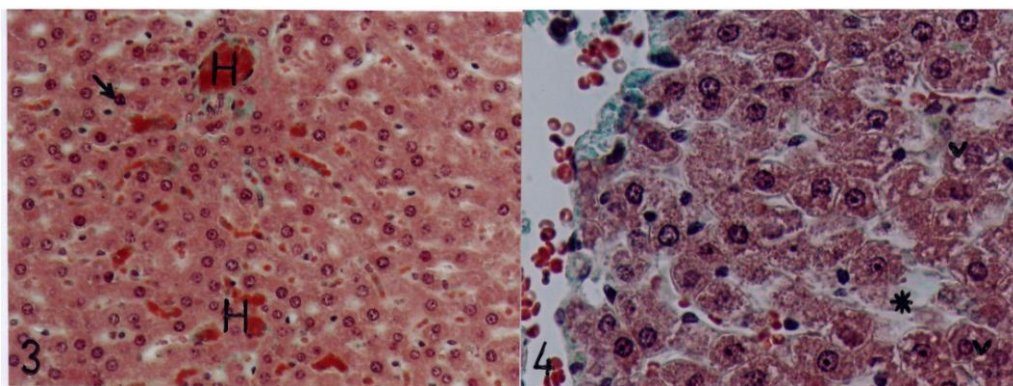
## Results

### *Morphological Results*

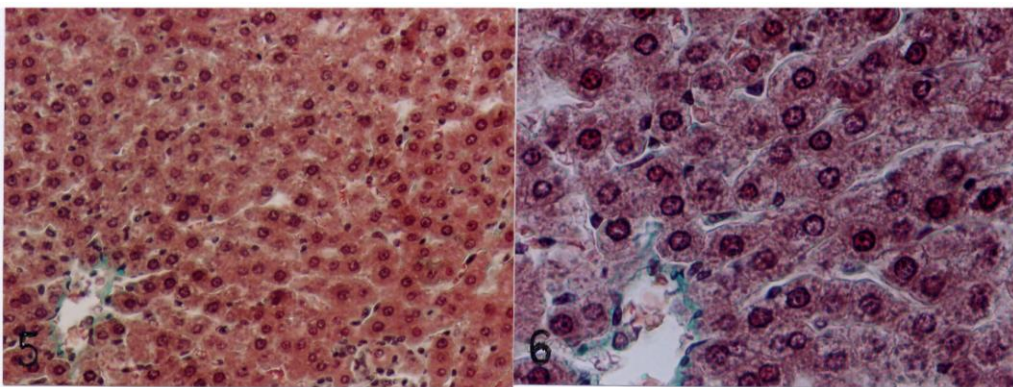
The control (intact) and control animals given B6 showed the same microstructure (Figs. 1,2). Excessive cytoplasmic vacuolization and pycnotic nuclei in hepatocytes were observed in diabetic rats compared to the control groups. In addition, liver sections of this group revealed sinusoidal dilations and hyperemia in sinusoids and central veins (Figs. 3,4). In diabetic group receiving vitamin B6 an ordinary histological appearance was accompanied by minor vacuolization in some cells (Figs. 5,6).



Figures. 1, 2. Liver micrograph of control rat given B6. Masson. X 270, X 540.



Figures. 3, 4. Liver micrograph from diabetic rats. Cytoplasmic vacuolization (V), pyknotic nuclei (→) in hepatocytes, hyperemia (H) in sinusoids and central vein, sinusoidal dilations(\*). Masson. X 270, X540.



Figures. 5, 6. Liver section from vitamin B6 administered diabetic rat. An ordinary histological appearance of hepatocytes. Masson. X270, X540.

### Biochemical Results

According to Table 1, there was no significant difference between the weights of four groups on the 0<sup>th</sup> day ( $P_{ANOVA} = 0.157$ ). In control and control animals given vitamin B6, body weight did not differ remarkably at days 0 and 15 ( $P_{t-test}$

= 0.114 and  $P_{t-test} = 0.505$ ). Body weight, in diabetic group showed a notable decrease at days 15 compared to day 0 ( $P_{t-test} = 0.0001$ ). Administration of the vitamin B6 for 15 days caused a significant increase in body weights in the diabetic group ( $P_{t-test} = 0.0001$ ).

**Table 1.** Mean levels of body weights for all groups\*

Group	Day 0	$P_{t-test}$	Day 15	$P_{t-test}$
Control	330.25 ± 17.24	0.114	333.00 ± 20.67	0.505
Control + Vitamin B6	317.09 ± 13.83		327.50 ± 9.49	
Diabetic	317.56 ± 11.20	0.108	212.97 ± 9.37 <sup>a</sup>	0.0001
Diabetic + Vitamin B6	330.11 ± 12.76		252.53 ± 6.41	
$P_{ANOVA}$	0.157		0.0001	

\* Mean ± SD

n= Number of animals

<sup>a</sup>P < 0.0001 versus control group

The mean blood glucose levels of the four groups are given in Table 2. According to Table 2, there was no significant change in the blood glucose levels between four groups at day 0 ( $P_{ANOVA} = 0.201$ ). 15 days after administration of STZ, the diabetic group had significantly higher blood glucose levels than at day 0.

Vitamin B6 treatment did not produce any significant changes in blood glucose levels of non diabetic rats ( $P_{t-test} = 0.751$ ), but a significant reduction was observed in STZ treated rats after 15 day of vitamin B6 administration ( $P_{t-test} = 0.0001$ ).

**Table 2.** Mean levels of the blood glucose for all groups\*

Group	Day 0	$P_{t-test}$	Day 15	$P_{t-test}$
Control	78.14 ± 3.05	0.058	87.68 ± 5.47	0.751
Control + Vitamin B6	74.30 ± 3.63		86.63 ± 6.61	
Diabetic	76.24 ± 4.63	0.518	220.53 ± 3.52 <sup>a</sup>	0.0001
Diabetic + Vitamin B6	77.63 ± 2.54		159.57 ± 5.86	
$P_{ANOVA}$	0.201		0.0001	

\* Mean ± SD

n= Number of animals

<sup>a</sup>P < 0.0001 versus control group

A significant difference in serum AST, ALT, ALP activities of all groups was observed at the end of the 15 day experiment ( $P_{ANOVA} = 0.0001$ ).

The serum AST, ALT, ALP activities were significantly increased in diabetic group compared to control groups ( $P_{t-test} = 0.0001$ ).

Administration of vitamin B6 was found to reduce AST, ALT and ALP activities in

diabetic rats ( $P_{t\text{-test}} = 0.035$ ,  $P_{t\text{-test}} = 0.0001$ ) (Table 3).

**Table 3.** Serum AST, ALT and ALP activities for all groups.

Group	AST (U/L)*	$P_{t\text{ test}}$	ALT (U/L)*	$P_{t\text{ test}}$	ALP (U/L)*	$P_{t\text{ test}}$
Control	132.43±10.23	0.001	40.76±3.19	0.0001	58.41±2.23	0.0001
Control+Vitamin B6	153.48±3.01		83.22±2.64		46.91±2.37	
Diabetic	185.20±7.46 <sup>a</sup>	0.035	241.37±13.08 <sup>a</sup>	0.0001	243.55±10.60 <sup>a</sup>	0.0001
Diabetic+Vitamin B6	173.91±7.66		91.08±10.50		145.32±13.92	
$P_{ANOVA}$	0.0001		0.0001		0.0001	

\* Mean ± SD

n= Number of animals

<sup>a</sup>P < 0.0001 versus control group

## Discussion

Diabetes mellitus comprises a group of chronic metabolic diseases characterized by hyperglycemia due to abnormal insulin secretion or insulin receptor or post-receptor event affecting metabolism involving carbohydrates, proteins and fats in addition to damaging liver, kidney and  $\beta$ -cells of pancreas (Baynes and Thorpe 1999; Robertson 2004).

The functions of liver and kidney may also be affected by the changes in the levels of insulin. It is known that structural changes occur in the liver as a result of the absence of insulin in diabetes (Koyuturk et al. 2005). Excessive cytoplasmic vacuolization, pyknotic nuclei and a lot of lipid droplets are accepted as an indicator of hepatotoxic effect. The increases in the vacuolization and pyknotic nuclei are important findings indicating that hepatocytes are either dying or heading for necrosis. Hyperemia in sinusoids and central veins show that the liver is having difficulty in its function and it is toxically damaged.

STZ- induced diabetes is characterized by severe loss in body weight. The characteristic loss of body weight associated with STZ-induced diabetes is due to increased muscular wasting in diabetes (Ravi et al. 2004). We have

registered a decrease in body weight in STZ-diabetic rats. Treatment with vitamin B6 improved the weight gain as compared to diabetic rats. This study showed that administration of vitamin B6 improved the body weight in diabetic rats, which could be attributed to its antidiabetic role.

Yarat et al. (1998) reported that 20 mg/kg doses of vitamin B6 increased the blood glucose of streptozotocin-induced diabetic rats. This study, however, showed that vitamin B6 inhibited the increase in blood glucose levels in the diabetic group. Vitamin B6 has also been reported to prevent retinopathy (Ellis et al. 1991) and in gestational diabetes cases to stabilize xanthurenic acid production by restoring tryptophan metabolism and improving oral glucose tolerance (Bennink and Schreurs 1975).

Liver cell destruction shows itself as impairment in the permeability of AST and ALT, which are marker enzymes in the liver. Measurement of enzymatic activities of aminotransferase (AST and ALT) and ALP is of clinical and toxicological importance, as changes in their activities are indicative of tissue damage by toxicants or in disease

conditions (Singh et al. 2001). Vitamin B6 is the coenzyme of transaminases. It has been shown in various studies that there is a decrease in the activities of AST and ALT in case of vitamin B6 deficiency and an increase in the AST values in diabetes, various tissue damage and heart diseases occur (Selvam and Ravichandran 1991; Okada et al. 1993; Nanbara et al. 1990). In our study, it was found that there was an increase in the serum AST and ALT activities of diabetic group. The decrease in those enzyme levels in STZ-diabetic rats given vitamin B6 shows that vitamin B6 prevented liver damage. These findings are also supported by histological findings.

## References

- Baynes J. W. and Thorpe S. R. (1999) Role of oxidative stress in diabetic complications: A new perspective on an old paradigm. *Diabetes*, 48: 1-9.
- Bennink H. J. and Schreurs W. H. (1975) Improvement of oral glucose tolerance in gestational diabetes by pyridoxine. *British Medicine Journal*, 3: 13–15.
- Borschel M. W., Kirksey A. and Hanneman R. E. (1986) Effects of vitamin B6 intake on nutriture and growth of young infants. *American Journal of Clinical Nutrition*, 43: 7 – 15.
- Coburn S. P. (1994) A critical review of minimal vitamin B6 requirements for growth in various species with a proposed method of calculation. *Vitamins and Hormones*, 48: 259 – 300.
- Ellis J. M., Folkers K., Minadeo M., Vanbuskirk R., Xia L. J. and Tamagawa H. (1991) A deficiency of vitamin B6 is a plausible molecular basis of the retinopathy of patients with diabetes mellitus. *Biochemical and Biophysical Research Communications*, 179: 615–619.
- Jain S. K. (2007) Vitamin B6 (pyridoxamine) supplementation and complications of diabetes. *Metabolism Clinical and Experimental*. 56: 168-171.
- Koyuturk M., Tunali S. Bolkent S. and Yanardag R. (2005) Effects of vanadyl sulfate on liver of Streptozotocin-induced diabetic rats. *Biological Trace Element Research*, 104: 2332-2347.
- Nanbara S., Tanaka K., Koide H., Tanaka T. and Hayashi T. (1990) Changes on levels of B6 vitamin and aminotransferase in the liver of diabetic animals. *Diabetes Research and Clinical Practice*, 9: 109–114.
- Okada M., Harima H., Hosoi Y. and Sogo A. (1993) Influences of some low molecular compounds on enzymatic activity and isoelectric point of aspartate aminotransferase from rat liver. *Journal of Nutritional Science and Vitaminology*, 39: 311–321.
- Okada M., Miyamoto E., Nishida T., Tomida T. and Shibuya M. (1997) Effect of vitamin B-6 nutrition and diabetes on vitamin B-6 metabolism. *The Journal of Nutritional Biochemistry*, 8: 44 –48.
- Okada M., Shibuya M., Yamamoto E. and Murakami Y. (1999) Effects of diabetes on vitamin B6 requirement in experimental animals. *Diabetes, Obesity and Metabolism*, 1: 221-225.
- Rall L. C. and Meydani S. N. (1993) Vitamin B<sub>6</sub> and immune competence. *Nutrition, Reviews*, 51: 217 – 225.
- Ravi K., Ramachandran B. and Subramanian S. (2004) Protective effect of Eugenia jambolana seed kernel on tissue antioxidants in streptozotocin-induced diabetic rats. *Biological Pharmaceutical Bulletin*, 27: 1212-1217.
- Ravichandran V. and Selvam R. (1991) Increased plasma lipid peroxidation in vitamin B-6 deficient rats. *Indian Journal of Experimental Biology*, 29: 56–58.
- While the cause of the pathological increases observed in plasma alkaline phosphatase levels is liver or bone diseases, serum alkaline phosphatase levels were also increased in cases of liver cell damage and diabetes mellitus. Whereas, a significant increase in the ALP activity of diabetic rats compared to controls was observed, the finding that this increase tends to decrease by vitamin B6 treatment, showing that the damage formed in the liver decreases by vitamin B6. In this study, as a result of all these morphological and biochemical findings, it is concluded that vitamin B6 exerts a protective effect against hepatotoxicity produced by diabetes.

- Reitman S. and Frankel S. (1957) A colorimetric method for the determination of serum glutamic oxalacetic and glutamic pyruvic transaminases. *American Journal of Clinical Pathology*, 28: 56–63.
- Relander A. and Raiha C. E. (1963) Differences between the enzymatic and toluidine methods of blood glucose determination. *Scandinavian Journal of Clinical and Laboratory Investigation*, 15: 221–224.
- Reynolds R. D. (1986) Vitamin B6 deficiency and carcinogenesis. *Advances in Experimental Medicine and Biology*, 206: 339 – 347.
- Robertson R. P. (2004) Chronic oxidative stress as a central mechanism for glucose toxicity in pancreatic islet beta cells in diabetes. *Journal of Biological Chemistry*, 279: 42351–42354.
- Selvam R. and Ravichandran V. (1991) Lipid peroxidation in liver of vitamin B6 deficient rats. *The Journal of Nutritional Biochemistry*, 2: 245 – 250.
- Singh S. N., Vats P., Suri S., Shyam R., Kumria M. M. L., Ranganathan S. and Sridharan K. (2001) Effect of an antidiabetic extract of *Catharanthus roseus* on enzymic activities in streptozotocin induced diabetic rats. *Journal of Ethnopharmacology*, 76: 269–277.
- Spellacy W. N., Buih W. C. and Birk S. A. (1977) Vitamin B6 treatment of gestational diabetes mellitus: Studies of blood glucose and plasma insulin. *American Journal of Obstetrics and Gynecology*, 127: 599 – 602.
- Vermaak W. J., Barnard H. C., Potgieter G. M. and Theron H. D. (1987) Vitamin B6 and coronary artery disease. Epidemiological observations and case studies. *Atherosclerosis*, 63: 235–238.
- Walter K. and Schütt C. (1974) Acid and alkaline phosphatase in serum (Two-point method), H. U. Bergmeyer (Ed.). *Methods of Enzymatic Analysis*, Vol 2, Verlag Chemie GmbH, Florida, pp. 856–860.
- Yarat A., Yanardağ R., Özçelik F., Özsoy Ö., Baççum A. and Emekli N. (1998) Effect of vitamin B6 on lenses of diabetic rats. *Indian Journal of Experimental Biology*, 36: 1269–1272.