
A case of epidural venous plexus enlargement presenting with radiculopathy and low back pain mimicking lumbar disc herniation

Radikülopati ve bel ağrısı ile ortaya çıkan ve lomber disk herniasyonunu taklit eden epidural venöz pleksus genişlemesi olgusu

Yakup Erden¹ , Nurullah Dag² , Rumeysa Samancı³ 

ÖZ

Bel ağrısı ve radikülopati ile ortaya çıkan epidural venöz pleksus genişlemesi, sinir kökleri sıkışmalarının nadir bir nedenidir. Lomber epidural varisler klinik ve radyolojik olarak lomber disk hernisini taklit edebilir. Bu nedenle, kalıcı semptomlara yol açan tanı sıklıkla gözden kaçırılır veya ertelenir. Biz, tıbbi tedaviye yanıt vermeyen, aralıklı bel ağrısı ve radikülopatili genç bir kadın hastayı sunuyoruz.

Anahtar Kelimeler: Epidural venöz pleksus genişlemesi; lomber disk hernisi; radikülopati; bel ağrısı

ABSTRACT

Epidural venous plexus enlargement, presenting with low back pain and radiculopathy, is a rare cause of nerve roots impingement. Lumbar epidural varices can mimic as a lumbar disc herniation clinically and radiologically. For this reason, the diagnosis is commonly missed or delayed leading to persistent symptoms. We present a young female patient with intermittent low back pain and radiculopathy, unresponsive to medical treatment.

Keywords: Epidural venous plexus enlargement; lumbar disc herniation; radiculopathy; low back pain

Received: 04.02.2020, Accepted: 08.06.2020

¹MD, Abant İzzet Baysal University İzzet Baysal Physical Treatment Training and Research Hospital, Bolu, Turkey

²MD, Department of Radiology, Gazi University Faculty of Medicine, Ankara, Turkey

³MD, Clinic of Physical Medicine and Rehabilitation, Düzce Atatürk Devlet Hastanesi, Düzce, Turkey

Corresponding Author: Yakup Erden. Abant İzzet Baysal University İzzet Baysal Physical Treatment Training and Research Hospital, Bolu, Turkey

E-posta: yakuperden@hotmail.com

This case report was presented as a poster presentation at the 3rd Congress of PMR Course Days (02-05 April 2020).

How to cite: Erden Y, Dag N, Samancı R. A case of epidural venous plexus enlargement presenting with radiculopathy and low back pain mimicking lumbar disc herniation. Ahi Evran Med J. 2020;4(2):53-55.

INTRODUCTION

Lumbar disc herniation (LDH) is initially considered in patients with low back and lower extremity radicular pain. Epidural Venous Plexus Enlargement (EVPE) is a rare condition that cause these complaints and may be seen in magnetic resonance imaging (MRI) taken with a prediagnosis of herniated disc. The diagnosis is often missed, because it is rarely accepted as a primary pathophysiological entity. Here, we aimed to present a young female patient with intermittent low back pain and radiculopathy, who had no additional diseases. An informed consent statement was obtained from patient for this study.

CASE REPORT

A 21-year-old female patient presented with intermittent chronic low back pain radiating down the back of the thigh into the left leg. There were numbness and paresthesia in the same area. The pain was increasing especially with long standing and valsalva maneuver. The pain was not ameliorated with analgesic and myorelaxant agents. Prolonged morning stiffness never happened. On physical examination, range of motion testing of the lumbar spine was normal but mildly painful. Tenderness over the lumbar spinous process segments and paravertebral muscle was present. Straight leg raise test was negative, neurological examination was normal, and the patellar reflex was normoactive. Edema, leg diameter difference and discoloration were not observed in the lower extremities. An MRI was performed with a prediagnosis of lumbar discopathy. The MRI was reported as minimal diffuse bulging at all lumbar levels. Radiologists failed to notice the epidural varices on MRI. Due to the persistence of the symptoms, all aspects of the images were closely examined and the enlarged epidural venous plexus was finally detected on the MRI. EVPE was observed bilaterally, with a larger left. There were enlarged vascular structures within bilateral neural foramens, particularly at the left L4-5 and L5-S1 levels (Figure 1). It was noted that the vascular structures were close to the nerve roots and indentations in some nerves. However, no significant edema and diameter increase was observed in the nerves.

Her EMG and peripheral nerve conduction studies were normal. There was no thrombus and stenosis in the inferior vena cava and iliac veins. She was conservatively managed with physiotherapy including superficial heating, transcutaneous electrical nerve stimulation and exercises that do not cause a marked increase in venous pressure. Her symptoms relieved partially. The intervals of symptoms extended and their severity decreased. An informed consent statement was obtained from patient for this study.

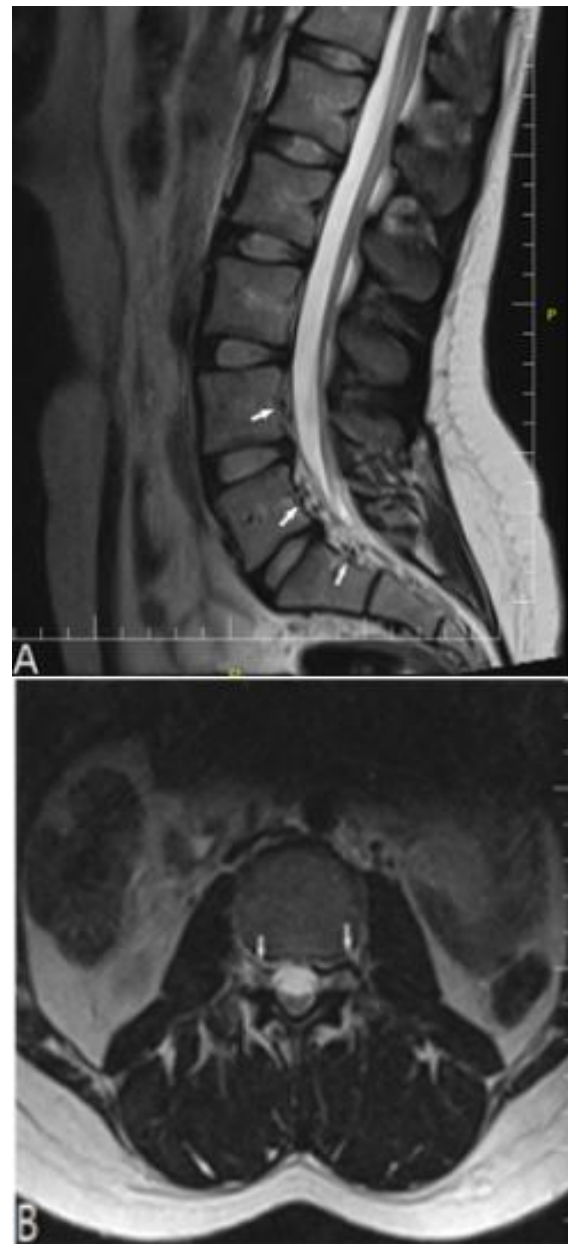


Figure 1. Varices on T2-weighted images sequence are sagittal(A) and axial (B) plane. The white arrows show the lesions.

DISCUSSION

The vertebral venous system is a valveless, large and relatively low-pressure network that communicates with the inferior vena cava, pelvic veins and azygous system. Venous flow is bidirectional. When venous pressure is increased in the inferior vena cava, venous return may be redirected into the epidural veins, eventually forming epidural venous enlargements.¹ The mechanism of radicular pain is exactly unknown, but the pain most likely results from nerve root compression or stimulation by the varix itself. Back pain caused by epidural venous varicosity is common, but the mechanism is not yet known.² EVPE can be congenital or acquired. The common causes of acquired EVPE include compressive lesions in the spinal cord, intracranial hypotension, inferior vena cava or iliac vens thrombosis, and increased intraabdominal pressure (e.g., pregnancy, obesity).³

Lumbar epidural varices can compress nerve root and thecal sac directly, therefore they clinically and radiologically mimic lumbar disc herniation.⁴ Lumbar epidural pressure is related to posture, increased with extension and decreased with flexion. The pressure had a wave pattern during walking.⁵ This mechanism may explain the pain pattern of our patient. Herniated nucleus pulposus, depending on the amount of water it contains, can be seen as hypo- and hyperintensity on MRI sequences. Therefore, diagnosing epidural venous varices is difficult and generally overlooked. Accurate evaluation of MRI is essential to differentiate between nucleus pulposus and epidural varices.

In cases that failed to respond to medical treatment and have major neurological deficits, surgery is recommended. Decompressive laminectomy and aspiration, excision and coagulation of epidural varices have been described surgically.⁶ In a patient whose surgery was contraindicated, a partial improvement in symptoms was detected with physiotherapy without deep heating.⁷

In conclusion, epidural varices should be included in the differential diagnosis of the low back pain. It should also be considered before algological and surgical interventions to prevent vascular injuries.

CONFLICT OF INTEREST

The authors declare no conflict of interest.

REFERENCES

1. Moonis G, Hurst RW, Simon SL, Zager EL. Intradural venous varix: a rare cause of an intradural lumbar spine lesion. *Spine*. 2003;28(20):430-432.
2. Ju JH, Ha HG, Jung CK et al. Patterns of epidural venous varicosity in lumbar stenosis. *Korean J Spine*. 2012;9(3):244-249.
3. Donmez FY. Epidural venous plexus engorgement: what lies beneath? *Case Rep Radiol*. 2015;2015:965106.
4. Bursalı A, Akyoldas G, Guvenal AB, Yaman O. Lumbar epidural varix mimicking disc erniation. *J Korean Neurosurg Soc*. 2016;59(4):410-413.
5. Takahashi K, Kagechika K, Takino T, Matsui T, Miyazaki T, Shima I. Changes in epidural pressure during walking in patients with lumbar spinal stenosis. *Spine*. 1995;20(24):2746-2790.
6. Genevay S, Palazzo E, Hutten D, Fossati P, Meyer O. Lumbar radiculopathy due to epidural varices: two case reports and a review of the literature. *Joint Bone Spine*. 2002;69(2):214-217.
7. Atalay B, Atalay A. Chronic low-back pain due to epidural varices: a case based review of the literature. *Yeditepe Med J*. 2011;5(19):429-432.