

TUBERCULOUS TENOSYNOVITIS PRESENTING ITSELF AS CARPAL TUNNEL SYNDROME AND WRIST GANGLION

KARPAL TÜNEL SENDROMU ve BİLEKTE GANGLİON ŞEKLİNDE GÖZÜKEN TÜBERKÜLOZ TENOSİNOVİTİ: Olgu sunumu

Selma SÖNMEZ ERGÜN*, Resit Burak KAYAN*, Esra BAŞAR GÜRSOY**, Zühal GÜCİN***

ABSTRACT

Tuberculosis caused by *Mycobacterium tuberculosis* is a well known and one of the oldest infectious diseases to affect humans. There is a recent increase of its incidence due to development of resistance to antituberculosis drugs and conditions associated with immunodeficiency such as AIDS and chemotherapy. As a result, unusual presentations of tuberculosis have been encountered more frequently in the last decade.

Although soft tissue tuberculosis is a well recognized form of extrapulmonary tuberculosis, primary tuberculous tenosynovitis is rare.

We report an immunocompetent male patient with a very rare presentation of extrapulmonary tuberculosis, tuberculous tenosynovitis of the wrist, presenting itself as carpal tunnel syndrome and wrist ganglion.

Key words: Tuberculous tenosynovitis, carpal tunnel syndrome, wrist ganglion, treatment.

ÖZET

Mikobakteryum tüberkülozis tarafından oluşturulan tüberküloz insanoğlunu etkileyen, iyi bilinen en eski enfeksiyon hastalıklarından biridir. Antitüberküloz ilaçlara karşı gelişen direnç ve AIDS- kemoterapi gibi nedenlerle oluşan immün yetmezlik tüberküloz insidensinde artışa yol açmıştır. Bu nedenlerle son yıllarda alışılmışın dışında tüberküloz tablolarıyla karşılaşmaktadır. Yumuşak doku tüberkülozu ekstrapulmoner tüberkülozun çok tanınan şekli olmasına rağmen primer tüberküloz tenosinoviti nadir görülür.

Bu çalışmada, ekstrapulmoner tüberkülozun nadir görülen formlarından tüberküloz sinovitin kendisini klinik olarak karpal tunnel sendromu ve bilekte ganglion olarak gösterdiği olgu sunulmaktadır.

Anahtar kelimeler: Tüberküloz tenosinovit, karpal tunnel sendromu, bilek ganglionu, tedavi.

INTRODUCTION

Tuberculosis usually affects lungs, but other organs are involved in up to one third of cases. Primary tuberculous tenosynovitis is a rare condition and selectively targets the flexor tendons of the wrist and radioulnar bursae, the latter having earned the misleading expression ganglion as in our case (1,2,3).

The rarity of this condition leads to delayed diagnosis. The clinical presentation is usually a slow-growing indolent mass along the tendon associated with pain and restriction of movements, sometimes as in our case, with development of carpal tunnel syndrome (4).

An unusual case of extrapulmonary tuberculosis mimicking concomitant carpal tunnel syndrome and wrist ganglion presented in this report.

CASE REPORT

A 67-year-old man was admitted to our hospital complaining of numbness and tingling in the radial three fingers (D3, D4 and D5) and swelling and pain on his left wrist. While the numbness had been present for 6 months, the swelling and pain had been present for 18 months.

Date received/Dergiye geldiği tarih: 06.06.2013 - Dergiye kabul edildiği tarih: 30.09.2013

* Department of Plastic and Reconstructive Surgery, ** Department of Neurology, *** Department of Pathology
Bezmialem Medical School, Bezmialem Vakif University, Istanbul, Turkey
(İletişim kurulacak yazar: selmasonmezergun@yahoo.com)

Tuberculous tenosynovitis

His previous wrist MRI in June 2010 revealed sclerosis and subchondral erosion of the carpal bones and distal part of the radius and ulna. There was synovial thickening and excess synovial fluid in the wrist joint space. There were no abnormalities and sign of compression on the trace of median nerve. These MRI findings are considered as symptoms of rheumatological disease, therefore he was treated with anti-inflammatory drugs in another medical center. But his swelling was localized on the volar side of the wrist region, his pain continued increasingly and numbness of the radial three fingers of the left hand was present as well.

Physical examination revealed a partly mobile mass 3x2.5 cm in size on the ulnovolar aspect of the left wrist. The pain was aggravated with wrist movements and disturbed his sleep at night. There was no local tenderness on the mass and no sign of acute inflammation. Phalen's test and Tinel' sign were positive.

The patient denied any direct trauma on this area. He was normally fit and healthy (ASA 2).

Laboratory examinations (blood cell counts, erythrocyte sedimentation rate, C-reactive protein, rheumatoid factor, anti-HIV and anti-HCV) were unremarkable.

The roentgenograms of the chest, left hand and wrist were normal. Performed electromyography (EMG) testing was compatible with carpal tunnel syndrome.

Clinical primary diagnosis was carpal tunnel syndrome and wrist ganglion. Surgery was planned for the carpal tunnel release and removal of the ganglion under axillary nerve block. Grossly thickened synovium encasing flexor tendons, polished white rice bodies and clear synovial fluid were observed at operation. Debulking tenosynovectomies were performed and rice bodies were removed.

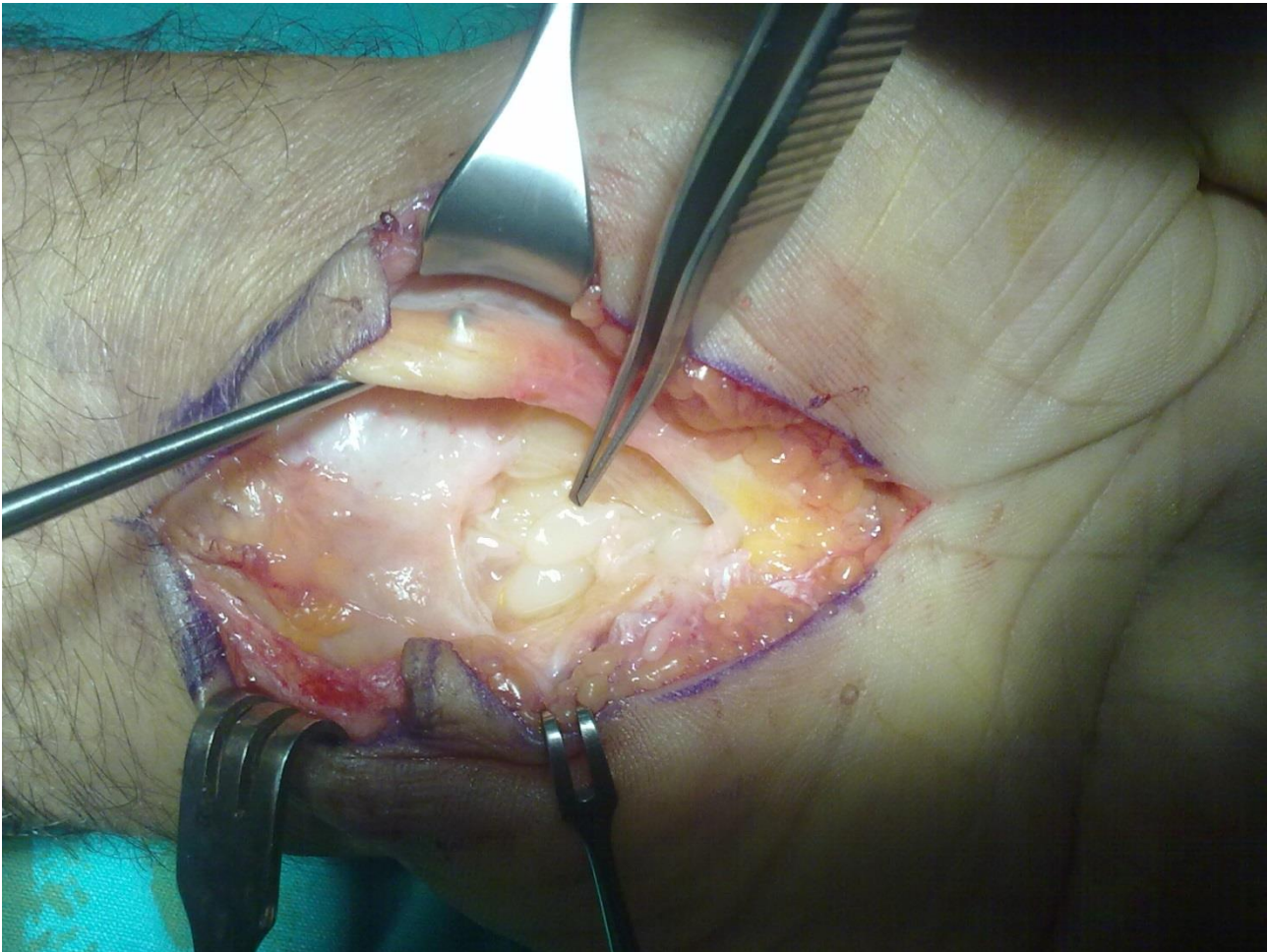


Figure 1: Peroperative appearance of the rice bodies in the wrist region.

Histopathology revealed histiocytic granulomas, fibrinoid degeneration and lymphoplasmocytic infiltration. Acid-fast bacilli were not seen on Ziehl-Neelsen staining of the surgical specimens. Microscopic evaluation of rice bodies showed that they consisted of fibrino-necrotic material. PCR (Polymerase Chain Reaction) for mycobacterium tuberculosis was negative. Finally granulomatous tenosynovitis was diagnosed.

Exhaustive investigations were done for possible causes of granulomatous tenosynovitis in the postoperative period. Chest CT showed no significant findings. Laboratory examinations (cyclic citrullinated peptid antibody, antinuclear antibodies, anti-SS-A, anti-DNA, ACE) were unremarkable except for tuberculin skin test (TST) (30 mm induration) and interferon-inducible protein (IP-10; RayBio) (TB Ag-Nil: 25032 pg/ml,

Tüberküloz tenosinoviti

Mitogen-Nil: 45360 pg/ml (Nil \leq 8000, TB Ag-Nil \geq 1500, TB Ag-Nil \geq Nil/4) and Xpert MTB/RIF assay (Cepheid) positivity on sample taken by nasopharyngeal smear.

He had no pulmonary symptoms such as productive cough. Family history revealed no previous tuberculosis. Treatment with isoniazid (INH) 3000 mg/

day, rifampicin (RMP) 600 mg /day, ethambutol (EMB) 1.5 g/day and pyrazinamid (PZA) 2 g/day were started. The complaints of the patient regressed within 2 months. After two months EMB and PZA were discontinued. INH and RMP were given for 4 months. At 26 months of follow-up the patient was doing well.

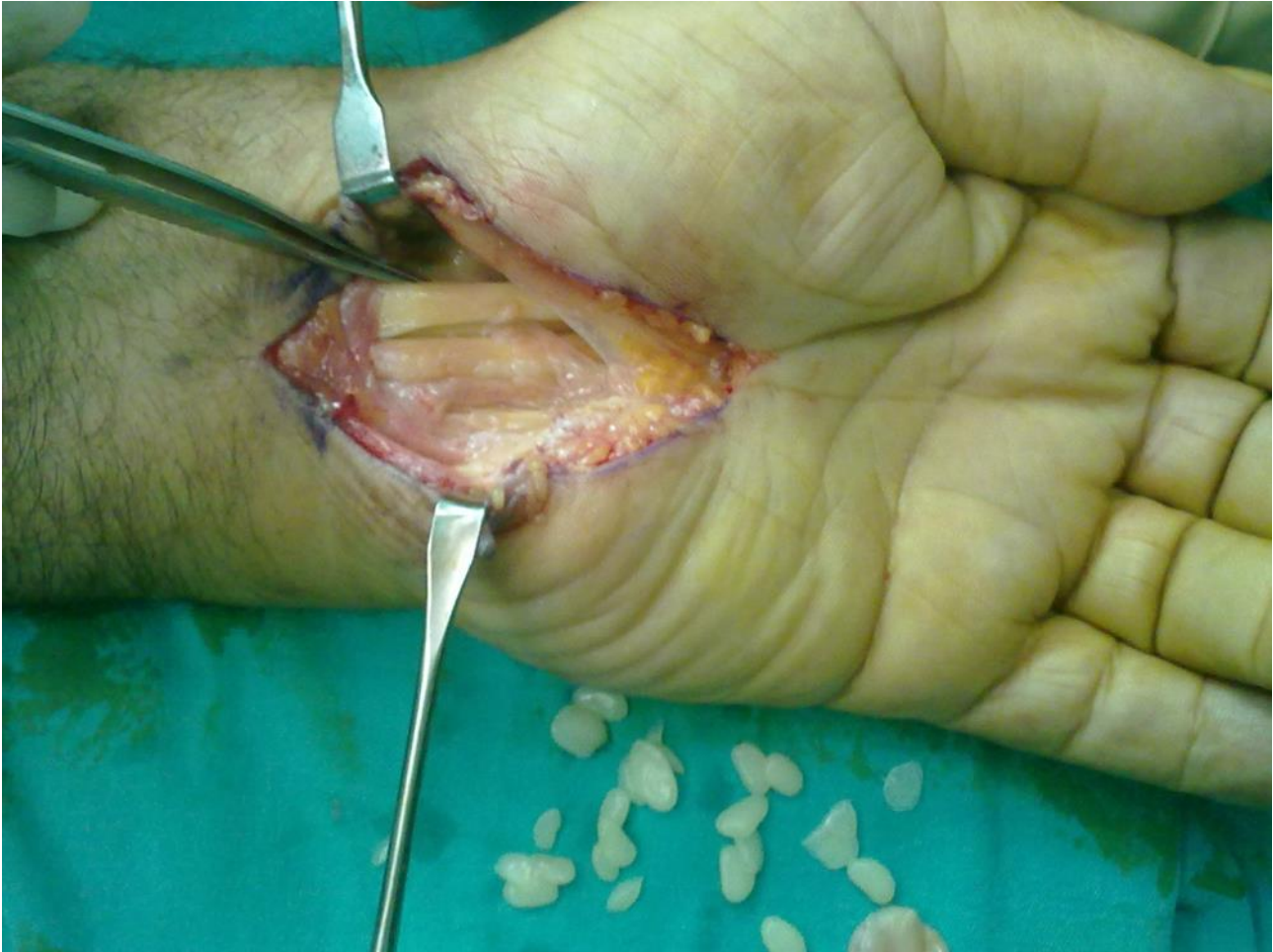

Figure 2: Peroperative appearance after debulking synovectomy and carpal tunnel release.

DISCUSSION

Musculoskeletal tuberculosis is a rare form of extrapulmonary tuberculosis. 1- 3% of patients with tuberculosis have musculoskeletal tuberculosis and of these, 2% involve wrist region. It typically results from direct invasion of adjacent bone or joint infection, or hematogenous spread from a primary focus. In these patients disease may involve tenosynovium, carpal synovium or bone (5,6).

Nonspecific symptoms and signs, nonspecific radiological findings, laboratory examinations depending on positive cultures for tuberculosis bacilli and rarity of the condition lead to misdiagnosis or delayed diagnosis similar to our patient (7).

Onset of the disease is insidious, with progressive swelling that is mistaken for simple ganglion, pain and restricted motion, sometimes, with development of carpal tunnel syndrome as in the presented case (4).

The disease has four stages (hygromatous, serofibrinous, fungoid and very late stage) as it progresses although they may coexist in the same patient (6,7).

While some authors recommend a combination therapy consisting of surgical synovectomy and chemotherapy, most recommend a tissue sample biopsy for diagnosis and chemotherapy without synovectomy for immunocompetent patients. The handicap of the latter approach is fibrosis necessitating synovectomy later. Aggressive synovectomy may reduce the mycobacterial load to chemotherapy in immunocompromised patients. Thorough synovectomy and chemotherapy is indicated regardless of immune status of the patients if the mycobacteria are partially or completely resistant to the drugs or the organism is pernicious (7,8).

Synovial specimens are usually sent for histopathological examination but, reflecting decreased

awareness of this uncommon condition, may not be sent for microbiological examinations as in our case due to unsuspected diagnosis of tuberculous tenosynovitis. The use of paraffin and formalin in excised synovial specimen was most likely cause of non-diagnostic PCR in our case.

Prompt diagnosis is important to prevent functional impairment. Thus, if the tenosynovitis is observed peroperatively, excised synovial specimens should be sent for histopathological examination and bacterial cultures, to ascertain or rule out the presence of tuberculosis (6,7).

Laboratory diagnosis of the disease should be essential in the absence of microbiological examinations. It is often possible with Ziehl Neelsen stained sputum smears, but it is difficult to obtain appropriate quality sputum samples in the cases of extrapulmonary tuberculosis. In these cases, immunodiagnostic tests such as IP-10 release assays are useful in the identification of *Mycobacterium tuberculosis* (9).

The differential diagnosis for tuberculous tenosynovitis includes atypical mycobacterial infections, pyogenic infections, fungal infections, brucellosis, rheumatoid arthritis, gouty arthritis, sarcoidosis, foreign body tenosynovitis, villonodular tenosynovitis and giant cell tumor of the tendon sheath (6,8).

Although, our patient had normal chest roentgenograms and chest CT, and negative PCR for mycobacteria, high prevalence of tuberculosis in our country and our patient's positive TST and IP-10 release assays led us to the diagnosis of extrapulmonary tuberculosis, and marked clinical improvement with the antituberculous agents strongly supported our diagnosis.

In conclusion, the diagnosis of tuberculous tenosynovitis remains a challenge for clinicians and requires a high index of suspicion. Consideration of the possibility and combined appropriate surgical treatment and antituberculous drugs resulted in a successful outcome.

REFERENCES

1. Cramer K, Seiler JG, Milek MA. Tuberculous tenosynovitis of the wrist: two case reports. *Clin Orthop Relat Res* 1991;262:137-140.
2. Jaovisidha S, Chen C, Ryu KN, Siriwongpairat P, Pekan P, Sartoris DJ, Resnick D. Tuberculous tenosynovitis and bursitis: imaging findings in 21 cases. *Radiology* 1996; 201:507-13.
3. Kotwal PP, Khan SA. Tuberculosis of the hand: clinical presentation and functional outcome in 32 patients. *J Bone Joint Surgery Br.* 2009; 91B, 1054-1057.
4. Patel MR, Malaviya GN, Sugar AM. Chronic infections. In: Greens operative hand surgery. Eds: Green DP, Hotchkiss RN, Pederson WC, Wolfe SW. 5th ed. Philadelphia: Elsevier-Churchill Livingstone 2005: 94-158.
5. Ruhwald M, Aabye MG, Ravn P: IP-10 release assays in the diagnosis of tuberculosis infection: current status and future directions. *Expert Rev Mol Diagn* 2012; 12:175-87.
6. Sanders CJ, Schucany WG. Tuberculous tenosynovitis. *Proc (Bayl Univ Med Cent)*. 2008; 21: 71-72.
7. Suso S, Peidro L, Ramon R. Tuberculous synovitis with "rice bodies" presenting as carpal tunnel syndrome. *J Hand Surg Am* 1988;13A:574-576.
8. Tappeiner G, Wolff K. Tuberculosis and other mycobacterial infections. In: *Dermatology in General Medicine*. Eds: Fitzpatrick TB, Freedberg IM, Eisen AZ, Wolff K. 4th ed. New York: McGraw-Hill Company, 1999: 2274-92.
9. Woon CY, Phoon ES, Lee JY, Puhaindran ME, Peng YP, Teoh LC. Rice bodies, millet seeds, and melon seeds in tuberculous tenosynovitis of the hand and wrist. *Ann Plast Surg.* 2011 Jun;66(6):610-7.